



# Evaluation of Testosterone, Blood Antioxidants, And Histopathological Changes Following Chemical Castration With Calcium Chloride in Rats

Mehdi Hami<sup>1</sup>, Abbas Veshkini<sup>1\*</sup>, Alireza Jahandideh<sup>1</sup>, Siamak Mashhadi Rafiee<sup>1</sup>, Pejman Mortazavi<sup>2</sup>

## Abstract

**Objectives:** Castration is one of the most common methods of contraception in animals. This method can prevent animals from contracting various diseases, such as testicular tumors, and prevent the overgrowth of animal populations.

**Materials and Methods:** In this experiment, 10 adult and clinically healthy male Wistar rats weighing approximately 250-200 g were divided into two equal groups of control and treatment (n=5 in each). In the control group, normal saline and in the treatment group, 20% calcium chloride was injected into the testicular tissue. Blood samples were taken at the beginning and end of the experiment (day 21) and the superoxide dismutase (SOD), glutathione peroxidase (GPx), and testosterone levels were measured. Then, the tissue samples of testis were evaluated on days 7, 14, and 21.

**Results:** On day 21, SOD and GPx enzymes significantly increased in the treatment group compared to day zero ( $P=0.01$ ). However, calcium chloride injection reduced the mean testosterone levels on day 21 compared to day zero ( $P=0.06$ ). Meanwhile, the mean number of sperms in the right testis of treated mice significantly decreased ( $P=0.03$ ). Seminiferous tubule necrosis significantly increased on day 7, neutrophil infiltration significantly increased on days 7 and 14, and calcification significantly increased on days 7 and 21 ( $P<0.01$ ).

**Conclusions:** Although chemical sterilization using 20% calcium chloride can lead to testicular degeneration, it is not a recommended method because it does not reduce testosterone and activates oxidative stress biomarkers. However, the negative effects might be eliminated in future studies using some substances such as tannic acid.

**Keywords:** Calcium chloride, Chemical castration, Antioxidant, Histopathology, Testosterone, Rat

## Introduction

Currently, most veterinarians perform surgery to castrate and sterilize male animals. However, surgical castration requires postoperative care to minimize the risk of bleeding and infection. Postoperative complications, along with cost and time spent on surgery are among the disadvantages of this method (1). In addition, surgery is not a suitable technique to be used on a large scale, such as population control of stray dogs (2). Therefore, researchers are trying to use sterilization methods to identify chemicals in male pets that might be a better alternative to castration surgery.

Chemical castration was done for the first time in the United States by Wang in 1987. Since then, numerous attempts have been made to sterilize males using chemical methods, and various pharmacological chemical compounds have been used. Several reports have evaluated the injection of different hormones into sterilizing male animals in many different species, but these treatments have failed to cause permanent sterilization (3,4). Results have shown that all ingredients that can inhibit spermatogenesis by inhibiting the secretion of gonadotropins, especially luteinizing hormone (LH), can be used for chemical

castration (5). Immunological techniques have also been used to induce antibodies against gonadotropins, with varying results (6,7). In addition, researchers have tested the effect of intra-testicular injections of various chemical agents such as cadmium chloride, iron chloride, iron sulfate, danazol, glycerol, and lactic acid for chemical castration in laboratory and domestic animals (4,8,9). There is pain, fever, and even severe inflammation (orchitis) after injecting these substances into the testicles. Some substances, such as cadmium chloride, glycerol, and lactic acid cause selective destruction of testicular tissue with reversible testicular tissue damage (8,10,11).

So far, no effective sterilizing chemical has been introduced to manage the side effects of the above chemicals. Recently, some studies attempted sterilization by injection of calcium chloride into testicular tissue in dog (12,13), cat (1,14), cattle (15,16), goat (17), donkey (18,19), pig (20), and rat (8). The mechanism of action of this chemical is still under investigation. Calcium chloride is a chemical compound with the formula  $\text{CaCl}_2$ , which is often associated with two molecules of water. One of its main properties is to participate in alternative reactions. It is easily substituted for another cation and, when



## Key Messages

- ▶ Calcium chloride is an important chemical for inducing the production of free radicals in tissues
- ▶ Calcium chloride increases the biomarkers of oxidative stress and decreases testosterone.

dissolved in water, releases heat due to its high enthalpy of dissolution (21). One of the things that is always important in chemical sterilization is its effect on oxidative stress. Calcium chloride is an important chemical for inducing the production of free radicals in tissues, because it can destruct all cellular structures and lipids by lipid peroxidation (1). Free radicals inhibit spermatogenesis, and antioxidant enzymes are important inhibitors against free radicals in the male gonads (2,22,23).

Accordingly, this study aimed to evaluate the effect of injecting 20% calcium chloride solution into the testis of rats on testosterone levels, histopathological changes of testis tissue, sperms count, as well as some antioxidant enzymes.

### Materials and Methods

This study was performed in Vanak Veterinary Clinic in Tehran, Iran from September to December 2020. To this end, ten 6-month-old male Albino Wistar rats weighing 200-250 g were selected and kept in standard cages under 12 hours light and dark conditions at room temperature ( $22 \pm 2^\circ\text{C}$ ). The animals had free access to sufficient water and pelleted food during the experiment. All the mice were clinically examined at the beginning and end of the study (day 21), which included testicular examination, pain in the testis area, appetite, and stool.

The mice were randomly divided into two equal groups ( $n = 5$  in each) of control and treatment. In the treatment group, on day zero, 20% calcium chloride was dissolved in 0.3 ml of normal saline and injected into the tissue of both testes. In the control group, normal saline was injected. For this purpose, the hair of the scrotum was first shaved with a hair straightener. Then, following local anesthesia, calcium chloride solution (Inoxia, UK) was injected into the testes of mice under ultrasonography. The injection was performed using a sterile syringe and needle No. 27 from the abdominal surface of the testis, away from the epididymis and towards the anterior part of the testis.

In both groups, the right testicle was removed at the end of the experiment (day 21). Immediately after testicular resection, semen was taken from the epididymis of all mice and then buffered with formalin saline, diluted 1 to 10, and the number of sperms in the semen transferred on a hemocytometer was counted with a light microscope. At the same time, on days 0 and 21, the mice were sampled in two tubes containing both anticoagulants and no anticoagulants. After serum preparation, testosterone levels were measured by the enzyme-linked immunosorbent assay (ELISA) method using a human

kit (ZellBio, Germany). In blood samples, the activity of superoxide dismutase (SOD) and glutathione peroxidase (GPx) enzymes was measured with a commercial kit (Randox, UK) (24).

### Histopathology

The left testicles were fixed in 10% buffered formalin on days 7, 14, and 21 and transferred to the pathology department of Islamic Azad University of Tehran. The formalin was also replaced 24 hours later and remained in place until studies were completed. To prepare tissue slides, the tissue samples were placed in paraffin blocks, then examined microscopically by hematoxylin and eosin (H&E) staining. Next, we evaluated intravascular thrombosis, seminiferous tubule necrosis, hemorrhage, neutrophil infiltration, and calcification in the samples. The observed damage was measured according to the following quantitative indicators: lack of damage, the least damage, average damage, a large amount of damage, and huge damage (16).

The obtained data was analyzed using the Statistical Package for the Social Sciences (SPSS) software version 21 and *t* test at the probability level of  $P < 0.05$ . The results of histopathology were analyzed by chi-square test.

### Results

All mice tolerated injection of calcium chloride into the testis. None of the mice showed any signs of discomfort from the injection. There were no significant changes in food and water intake in any of the mice during the experiment. Measurement of left and right testes showed a significant reduction in the length and width of both testicles in the treatment group, but there was no significant change in testicular size in the control group (Table 1). Comparison of changes in SOD and GPx enzymes in the treatment group showed a significant increase in both enzymes on day 21 compared to day zero. There were no significant changes in the control group (Table 2).

Although calcium chloride injection reduced the mean testosterone levels on day 21 compared to day zero, this difference was not statistically significant. At the same time, the mean number of sperms in the right testis of treated mice significantly decreased ( $P = 0.019$ , Table 3).

Intravascular thrombosis and hemorrhage increased in the treatment group, but there was no significant difference in different days of the study ( $P=0.081$ ). Also, seminiferous tubule necrosis significantly increased on day 7 and then decreased at the end of the study (day 21) ( $P=0.019$ ) (Figure 1). Neutrophil infiltration increased on days 7 and 14, and it was at the lowest level at the end of study (day 21) ( $P=0.001$ ) (Figure 1). In addition, calcification significantly increased on days 7 and 21 ( $P=0.005$ ).

### Discussion

In this study, we observed no significant changes in animals' behavior and there were no symptoms of discomfort,

**Table 1.** Mean Testicular Length and Width of Rats Before and After Calcium Chloride Injection ( $\pm$ Standard Deviation)

Group		Length (mm)			Width (mm)		
		Day 0	Day 21	P Value	Day 0	Day 21	P Value
Control	Left	11.43 $\pm$ 0.6	11.43 $\pm$ 0.6	0.099	9.40 $\pm$ 1.1	9.40 $\pm$ 1.1	0.99
	Right	10.38 $\pm$ 1.0	10.38 $\pm$ 1.0	0.99	10.09 $\pm$ 1.3	10.9 $\pm$ 1.3	0.99
Treatment	Left	10.68 $\pm$ 0.7	3.42 $\pm$ 0.8*	0.015	9.42 $\pm$ 0.7	3.22 $\pm$ 0.4*	0.011
	Right	10.43 $\pm$ 0.3	3.23 $\pm$ 0.3*	0.012	9.83 $\pm$ 0.4	3.31 $\pm$ 0.4*	0.009

\*Indicates a statistically significant difference in each row ( $P < 0.05$ ).

**Table 2.** SOD and GPx Activity in the Study Groups ( $\pm$ Standard Deviation)

Group	SOD (Units/g of hemoglobin)			GPx (Units/g of hemoglobin)		
	Day 0	Day 21	P Value	Day 0	Day 21	P Value
Control	44.93 $\pm$ 1.23	45.06 $\pm$ 1.33	0.073	238.11 $\pm$ 10.17	238.38 $\pm$ 12.21	0.81
Treatment	44.30 $\pm$ 0.79	56.19 $\pm$ 0.078*	0.026	236.28 $\pm$ 11.17	430.00 $\pm$ 18.94*	0.017

\*Indicates a statistically significant difference in each row ( $P < 0.05$ ).

**Table 3.** A Comparative Study of Serum Testosterone Levels and Sperm Counts on Days 0 and 21 in the Studied Groups ( $\pm$ Standard Deviation)

Group	Testosterone (ng/mL)			Sperms count (million/mm <sup>3</sup> )		
	Day 0	Day 21	P Value	Day 0	Day 21	P Value
Control	16.30 $\pm$ 0.82	16.19 $\pm$ 0.73	0.851	39.45 $\pm$ 5.2	38.12 $\pm$ 5.7	0.659
Treatment	16.44 $\pm$ 0.64	10.58 $\pm$ 1.24	0.026	39.12 $\pm$ 4.1	20.14 $\pm$ 2.0*	0.019

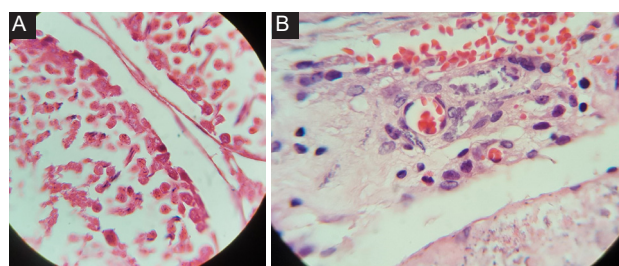
\*Indicates a statistically significant difference in each row ( $P < 0.05$ ).

which is consistent with some previous reports (8,24). However, in another study, dogs treated with calcium chloride showed temporary and mild discomfort after injection due to excessive fluid pressure (12).

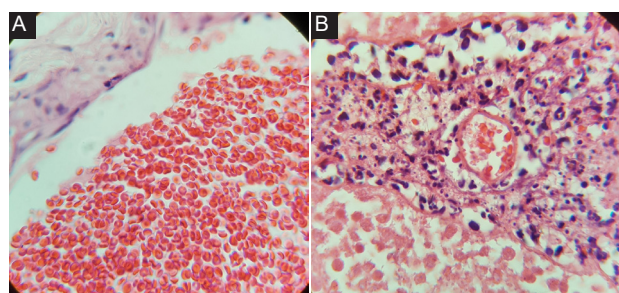
Oxidative stress is caused by the excessive formation of free radicals due to the further reduction of antioxidants in the target cells and tissues. The body reduces and

controls the amount of free radical molecules by various cellular defense mechanisms consisting of enzymes (2). The results of our study indicated that the oxidative stress indices, including SOD and GPx significantly increased after the injection of 20% calcium chloride. This finding was in line with the study by Abou-Khalil et al, in which the authors compared changes in oxidative and antioxidant parameters and oxidative stress index following chemical castration after the injection of 20% calcium chloride solution in ethanol and surgical castration in the ass. According to their results, although total antioxidant capacity and total peroxide in both groups were associated with time-dependent changes, the oxidative stress index in the surgical castration group was high compared to the chemical castration group. They also compared serum cortisol as an indicator of stress in the ass. Their findings showed that cortisol was significantly higher in the castrated group with calcium chloride solution compared to the surgical method (19).

In a study of castrated dogs with surgery, the total antioxidant capacity on day 14 after castration was lower (2), which is contradictory to our results. However, in the study, plasma malondialdehyde (MDA) and catalase levels were not different in male dogs before and after castration, which indicates no oxidative stress in dogs after castration. In another similar study in dogs, a dose-dependent decrease in GPx and SOD activity in testicular tissue was recorded (12). In 2002, Jana et al showed that injection of 2.5 mg of calcium chloride into rat testicular tissue did not significantly alter SOD activity and MDA in testicular tissue, but significantly decreased SOD and significantly



**Figure 1.** Histopathological Changes in Testis (H&E), A: Necrosis, B: Hemorrhage.



**Figure 2.** Histopathological changes in testis (H&E), A: hemorrhage, B: Neutrophil infiltration (X100 magnification).

increased MDA in testicular tissue after injection of calcium chloride 5, 10, and 20 mg (24). However, it should be noted that these studies focused on the oxidant-antioxidant balance in testicular tissue, whereas our study focused on the whole body and plasma. It has also been shown that chemical castration using 20% sodium chloride in calves led to mild stress and inflammatory responses compared to surgical castration (25). However, injection of calcium chloride into the testes of rats did not significantly alter plasma corticosterone levels (24).

In the present study, studying the testosterone levels in mice before and after intra-testicular injection of calcium chloride showed that testosterone levels were insignificantly lower on day 21 in the treatment group than before the injection. In a similar study by Ibrahim et al, chemical castration with calcium chloride in donkeys did not reduce serum testosterone levels (18). Different doses of calcium chloride in rats significantly decreased plasma testosterone levels after injection of calcium chloride 5, 10, and 20 mg, but the injection of 2.5 mg had no effect (24). Also, injection of 20% sodium chloride in calves less than 20 days old significantly reduced testosterone secretion (26), which contradicts the findings of this study. This difference can be attributed to higher testosterone levels in calves than in mice. Emir et al injected hypertonic saline solution into 40 rats and reported significantly reduced total blood testosterone levels on day 30 compared to the day before the intervention (27). Similarly, a significant decrease in plasma testosterone in dogs on day 45 after a single dose of calcium chloride injection was shown to be the greatest decrease at doses of 15 and 20 mg (12). The discrepancy in the latter two cases with the present study may be related to the difference in study time. The occurrence of degeneration in Leydig interstitial cells induced by calcium chloride may lead to a decrease in plasma testosterone concentration (28).

The results of this study showed that the number of sperms in the mice receiving 20% calcium chloride was significantly lower than the control group. In a similar study, injection of 2.5 mg of calcium chloride did not cause a significant change in sperms count in the testicular epididymis, but a significant decrease in sperms count occurred after injection of 5, 10, and 20 mg of calcium chloride. Thus, the minimum effective dose for chemical castration in rats is estimated to be 5 mg (24). Injection of different doses of calcium chloride into the testis has significantly reduced the number of sperms in dogs (12). A significant decrease in sperms count in the epididymis reflects low plasma testosterone levels, because sperm production in the testicle and its development in the epididymis is controlled by testosterone. Leydig interstitial cell degeneration due to calcium chloride injection reduces plasma testosterone (28). The ability of calcium chloride in the chemical castration of rats has been associated with necrosis of the seminiferous tubules and Leydig interstitial cells and apparent interstitial fibrosis (24).

In addition, low plasma testosterone concentrations have been shown in mice treated with calcium chloride with a significant reduction in epididymis sperm count, because sperm maturation in the epididymis is controlled by testosterone (12). The effect of calcium chloride on chemical induction of sterilization due to necrosis of seminiferous tubules and interstitial cells is accompanied by significant fibrosis and hyaline. The infiltration of leukocytes into the seminiferous tubules and interstitial spaces after calcium chloride treatment may be due to testicular tissue damage or degeneration that releases large amounts of chemotactic factors to invoke leukocytes (12). Another explanation for the mechanism of chemical sterilization with calcium chloride could be through the production of large amounts of free radicals or their products in testicular tissue. The production of free radicals in the testicles leads to low testosterone levels (29). Clinical evaluations indicated no changes related to vital parameters and no adverse reactions to the sterilizing agent, which is similar to previous reports (16). One study reported chemical castration had no detectable changes in the general health of the animals and there was only swelling in external genitalia (18).

Histopathology results indicated that 20% calcium chloride injection caused changes in the testis tissue. The most significant changes included intravascular thrombosis, seminiferous tubule necrosis, hemorrhage, neutrophil infiltration, and calcification. The results of studies on uses of 10% and 20% calcium chloride in cats demonstrated that the testis tissue was completely necrotic and had fibrosis 60 days after injection (1). Other researchers evaluated the calcium chloride effects in bull testis. The coagulative necrosis of seminiferous tubules and interstitial cells, infiltration of inflammatory cells, and fibroplasia were widely observed in the tissues (16). The administration of 30% calcium chloride to male buffalo causes complete testicular fibrosis (30). In another research, the effects of 20% calcium chloride on mature and immature dogs was evaluated. There was focal necrosis, as well as severe and extensive degenerative changes with the presence of Leydig cells in the lumen (31). The administration of 30% calcium chloride in 5-month-old cattle caused coagulation necrosis, infiltration of inflammatory cells, and calcification. So, chemical castration caused light stress and inflammatory response compared to surgical method (25).

## Conclusions

In summary, based on the results of this study, chemical sterilization with 20% calcium chloride can lead to testicular tissue degradation. However, since it increases the biomarkers of oxidative stress and decreases testosterone, its use alone is not recommended. We may eliminate this shortcoming by using antioxidant drugs at the same time.

### Authors' Contribution

MH: data collection, drafting the manuscript and supervised the study process; AV: study design and conducting the study; AJ: supervised the pathology slides, SMR: supervised the castration process; PM: review of the manuscript and consulting on biochemical analysis.

### Conflict of Interests

None.

### Ethical Issues

The research project was approved by the Ethics Committee of Science and Research Branch Islamic Azad University (code: IR.IAU.SRB.REC.1397.209).

### Financial Support

This study has been financed by Science and Research Branch, Islamic Azad University, Tehran, Iran.

### Acknowledgments

The authors wish to thank the Radiology and Diagnostic Imaging Department of Vanak Veterinary Clinic in Tehran, Iran. We also thank Dr. Zakeri and Dr. Eliassy for sincere help.

### References

- Jana K, Samanta PK. Clinical evaluation of non-surgical sterilization of male cats with single intra-testicular injection of calcium chloride. *BMC Vet Res.* 2011;7:39. doi:10.1186/1746-6148-7-39
- Aengwanich W, Sakundech K, Chompoosan C, Tuchpramuk P, Boonsorn T. Physiological changes, pain stress, oxidative stress, and total antioxidant capacity before, during, and after castration in male dogs. *J Vet Behav.* 2019;32:76-79. doi:10.1016/j.jveb.2019.04.004
- Dhar JD, Setty BS. Effect of a nonsteroidal antiandrogen, anandron, on the reproductive system and fertility in male rats. *Contraception.* 1990;42(1):121-138. doi:10.1016/0010-7824(90)90096-e
- Singh G, Kumar A, Dutt R, Arjun V, Jain VK. Chemical castration in animals: an update. *Int J Curr Microbiol Appl Sci.* 2020;9(4):2787-2807.
- Shim M, Bang WJ, Oh CY, Lee YS, Cho JS. Effectiveness of three different luteinizing hormone-releasing hormone agonists in the chemical castration of patients with prostate cancer: goserelin versus triptorelin versus leuprolide. *Investig Clin Urol.* 2019;60(4):244-250. doi:10.4111/icu.2019.60.4.244
- Gonzalez A, Allen AF, Post K, Mapletoft RJ, Murphy BD. Immunological approaches to contraception in dogs. *J Reprod Fertil Suppl.* 1989;39:189-198.
- Inaba T, Umehara T, Mori J, Torii R, Tamada H, Sawada T. Reversible suppression of pituitary-testicular function by a sustained-release formulation of a GnRH agonist (leuprolide acetate) in dogs. *Theriogenology.* 1996;46(4):671-677. doi:10.1016/0093-691x(96)00218-x
- Jana K, Samanta PK. Evaluation of single intratesticular injection of calcium chloride for nonsurgical sterilization in adult albino rats. *Contraception.* 2006;73(3):289-300. doi:10.1016/j.contraception.2005.07.011
- Nishimura N, Kawate N, Sawada T, Mori J. Chemical castration by a single intratesticular injection of lactic acid in rats and dogs. *J Reprod Dev.* 1992;38(4):263-266. doi:10.1262/jrd.38.263
- Immegart HM, Threlfall WR. Evaluation of intratesticular injection of glycerol for nonsurgical sterilization of dogs. *Am J Vet Res.* 2000;61(5):544-549. doi:10.2460/ajvr.2000.61.544
- Mohamadpour M, Mollajani R, Sarabandi F, Hosseini F, Mohsenkia M, Erfanizadeh M, et al. Protective effect of grape seed extract on dexamethasone-induced testicular toxicity in mice. *Crescent J Med Biol Sci.* 2020;7(1):59-65.
- Jana K, Samanta PK. Sterilization of male stray dogs with a single intratesticular injection of calcium chloride: a dose-dependent study. *Contraception.* 2007;75(5):390-400. doi:10.1016/j.contraception.2007.01.022
- Leoci R, Aiudi G, Silvestre F, Lissner EA, Marino F, Lacalandra GM. A dose-finding, long-term study on the use of calcium chloride in saline solution as a method of nonsurgical sterilization in dogs: evaluation of the most effective concentration with the lowest risk. *Acta Vet Scand.* 2014;56(1):63. doi:10.1186/s13028-014-0063-1
- Paranzini CS, Sousa AK, Cardoso GS, et al. Effects of chemical castration using 20% CaCl<sub>2</sub> with 0.5% DMSO in tomcats: evaluation of inflammatory reaction by infrared thermography and effectiveness of treatment. *Theriogenology.* 2018;106:253-258. doi:10.1016/j.theriogenology.2017.10.013
- Mitra B, Samanta PK. Testicular degeneration of scrub bulls by calcium chloride. *Indian J Vet Surg.* 2000;21(1):37-38.
- Pereira LF, Dias FG, Miguel MP, Honsho CS, Tavares DC, Hellú JA, et al. Testicular histological evaluation and serum testosterone concentrations of bulls after chemical castration with calcium chloride. *Pesqui Vet Bras.* 2018;38(8):1554-1563. doi:10.1590/1678-5150-pvb-4945
- Jana K, Samanta PK, Ghosh D. Evaluation of single intratesticular injection of calcium chloride for nonsurgical sterilization of male Black Bengal goats (*Capra hircus*): a dose-dependent study. *Anim Reprod Sci.* 2005;86(1-2):89-108. doi:10.1016/j.anireprosci.2004.05.021
- Ibrahim A, Ali MM, Abou-Khalil NS, Ali MF. Evaluation of chemical castration with calcium chloride versus surgical castration in donkeys: testosterone as an endpoint marker. *BMC Vet Res.* 2016;12:46. doi:10.1186/s12917-016-0670-3
- Abou-Khalil NS, Ali MF, Ali MM, Ibrahim A. Surgical castration versus chemical castration in donkeys: response of stress, lipid profile and redox potential biomarkers. *BMC Vet Res.* 2020;16(1):310. doi:10.1186/s12917-020-02530-0
- Sen CC, Yumusak N, Faundez R, Temamogullari F, Taskin A. Evaluation of intra-testicular injections of calcium chloride and 4-vinylcyclohexene 1,2 monoepoxide for chemical sterilization in guinea pigs. *Pol J Vet Sci.* 2017;20(2):251-260. doi:10.1515/pjvs-2017-0030
- Rumble JR. *CRC Handbook of Chemistry and Physics.* 101st ed. Abingdon: CRC Press; 2020.
- Moshkelani S, Asghari A, Abedi G, Jahandideh A, Mortazavi P. The effect of magnesium sulfate on sperm characteristics and blood hematology after testicular ischemia-reperfusion injury in rats. *Crescent J Med Biol Sci.* 2020;7(1):91-95.
- Alipour F, Jalali M, Nikravesh MR, Fazel A, Sankian M, Khordad E. The relationship between extracellular matrix proteins and germ cells apoptosis in BALB/c mouse testis following experimental hypothyroidism. *Crescent J Med Biol Sci.* 2022;9(1):9-18. doi:10.34172/cjmb.2022.03
- Jana K, Samanta PK, Ghosh D. Dose-dependent response to an intratesticular injection of calcium chloride for induction of chemosterilization in adult albino rats. *Vet Res Commun.* 2002;26(8):651-673. doi:10.1023/a:1020976905746
- Oliveira FC, Ferreira CER, Haas CS, et al. Chemical castration in cattle with intratesticular injection of sodium chloride: effects on stress and inflammatory markers. *Theriogenology.* 2017;90:114-119. doi:10.1016/j.theriogenology.2016.12.001
- Neto OA, Gasperin BG, Rovani MT, et al. Intratesticular hypertonic sodium chloride solution treatment as a method of chemical castration in cattle. *Theriogenology.* 2014;82(7):1007-1011.e1. doi:10.1016/j.theriogenology.2014.07.020

27. Emir L, Dadali M, Sunay M, Erol D, Caydere M, Ustün H. Chemical castration with intratesticular injection of 20% hypertonic saline: a minimally invasive method. *Urol Oncol*. 2008;26(4):392-396. doi:10.1016/j.urolonc.2007.05.013
28. Kataoka T, Hotta Y, Maeda Y, Kimura K. Testosterone deficiency causes endothelial dysfunction via elevation of asymmetric dimethylarginine and oxidative stress in castrated rats. *J Sex Med*. 2017;14(12):1540-1548. doi:10.1016/j.jsxm.2017.11.001
29. Chainy GB, Samantaray S, Samanta L. Testosterone-induced changes in testicular antioxidant system. *Andrologia*. 1997;29(6):343-349. doi:10.1111/j.1439-0272.1997.tb00328.x
30. Martins LT, Gonçalves MC, Tavares KCS, et al. Castration methods do not affect weight gain and have diverse impacts on the welfare of water buffalo males. *Livest Sci*. 2011;140(1-3):171-176. doi:10.1016/j.livsci.2011.03.026
31. Canpolat I, Karabulut E, Eroksuz Y. Chemical castration of adult and non-adult male dogs with sodium chloride solution. *IOSR J Agric Vet Sci*. 2016;9(12)

**Copyright** © 2022 The Author(s); This is an open-access article distributed under the terms of the Creative Commons Attribution License (<http://creativecommons.org/licenses/by/4.0>), which permits unrestricted use, distribution, and reproduction in any medium, provided the original work is properly cited.