



# Effects of Tramadol Administration on Sperm Characteristics on Testicular Ischemia-Reperfusion Injury in Rat

Ahmad Asghari<sup>1\*</sup>, Ghasem Akbari<sup>2</sup>, Abbas Mohammad Beigi<sup>3</sup>, Pejman Mortazavi<sup>4</sup>

## Abstract

**Objective:** The main purpose of this study was to instigate effect of tramadol administration on sperm characteristics on testicular ischemia-reperfusion (IR) injury in male Wistar rats.

**Materials and Methods:** Eighteen Wistar rats were randomly allocated into 3 experimental groups. (A) The control group had no received any medications, abdominal cavity was opened but no IR-induced. The IR group (B): abdominal cavity was opened, IR-induced without pre-medication. (C) Animal orally administrated with tramadol (40 mg/kg) for 1 week followed by testicular IR-induced. The time duration of IR was 60 minutes in all experimental groups. Then after 24 hours, the abdomen was opened, semen samples were collected from the caudal epididymis to determine epididymis weight, sperm mortality, mobility and sperm count.

**Results:** According to the results, sperm mortality, mobility and sperm count significantly diminished in control group rats (group B) ( $P < 0.05$ ). Pre-treatment with 40 mg/kg of tramadol for 1 week before the IR was able to diminish effect of ischemia on sperm mortality, mobility and sperm count in rat ( $P < 0.05$ ).

**Conclusion:** Perhaps tramadol has curative effect against testicular IR.

**Keywords:** Tramadol, Sperm characteristic, Ischemia-reperfusion, Testicular, Rats

## Introduction

Infertility is the chief problems in couples in the world-wide which one third of the problems related to the males (1-3). Infertility is known as multi-parametric disorder and influence spermatogenesis and sperm quality (4). Testicular torsion terminates to tissue degeneration and for reperfusion of the affected testis needs emergency surgical intervention. Ischemia of the testis followed by reperfusion is the main pathophysiological event in testicular. Ischemic damage destroys the blood-testis barrier which leads to immunological invention and damage (5). Following unilateral torsion, blood flows in both the ipsilateral and the contralateral internal spermatic arteries are diminished. Also, long-term consequences lead to damage testicular function and fertility (6).

Reports indicated tissue injury in several organs happens not only during the ischemia but also in the reperfusion stage (7). Tramadol hydrochloride is narcotic-like pain reliever drug centrally effective analgesic used for acute pain conditions include neuropathic, cancer and postoperative surgical pain (8). Recent reports imply that tramadol diminishes lipid peroxidation and regulates noradrenalin uptake and can be used for the management of ischemia (9). The role of the tramadol on remote testicular injury caused by skeletal muscle ischemia/reperfusion is not determined. Tramadol provides a cardio-protective effect

against myocardial ischemia-reperfusion (IR) in rat (10). Because IR injury is categorized by an increase in reactive oxygen species (ROS) and on the other side antioxidant activity of tramadol against oxidative stress, the hypothesis of this paper was to investigate possible effects of tramadol on sperm characteristics in testicular IR in rat.

To best of our knowledge, scarce no report exists on role of tramadol on experimental testicular IR in rat. The results of our investigation would help to clarify the potential importance of the use of tramadol in situations of oxidative damage. In this regard, based on literature review, our hypothesis was that maybe tramadol might has effect (8) on fertility testicular IR in rat. So, aim of the current study was to determine role of dietary tramadol on sperm mortality, mobility and sperm count on experimental testicular IR in rat.

## Materials and Methods

### Study Animals

In this study, 18 male Wistar rats (230-250 g) were allocated into 3 treatment groups. The rats were housed individually under standard laboratory conditions according to European community suggestions for laboratory animals at a temperature of 21°C, relative humidity of 55%-60% and a 12-hour light period. All animals had free access to chow pellets and fresh water. All experimental proce-

Received 18 October 2015, Accepted 25 August 2016, Available online 16 September 2016

<sup>1</sup>Department of Veterinary Surgery, Science and Research Branch, Islamic Azad University, Tehran, Iran. <sup>2</sup>Department of Theriogenology, Science and Research Branch, Islamic Azad University, Tehran, Iran. <sup>3</sup>Graduate Student, Science and Research Branch, Islamic Azad University, Tehran, Iran.

<sup>4</sup>Department of Pathology, Science and Research Branch, Islamic Azad University, Tehran, Iran.

\*Corresponding author: Ahmad Asghari, Email: dr.ahmad.asghari@gmail.com

dures were carried in accordance with the Guide for the Care and Use of Laboratory Animals to Investigate Experimental Pain in Animals (11). Animal handling and experimental procedures were performed according to the Guide for the Care and Use of Laboratory Animals by the US National Institutes of Health (NIH Publication No. 85-23, revised 1996) and the current laws of the Iranian government. Also, all protocol of the study proved by ethic committee of Islamic Azad University, Science and Research Branch, Tehran, Iran.

#### Experimental Testicular Ischemia-Reperfusion Injury

Surgical procedures were done beneath anesthesia by intraperitoneal (i.p.) injection of 60 mg/kg ketamine hydrochloride 10% and 10 mg/kg xylazine hydrochloride 2%, then experimental varicocele was created (12,13). The upper left abdominal quadrant was approached through a midline laparotomy incision. The temperature of the animals was maintained at approximately 37°C by an overhead lamp during the surgery. The testicular IR injury was induced by torsion of the left testis, with a 720° twisting of the spermatic cord to produce total occlusion of the testis for 1 hour. In all experimental groups rats were subjected to 1 hour of testicular ischemia followed by 24 hours of reperfusion. Control-operated rats were subjected to the same surgical procedures as testicular IR injury rats except for the testicular torsion. An overdose injection of pentobarbital (300 mg/kg, i.p.) used for euthanize of the rats. Peritoneum on the animal opened and left testis was taken out for further investigations (6).

#### Study Design

Eighteen male Wistar rats were randomly divided into 3 experimental groups (A, B and C) (n=6). The control group (A) had no received any medication, abdominal cavity was opened without testicular IR. The testicular IR group (B): abdominal cavity was opened, testicular IR without previous treatment with medication. In group (C) animal orally administrated with Tramadol (40 mg/kg) for 1 week followed by testicular IR-induced. In all experimental groups rats were subjected to 1 hour of testicular ischemia followed by 24 hours of reperfusion in the left testis. After 24 hours, rats were euthanized, peritoneum opened and testes were taken out for investigate sperm characteristics.

#### Sperm Characteristics

At the end of the experiment, semen samples were collected from the caudal epididymis carefully separated from the testis and placed in a Petri dish containing Ham's F10. Epididymal caudal was minced with scissors to release sperm and then was placed in the incubator for 15 minutes. Approximately, 10 µL of the diluted sperm suspension was transferred to each counting chamber of the hemocytometer, then permitted to stand for 5 minutes. The cells which settled during this time were counted using a light microscope at 200X magnification. The sperm were counted and presented as million/ml of suspension (14).

#### Statistical Analysis

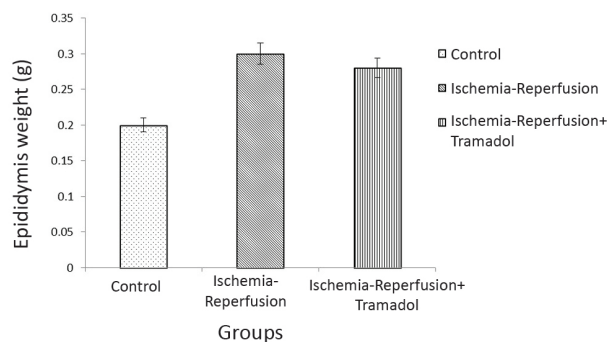
Data were prepared in Excel, the parametric data analyzed with one-way analysis of variance (ANOVA) using SPSS 16.0 for Windows (SPSS, Inc., Chicago, IL, USA). Data were expressed as mean values ± standard error of mean (SEM). *P* values of <0.05 were considered to denote significant differences between groups.

#### Results

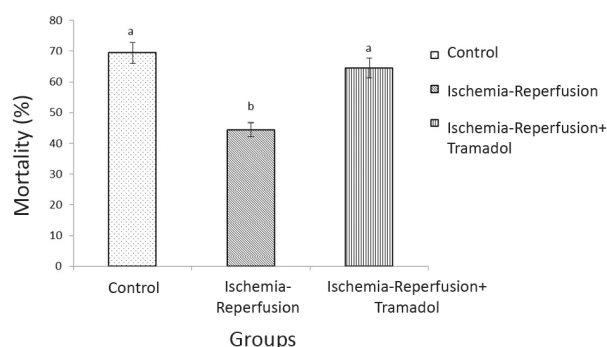
Effects of tramadol treatment followed by testicular IR on epididymis weight, sperm mortality, mobility and sperm count in rat is presented in Figures 1-4. According to the results, experimental testicular IR significantly diminished and tramadol treatment (40 mg/kg, for 1 week) had no significant effect on epididymis weight in comparison to control group (without testicular IR) ( $P=0.710$ ; Figure 1).

As seen in the Figure 2, testicular IR significantly diminished sperm mortality rate compared to control group ( $P=0.04$ ). Also, pre-treatment with tramadol (40 mg/kg, for 1 week) significantly attenuated the adverse the effect of testicular IR on sperm mortality compared to the rat without treatment (group B) ( $P=0.01$ ). There was no significant difference on sperm mortality among pre-treated tramadol group followed with testicular IR in comparison to control group ( $P>0.05$ ).

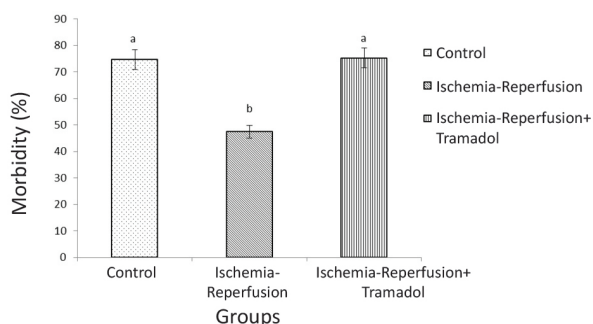
In this study, sperm mobility significantly decreased in



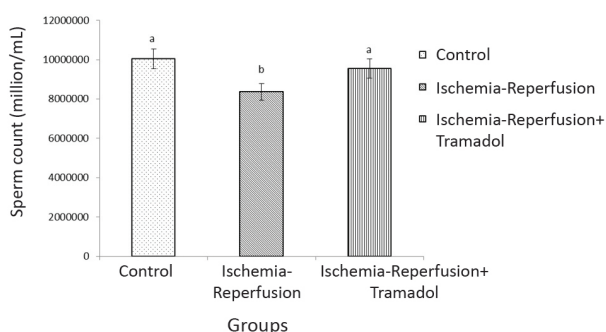
**Figure 1.** Effect of dietary tramadol supplement (40 mg/kg) for 1 week on epididymis weight in testicular ischemia-reperfusion rat. There are significant differences between groups with different superscripts in a column (a and b;  $P<0.05$ ).



**Figure 2.** Effect of dietary tramadol supplement (40 mg/kg) for 1 week on sperm mortality in testicular ischemia-reperfusion rat. There are significant differences between groups with different superscripts in a column (a and b;  $P<0.05$ ).



**Figure 3.** Effect of dietary tramadol supplement (40 mg/kg) for 1 week on sperm mobility in testicular ischemia-reperfusion rat. There are significant differences between groups with different superscripts in a column (a and b;  $P < 0.05$ ).



**Figure 4.** Effect of dietary tramadol supplement (40 mg/kg) for 1 week on sperm count in testicular ischemia-reperfusion rat. There are significant differences between groups with different superscripts in a column (a and b;  $P < 0.05$ ).

testicular IR rat (group B) compared to the control group ( $P = 0.02$ ). The pre-treatment with 40 mg/kg of tramadol for 1 week, significantly decreased the adverse effect of testicular IR on sperm mobility compared to the sole testicular IR group ( $P < 0.021$ ). Furthermore, no significant difference detected for sperm mobility among IR group than tramadol pre-treatment followed with IR ( $P = 0.07$ ; Figure 3).

As observed in Figure 4, experimental testicular IR significantly decreased sperm count comparison to the normal rat (control group) ( $P < 0.001$ ). Also, administration of dietary tramadol supplement (40 mg/kg) for 1 week was able to minimize suppressive effect of experimental testicular IR on sperm count ( $P = 0.032$ ). In this study, no significant detected on sperm count in testicular IR and tramadol treated groups (A and C) ( $P = 0.08$ ).

## Discussion

To our knowledge, there are limit studies describing the role of dietary tramadol supplement on sperm characteristics in experimental testicular IR in rat. As observed, sperm mortality, mobility and sperm count significantly diminished in testicular IR in rat. Administration of tramadol (40 mg/kg) improved sperm mortality, mobility and sperm count after in testicular IR rat. There are only a scarce reports demonstrating remote myocardial injury following skeletal muscle IR injury (9).

Previous studies done the use of tramadol after IR in an-

imals attenuated the oxidative injuries. Nagakannan et al (8) studied the neuro-protective effect of tramadol against transient forebrain ischemia in rats. Tramadol provides a cardio-protective effect against myocardial IR in isolated rat hearts (10). The main pathophysiology of testicular torsion-detorsion is IR injury of the testis. During IR injury, the ROS generation increases and leads to loss of ipsilateral testicular spermatogenesis. The ROS cause tissue damage via cell membrane lipid peroxidation, protein and DNA denaturation. The neutrophil is one of important sources of ROS generation (15). Because of limitation this study, we were not able to determine levels of antioxidant enzymes after tramadol therapy in testicular IR rats. We think observed effects of tramadol might increase the antioxidant effect of tramadol against generation of ROS and terminated sperm characteristics in testicular IR injury in rat.

The diagnosis of male infertility routinely initiates with a basic semen analysis viscosity, sperm count and motility, sperm morphology and sperm viability (16). A connection described among testicular IR and semen parameters where administration of tramadol (40 mg/kg) improved sperm mortality, mobility and sperm count after in testicular IR rat. Opioids are among the most useful and promising substances for pharmacological pain therapy. Several cells can manifest an antioxidant enzyme system against the toxic action of ROS such as superoxide dismutase (SOD), glutathione peroxidase and catalase. In ischemic conditions the capacity of antioxidant system is not sufficient to compensate for the increased toxic effects of ROS. The formation of ROS in ischemia tissue leads to injury and damage (10). So, low levels of ROS are serious for normal fertilization, capacitation, hyperactivation and motility (17).

Sperm membrane contains huge volumes of unsaturated fatty acids which provide fluidity, the process that is essential for membrane fusion (18). However, this also makes spermatozoa vulnerable to ROS attack. Seminal fluid is an important source of antioxidants, as the deficiency of cytoplasm and DNA compaction in spermatozoa leaves very little room for translation or for antioxidant defenses. Lipid peroxidation associated with decline in sperm motility (19). However, studies have shown that 30%-80% of male factor infertility cases are due to ROS mediated sperm damage (16). The amount of MDA accumulation in tissue is an index of the extent of lipid peroxidation and oxidative stress. MDA levels reduced in myocardial tissue of the groups receiving tramadol compared to the control group (10). It seems the tramadol-induced protective effect against testicular IR might act via its antioxidant properties (10).

However, to best of our knowledge, no report exists on role of dietary tramadol supplement on sperm characteristics in experimental testicular IR in rat. So, we were not able to compare our results with it. However, several researches have done on effects of other substances on testicular IR injury. For instance, rutin (15), taurine (19) and melatonin (20) protect testes from IR injury. Ashrafzadeh

Takhtfooladi et al (9) reported intravenous injection of 20 mg/kg of tramadol significantly decreased MDA and increased SOD levels in IR myocardial injuries in rat model. These results can be used as base information on effect of tramadol on sperm characteristics in experimental testicular IR in rat. Further researches needed to identify direct cellular and molecular signaling pathways of tramadol on sperm characteristics.

### Ethical Issues

All protocol of the study was approved by ethic committee of Islamic Azad University, Science and Research Branch, Tehran, Iran.

### Conflict of Interests

Authors declare that there is no conflict of interest.

### Financial Support

None.

### Acknowledgments

None.

### References

1. Khaki A, Fathiazad F, Nouri M, Khaki AA, Khamenehi HJ, Hamadeh M. Evaluation of androgenic activity of *Allium cepa* on spermatogenesis in rat. *Folia Morphol (Warsz)*. 2009;68:45-51. doi:10.1016/s0378-5122(09)70166-5
2. Lee B, Jung J, Kim H. Assessment of red onion on antioxidant activity in rat. *Food Chem Toxicol*. 2012;50:3912-9. doi: 10.1016/j.fct.2012.08.004.
3. Barkhordari A, Hekmatimoghaddam S, Ajebali, MA, Khalili, Talebi A, Noorani M. Effect of zinc oxide nanoparticles on viability of human spermatozoa. *Iran J Reprod Med*. 2013;11:767-771.
4. Ghiasi Ghalehkandi J. Garlic (*Allium sativum*) juice protects from semen oxidative stress in male rats exposed to chromium chloride. *Anim Reprod*. 2015;11(4):526-32.
5. Visser AJ, Heyns CF. Testicular function after torsion of the spermatic cord. *BJU Int*. 2003;92:200-3. doi: 10.1046/j.1464-410x.2003.04307.x.
6. Minutoli L, Antonuccio P, Romeo C, et al. Evidence for a role of mitogen-activated protein kinase 3/ mitogen-activated protein kinase in the development of testicular ischemia-reperfusion injury. *Biol Reprod*. 2005;73:730-6. doi: 10.1095/biolreprod.105.040741.
7. Ashrafzadeh Takhtfooladi M, Moayer F, Ashrafzadeh Takhtfooladi H. Beneficial effect of pentoxifylline into the testis of rats in an experimental model of unilateral hindlimb ischemia/reperfusion injury. *Int Braz J Urol*. 2015;41(3):576-83. doi:10.1590/s1677-5538.ibu.2014.0263
8. Nagakannan P, Shivasharan BD, Thippeswamy BS, Veerapur VP. Effect of tramadol on behavioral alterations and lipid peroxidation after transient forebrain ischemia in rats. *Toxicol Mech Methods*. 2012;22(9):674-8. doi:10.3109/15376516.2012.716092.
9. Ashrafzadeh Takhtfooladi M, Haghghi Khiabani Asl A, Shahzamani M, Ashrafzadeh Takhtfooladi M, Allahverdi A, Khansari M. Tramadol alleviates myocardial injury induced by acute hindlimb ischemia reperfusion in rats. *Arq Bras Cardiol*. 2015;105(2):151-9. doi: 10.5935/abc.20150059.
10. Bilir A, Erkasap N, Koken T, et al. Effects of tramadol on myocardial ischemia-reperfusion injury. *Scandinavian Cardio J*. 2007;41:242-7. doi: 10.1080/14017430701227747.
11. Zimmermann M. Ethical guidelines for investigations of experimental pain in conscious animals. *Pain*. 1983;16:109-10. doi: 10.1016/0304-3959(83)90201-4.
12. Turner TT. The study of varicocele through the use of animal models. *Hum Reprod Update*. 2001;7:78-84. doi: 10.1093/humupd/7.1.78.
13. Sahin Z, Bayram Z, Celik-Ozenci C, et al. Effect of experimental varicocele on the expressions of notch 1, 2, 3 in rat testes: an immunohistochemical study. *Fertil Steril*. 2005;83:86-94. doi: 10.1016/j.fertnstert.2004.09.006.
14. Seed J, Chapin RE, Clegg ED, et al. Methods for assessing sperm motility, morphology, and counts in the rat, rabbit, and dog: a consensus report. ILSI Risk Science Institute Expert Working Group on Sperm Evaluation. *Reprod Toxicol*. 1996;10: 237-44. doi: 10.1016/0890-6238(96)00028-7.
15. Wei SM, Yan ZZ, Zhou J. Protective effect of rutin on testicular ischemia-reperfusion injury. *J Pediatr Surg*. 2011;46:1419-24. doi: 10.1016/j.jpedsurg.2010.09.044.
16. Agarwal A, Durairajanayagam D, Halabi J, Peng J, Vazquez-Levin M. Proteomics, oxidative stress and male infertility. *Reprod Biomed Online*. 2014;29(1):32-58. doi: 10.1016/j.rbmo.2014.02.013.
17. Agarwal A, Makker K, Sharma R. Clinical relevance of oxidative stress in male factor infertility: an update. *Am J Reprod Immunol*. 2008;59:2-11. doi: 10.1111/j.1600-0897.2007.00559.x.
18. Hwang K, Lamb DJ. Molecular mechanisms of male infertility. In: Parekattil SJ, Agarwal A, eds. *Male Infertility*. New York: Springer; 2012. doi: 10.1007/978-1-4614-3335-4\_5.
19. Wei SM, Yan ZZ, Zhou J. Beneficial effect of taurine on testicular ischemia-reperfusion injury in rats. *Urology*. 2007;70:1237-42. doi: 10.1016/j.urology.2007.09.030.
20. Takhtfooladi H, Takhtfooladi M, Moayer F, Mobarakeh S. Melatonin attenuates lung injury in a hind limb ischemia-reperfusion rat model. *Rev. Port. Pneumol*. 2015;21(1):30-5. doi: 10.1016/j.rppnen.2014.01.010.

**Copyright** © 2016 The Author(s); This is an open-access article distributed under the terms of the Creative Commons Attribution License (<http://creativecommons.org/licenses/by/4.0>), which permits unrestricted use, distribution, and reproduction in any medium, provided the original work is properly cited.