



A Study of the Therapeutic Effects of Vitamin E on Testicular Tissue Damage Caused by Fluoxetine

Tohid Jalili¹, Arash Khaki^{2*}, Zahra Ghanbari³, Amir Mahdi Imani⁴, Farzam Hatefi⁵

Abstract

Objective: Fluoxetine is widely used in the treatment of neurological disorders. Hence, considering the adverse effects of this drug on the endocrine axes of the body is very important. Fluoxetine has been shown to cause significant changes in testicular tissue structure and sex hormones in rats. It seems that antioxidant compounds such as vitamin E can reduce free radicals and inhibit these changes. Therefore, the aim of this study is to investigate the therapeutic effects of vitamin E on testicular tissue damage caused by fluoxetine use.

Materials and Methods: In the present study, 40 Wistar rats (weight = 250 ±10 gr) were randomly divided into 4 groups; control group that received normal saline (with intraperitoneal (IP) method), fluoxetine group (n = 10) that received 10 mg/kg of fluoxetine (IP), vitamin E group (n = 10 that received 100 mg/kg of vitamin E (IP), and the treatment group that received both vitamin E (100 mg/kg) and fluoxetine (10 mg/kg) for 28 days. On the 28th day of the study testis tissue was removed and sent to the pathology lab and blood samples were taken for analyzing of testosterone and total antioxidant capacity.

Results: The highest testosterone levels are related to the control group and the lowest levels are related to the fluoxetine receiving group. Significant differences were observed between sperm density in the seminiferous tubes, spermatogonia cells, and primary spermatocyte, and leydig and sertoli cells in the experimental groups compared to the control group after a 28-day period.

Conclusion: Fluoxetine can damage the leydig cells and decrease activity of testis and production of testosterone, but vitamin E can repair the leydig cells and reduce damages caused by fluoxetine.

Keywords: Fluoxetine, Testis, Testosterone, Vitamin E

Introduction

Fluoxetine is a selective serotonin reuptake inhibitor drug. Given the importance of this drug in the treatment of neurological diseases, such as obsessive-compulsive disorder, bulimia nervosa, and depression, its side effects on the endocrine axes are of great importance. Fluoxetine entered the pharmaceutical market in America in 1987, and since then, it has had the highest prescription rate as antidepressant by psychiatrists. In fact, most

information about antidepressants has been gained from studies on fluoxetine which showed that this drug caused significant structural changes of testicular tissue and sex hormones in male rats (1,2). Vitamins E and C are antioxidant compounds, and due to their polyphenol components, they rapidly generate free radicals and protect sperm; thus, vitamin E and C deficiency can lead to infertility (3,4). Therefore, in this study, vitamin E was used as a natural antioxidant substance in rats treated with fluoxetine.

Received: 12 Dec 2013, Revised: 20 Jan 2014, Accepted: 16 Feb 2014, Available online: 15 Apr 2014

¹ Department of Pathology, College of Vet Medicine, Tabriz Branch, Islamic Azad University, Tabriz, Iran

² Women's Reproductive Health Research Center, Tabriz University of Medical Sciences, Tabriz, Iran

³ Department of Pediatrics, Faculty of Medicine, Zanjan University of Medical Sciences, Zanjan, Iran

⁴ Department of Histopathology, Sari Branch, Islamic Azad University, Sari, Iran

⁵ Department of Pathology, College of Veterinary Medicine, Tabriz Branch, Islamic Azad University, Tabriz, Iran

*Corresponding Author: Arash Khaki, Women's Reproductive Health Research Center, Tabriz University of Medical Sciences, Tabriz, Iran

Tel: +98 9143138399, Email: arashkhaki@yahoo.com

Materials and Methods

In the present study, 40 male Wistar rats (weight = 250 ± 10 g) were used. They were randomly divided into 4 groups. The rats were kept in darkness from 7 am to 7 pm. All behavioral tests were performed between 1 and 6 pm and during the dark phase of the light cycle.

First group: The rats were injected with normal saline using intraperitoneal (IP) method for 4 weeks (28 days) and this group was called control group.

Second group: This group was called the fluoxetine group in which 10 male rats were given 10 mg/kg fluoxetine using IP methods for 4 weeks (28 days).

Third group: This group was called vitamin E group in which 10 male rats were given 100 mg/kg vitamin E using IP methods for 4 weeks (28 days).

Fourth group: this group was called the treatment group in which 10 male rats were given a combination of 100 mg/kg vitamin E and 10 mg/kg fluoxetine for 4 weeks (28 days).

On the 28th day of the study, in the first phase, samples were taken from each of the 4 groups of rats, and after collecting blood from the eye, all the rats from each group were killed and samples were taken. Testicular tissue samples were collected for light microscopy. The samples were fixed in 10% formalin and referred to the pathology laboratory. Then, they were stained with hematoxylin and eosin and were studied by light microscopy (3,5).

To investigate the changes in testosterone serum level, serum samples were used. Testosterone levels were measured by radioimmunoassay (6). All animals in the study were killed based on the act of animal protection (4).

The results of statistical studies were analyzed by ANOVA using SPSS for Windows (version 17, SPSS Inc., Chicago, IL, USA).

Results

All results related to the mean measurement of testosterone levels are given in table 1. The highest mean obtained was related to the control group and the lowest mean was obtained from the group receiving fluoxetine. The results of histological studies showed significant differences in sperm density in seminiferous tubule, and the number of spermatogonia cells, primary spermatocytes, and leydig in the experimental groups compared to the control group after a period of 28 days (Figures 1-4).

Discussion

Infertility and problems related to it are one of the most important issues in the life of couples' (7). According to statistics, 35% of infertilities are related to men and 25% of infertility cases are related to both spouses. The most common cause of male infertility is inability to produce sufficient numbers of healthy and active sperms (8,9).

Table 1. Comparison of mean testosterone levels and total antioxidant plasma in the study groups

Groups	Serum testosterone levels (ng/ml)	Total antioxidant plasma (TAC)
Control	2.60 ± 0.05	0.55 ± 0.05
Fluoxetine	1.11 ± 0.01	0.38 ± 0.05
Vitamin E	2.31 ± 0.05	0.59 ± 0.66
Treatment	1.87 ± 0.01	0.51 ± 0.66

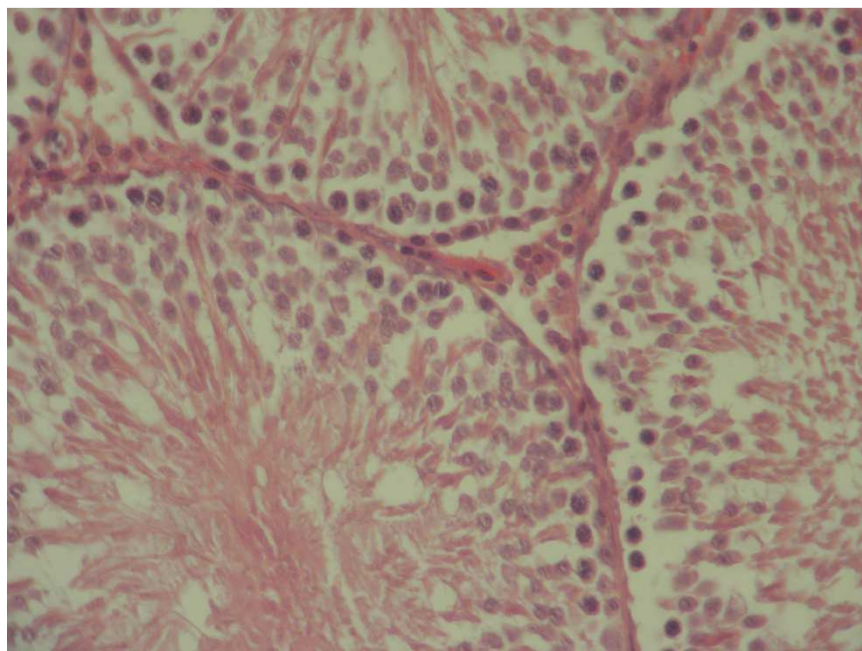


Figure 1. Sections of testicular tubules of Wistar rats in the control group, regularity of testicular tubules should be noted (H & E stained, magnification × 160)

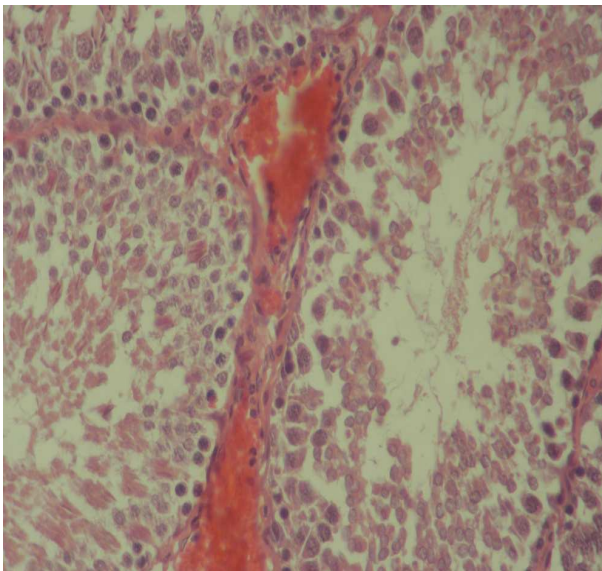


Figure 2. Sections of testicular tubules of Wistar rats in the fluoxetine group, the loss of germ cells and interstitial inflammation and interstitial tissue fibrosis should be noted (H & E stained, magnification $\times 160$)

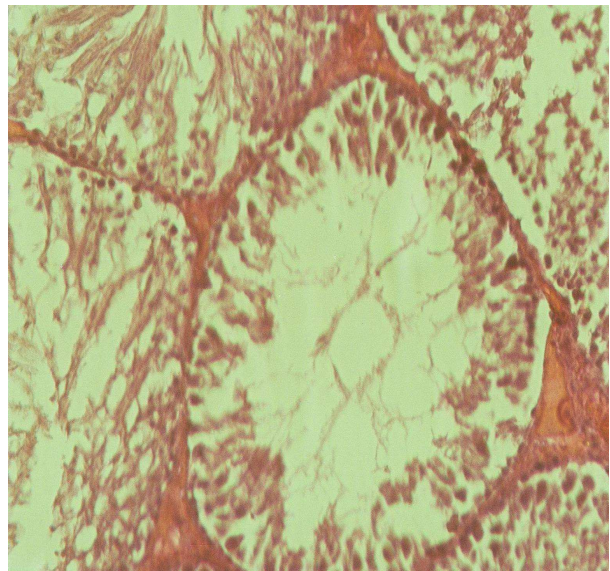


Figure 4. Sections of testicular tubules of Wistar rats in the treatment group, regularity of seminiferous tubules compared to the study groups should be noted (H & E stained, magnification $\times 160$)

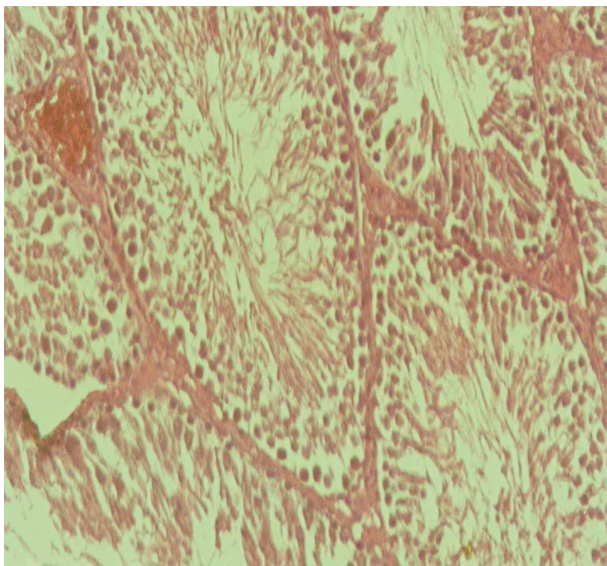


Figure 3. Sections of testicular tubules of Wistar rats in the vitamin E group, regularity of seminiferous tubules and sperm concentration in seminiferous tubules should be noted (H & E stained, magnification $\times 160$)

Many factors can affect sperm production and infertility risks. Among these factors are using chemotherapy drugs for cancer, antibiotics, toxic substances, selective serotonin reuptake inhibitor drugs, pesticides, radiation, stress, air pollution, and lack of adequate vitamins. These factors with the creation of free radicals and oxidation of germ cells in the testis can reduce sperm concentration (10,11). Fluoxetine is an antidepressant of the serotonin reuptake inhibitor drug group. Its use has been accepted for the treatment of major depression and bipolar, dysthymic, and seasonal mood disorders, obsessive compulsive disorder, panic disorder,

premenstrual dysphoric, hair-pulling disorder, posttraumatic stress disorder, social anxiety, body deformities, dependence in smokers, premature ejaculation, chronic fatigue syndrome, Raynaud's phenomenon, depression after brain stroke, hot flashes, and anorexia (1,2). This drug functions by inhibiting specific serotonin reuptake by the presynaptic nerve cell membrane resulting in increased synaptic concentrations in the central nervous system, and thus, exerts its effect. Fluoxetine by affecting the pituitary-gonadal axis can reduce spermatogenesis (1,2). Studies have shown that antioxidants and vitamins C, E, and B can strengthen the blood-testis barrier, protect and repair sperm DNA, and can be effective in treating male infertility by reducing the damage caused by free radicals (8,11,12). Previous studies have shown that the prevalence of infertility in men is increasing (13). Vitamins can be effective in increasing fertility and treating hormonal imbalance, erectile dysfunction (impotence), oligospermia, slow movement of the sperm, prostate inflammation, varicocele, and etcetera. Researches have shown that vitamins E, C, and B have a positive effect on the process of spermatogenesis through reducing the toxic effects of cadmium on testicular tissue (14). Researches on vitamins E and C and other antioxidants, such as glutathione and coenzyme Q₁₀, showed that these compounds were effective in the treatment of male infertility and protection of DNA in the cell nucleus which were caused due to stress, environmental pollution, and malnutrition (15,16). Malnutrition and lack of vitamin B cause damage to the spermatogenesis process due to their role in DNA cell repair, synthesis, and development (7,17). Research has shown those that diets high in folic acid and zincs (Zn) are able to increase 74% of the total sperm count (7). Vitamins B and C, zinc (Zn), and folic acid in reducing the effect of activated oxygen species (oxygen free radicals), improves the quality of semen

and reduces apoptosis spermatozoa. Moreover, it has been shown that vitamin E, as an antioxidant, has the ability to reconstruct seminiferous tubules after damages caused by ozone gas and reduces the harmful effects of this gas on testicular tissue and strengthens the blood-testis barrier. This research showed vitamin E to be an effective antioxidant in dealing with external and toxic factors in testicular tissue (18,19).

The results of this study indicated that vitamin E in combination with fluoxetine treatment caused improvement in spermatogenesis and reduced the loss of germ cells, interstitial inflammation, and interstitial fibrosis in macroscopic evaluation. Comparison of the mean testosterone levels showed a significant increase in the treatment group compared to the fluoxetine group. The amount of testosterone reduction in the fluoxetine group was significant compared to the control group. However, it was not significant in the vitamin E group compared to the control group. Previous findings showed the loss of germ cells, interstitial inflammation, and interstitial fibrosis in rats receiving fluoxetine (1,2). This finding was in agreement with the present study.

Conclusion

In summary, the results of this study showed that fluoxetine caused leydig cell damage, and decrease in testicular function and production of testosterone. However, vitamin E can help repair leydig cells and reduce the damage induced by fluoxetine. Therefore, further studies to clarify the mechanism of testicular damages by fluoxetine and repair mechanism of vitamin E are recommended. Furthermore, the use of vitamin E along with fluoxetine is recommended.

Ethical issues

The local ethics committee approved the study.

Conflict of interests

We declare that we have no conflict of interests.

Acknowledgments

The present study (No. 1876) was funded by the Research deputy of the Tabriz Branch of the Islamic Azad University, Iran.

References

- Gouvea TS, Morimoto HK, de Faria MJ, Moreira EG, Gerardin DC. Maternal exposure to the antidepressant fluoxetine impairs sexual motivation in adult male mice. *Pharmacol Biochem Behav* 2008; 90: 416-9.
- Csoka AB, Bahrick A, Mehtonen OP. Persistent sexual dysfunction after discontinuation of selective serotonin reuptake inhibitors. *J Sex Med* 2008; 5: 227-33.
- Sahoo DK, Roy A, Chainy GB. Protective effects of vitamin E and curcumin on L-thyroxine-induced rat testicular oxidative stress. *Chem Biol Interact* 2008; 176: 121-8.
- Acharya UR, Mishra M, Patro J, Panda MK. Effect of vitamins C and E on spermatogenesis in mice exposed to cadmium. *Reprod Toxicol* 2008; 25: 84-8.
- Bataineh HN, Daradka T. Effects of long-term use of fluoxetine on fertility parameters in adult male rats. *Neuro Endocrinol Lett* 2007; 28: 321-5.
- Vessal M, Hemmati M, Vasei M. Antidiabetic effects of quercetin in streptozocin-induced diabetic rats. *Comp Biochem Physiol C Toxicol Pharmacol* 2003; 135C: 357-64.
- Aitken RJ. The Amoroso Lecture. The human spermatozoon--a cell in crisis? *J Reprod Fertil* 1999; 115: 1-7.
- Amin A, Hamza AA. Effects of Roselle and Ginger on cisplatin-induced reproductive toxicity in rats. *Asian J Androl* 2006; 8: 607-12.
- Baker MA, Aitken RJ. The importance of redox regulated pathways in sperm cell biology. *Mol Cell Endocrinol* 2004; 216: 47-54.
- Amin A, Hamza AA. Effects of Roselle and Ginger on cisplatin-induced reproductive toxicity in rats. *Asian J Androl* 2006; 8: 607-12.
- Brooks DE. Activity and androgenic control of glycolytic enzymes in the epididymis and epididymal spermatozoa of the rat. *Biochem J* 1976; 156: 527-37.
- Chu FF. The human glutathione peroxidase genes GPX2, GPX3, and GPX4 map to chromosomes 14, 5, and 19, respectively. *Cytogenet Cell Genet* 1994; 66: 96-8.
- Hosseini Ahar N, Khaki A, Akbari G, Ghaffari Novin M. The Effect of Busulfan on Body Weight, Testis Weight and MDA Enzymes in Male Rats. *International Journal of Women's Health and Reproduction Sciences*. 2014; 2 :316-9.
- Grzanna R, Lindmark L, Frondoza CG. Ginger--an herbal medicinal product with broad anti-inflammatory actions. *J Med Food* 2005; 8: 125-32.
- Mosher WD, Pratt WF. Fecundity and infertility in the United States: incidence and trends. *Fertil Steril* 1991; 56: 192-3.
- Murakami A, Tanaka T, Lee JY, Surh YJ, Kim HW, Kawabata K, et al. Zerumbone, a sesquiterpene in subtropical ginger, suppresses skin tumor initiation and promotion stages in ICR mice. *Int J Cancer* 2004; 110: 481-90.
- Murugesan P, Muthusamy T, Balasubramanian K, Arunakaran J. Studies on the protective role of vitamin C and E against polychlorinated biphenyl (Aroclor 1254)-induced oxidative damage in Leydig cells. *Free Radic Res* 2005; 39: 1259-72.
- Noumi E, Amvan ZP, Lontsi D. Aphrodisiac plants used in Cameroon. *Fitoterapia* 1998; 69: 125-34.
- Kumar R, Gautam G, Gupta NP. Drug therapy for idiopathic male infertility: rationale versus evidence. *J Urol* 2006; 176: 1307-12.

Citation: Jalili T, Khaki A, Ghanbari Z, Imani AM, Hatefi F. **A Study of the Therapeutic Effects of Vitamin E on Testicular Tissue Damage Caused by Fluoxetine Use.** Crescent J Med & Biol Sci 2014; 1(2): 37-41.