



Determination of the Protective Impact of *Hypericum perforatum* Extract Against Ovarian Ischemia and Reperfusion in Rats

Seyit Ali Bingöl¹, Serdar Yiğit¹, Ergin Taşkın², Fatma Necmiye Kacı³, Muhammed Yayla⁴, Nurcan Kılıç Baygutalp⁵, Erdem Toktay¹, Nilnur Eyerci⁶, Hasan Çilgin⁷

Abstract

Objectives: Ovarian torsion is an important gynaecological emergency because it causes ischemia in ovary. Our aim is to research the effects of *Hypericum perforatum* on p53, TNF- α , CAT, SOD, GSH, PTEN and is haPI3K/Akt/mTOR pathway in ovarian of rats with ischemia reperfusion (I/R) injury.

Materials and Methods: The study included 56 adult female rats which were allocated to 7 groups; control, ischemia, ischemia 300HP, ischemia 600HP, I/R, I/R 300HP and I/R 600HP. *H. perforatum* was applied to ischemia 300HP, ischemia 600HP, I/R 300HP and I/R 600HP groups at the dose of 300 mg/kg or 600 mg/kg by oral gavage. Collected ovarian tissues were examined by light microscopy, biochemical and real-time PCR techniques.

Results: In histological examination, the least degeneration was seen in 600HP group among other groups, apart from control group. TUNEL results showed that apoptosis level of other groups was lower than that of ischemia and I/R groups. CAT and GSH levels of I/R 600HP group increased. The highest level of PTEN and mTOR was found in the ischemia group. The Akt level was lower in I/R and I/R 300HP groups but its level was close to that of control and I/R 600HP groups. TNF- α and p53 mRNA expressions in I/R group were increased.

Conclusions: The result of the study showed that *H. perforatum* (600 mg/kg) had an effect on tissue degeneration, CAT and GSH levels, and also TNF- α and p53 mRNA expressions levels. We suggest that *H. perforatum* can be considered as an agent to protect against tissues damage during ischemia reperfusion.

Keywords: Ovary, Ischemia/reperfusion, Antioxidant, p53, PTEN

Introduction

Ovarian torsion, also known as adnexal torsion, is an important gynaecological emergency because it has a partial or complete twist that blocks the vascular support and causes ischemia in the ovary (1,2). If a twisted ovary is left untreated, the ischemia results in necrosis of the ovary or entire adnexa that negatively affects fertility in young women. Early surgical intervention is recommended for detorsion ovarian torsion occurs; however, if the necrosis is not severe (2). After detorsion, ischemia-reperfusion (I/R) damage occurs when reperfusion starts. Increased oxygen level by re-circulation elevates reactive oxygen species (ROS), which cause ovarian tissue damage at the cellular level (3).

Hypericum perforatum L. (St. John's wort) belongs to the *Clusiaceae* family and has yellow flowers. It is a perennial plant that grows as natively in some parts of Europe,

Asia and Africa, but it also grows in some parts of other continents (4). It is among the most widely consumed medicinal plants in the world (5). *H. perforatum* has been used to treat some diseases like eczema, alimentary tract problems and depression (6,7). In addition, *H. perforatum* has properties such as anti-inflammatory, antioxidant, anti-viral and wound healing (8,9).

The organism has a defence system against the harmful effect of ROS. Some molecules of these defence system are glutathione (GSH) and superoxide dismutase (SOD) and catalase (CAT). These enzymes protect the tissues from ROS and oxidative stress (10, 11). Malondialdehyde (MDA) produced by ROS is the final output of lipid peroxidation, and it is used as an indirect indicator of ROS (10). ROS also has an important role to induce apoptosis (12).

There is a positive correlation between the apoptotic cell

Received 9 November 2023, Accepted 1 April 2024, Available online 12 April 2024

¹Department of Histology and Embryology, Faculty of Medicine, Kafkas University, Kars, 36100, Türkiye. ²Department of Medical Biochemistry, Faculty of Medicine, Agri Ibrahim Cecen University, Ağrı, 04100, Türkiye. ³Department of Molecular Biology and Genetics, Faculty of Science, Erzurum Technical University, Erzurum, 25050, Türkiye. ⁴Pharmacology Department, Faculty of Medicine, Kafkas University, Kars, 36100, Türkiye. ⁵Department of Biochemistry, Faculty of Pharmacy, Ataturk University, Erzurum, 25240, Türkiye. ⁶Department of Medical Biology, Faculty of Medicine, Kafkas University, Kars 36100, Türkiye. ⁷Medical Park Hospital, Department of Obstetrics and Gynaecology Elazığ, Türkiye (Formerly Department of Obstetrics and Gynaecology, Faculty of Medicine, Kafkas University, Kars, 36100, Türkiye).

*Corresponding Author: Seyit Ali Bingöl, Tel: +905326930537, E-mail: seyitali.bingol@gmail.com



Key Messages

- ▶ Ovarian torsion is a gynaecological emergency so early surgical intervention is recommended.
- ▶ I/R looks more harmful than only ischemia.
- ▶ Ischemia and I/R decreased some antioxidants like CAT and GSH, but *H. perforatum* increased CAT and GSH level during ischemia and I/R.
- ▶ *H. perforatum* has also suppressive effect on PTEN, TNF- α and p53.
- ▶ *H. perforatum* can be considered as an agent to protect against tissue damage during ischemia and reperfusion but it still needs to investigate it in detail.

number and the ischemia in the ovary (13). There are many kinds of molecules that play a key role in apoptosis such as phosphatase and tensin (PTEN), phosphatidylinositol 3-kinase (PI3K), the mammalian target of rapamycin (mTOR), protein kinase B (PKB) also known as Akt and p53 (14). PTEN and p53 have interdependent functions in increasing apoptosis (15). PTEN is also known as a negative regulator of PI3K. Therefore, PI3K/Akt/mTOR pathway decreases apoptosis (14). In addition, some cytokines like tumor necrosis factor-alpha (TNF- α) increases during I/R (16).

In this present study, we sought to examine the effects of *H. perforatum* on p53, TNF- α , antioxidant enzymes and PTEN, PI3K/Akt/mTOR pathway, which have important role in apoptosis, in the ovarian rats with I/R injury.

Materials and Methods

Experimental Design

Microsurgical sets were used for all surgical procedures. Incision was performed in the low middle abdomen. Before that, the skin was shaved, then cleaned with 10% povidone-iodine (Batticon; Adeka Laboratories, Türkiye) to provide asepsis. Before all surgery procedures, animals were anesthetized by injecting ketamine 90 mg/kg (Keta-Control, Doga ilac, Türkiye) and xylazine 10 mg/kg (Vetaxyl, VetAgro, Poland) intramuscularly.

In this study, 56 Wistar-albino adult female rats (body weight between 160-200 g) were utilised. The rats were taken from Medical Experimental Applications and Research Centre of Atatürk University and they were kept in a standard laboratory environment with 12 hours of dark/light at constant temperature, and humidity. In this process, the experimental animals were liberated get to food and water ad libitum. The rats were divided equally into seven groups blindly by the scientist who did not know which group was which.

- Group I (Control): Only the abdominal region was opened and closed, but no application was made to the ovaries.
- Group II (Ischemia): Bilateral ischemia was created in the ovaries by applying microvascular clamps for three hours and ovaries removed at the end of this three hours.

- Group III (Ischemia HP300): Bilateral ischemia was made in the same way as group II, and 300 mg/kg of *H. perforatum* extract (Palen, Ari Muhendislik, Ankara, Türkiye) was administered by oral gavage 2 hours before the end of the ischemia (4).
- Group IV (Ischemia HP600): Unlike the group III, 600 mg/kg of *H. perforatum* extract was administered.
- Group V (I/R): Bilateral ischemia was created in the ovaries in the same way. The clamps were removed 3 hours later, and reperfusion was allowed for another three hours (11,16).
- Group VI (I/R HP300): Bilateral ischemia was created in the ovaries for 3 hours. After 3 hours, the vascular clamp was discharged, and reperfusion was ensured in the ovaries for three hours. *H. perforatum* extract (300 mg/kg) was administered by gavage 2 hours prior to the end of the reperfusion.
- Group VII (I/R HP600) received 600 mg/kg of *H. perforatum* extract, in contrast to group VI.

After the ovarian tissues were surgically removed under anaesthesia, some parts were taken to formalin for histological and immunohistochemical examination, and the other parts were put at -80 °C for biochemical and molecular examination.

Histological and Immunohistochemical Examination

The tissues were subjected to a routine histological process after their fixation in 10% formalin then they were blocked in paraffin and then sections with a thickness of 5 μ m were taken with a microtome (Leica-RM2125 RTS, Germany), stained with Hematoxylin and Eosin stain (H&E), and then examined with a light microscope (Olympus BX43, Japan).

Avidin Biotin Peroxidase Complex (ABC) technique was used to determine p53 protein expression and localization in ovarian tissue. The sections were deparaffinised, rehydrated, and washed in phosphate buffer solution (PBS), respectively. They were incubated in 3% H₂O₂ to avoid endogenous peroxidase activity in tissues. After washing with PBS again, sections were rinsed in a citrate buffer solution and put into a microwave oven for antigen revival. Then, serum (10%, Ultra V Block, Fremont CA) for 10 minutes, the anti-p53 antibody concentration of 1/250 (Pab 1801, Santa Cruz, United States) for 1 hour, secondary antibody (biotinylated goat anti rabbit, Ultravision, Lab Vision, Fremont, CA) for 30 minutes, and streptavidin peroxidase (Lab Vision, CA) for 30 minutes were applied to the sections, and they were washed between each steps with PBS three times every 5 minutes for a total duration of 15 minutes. The Diaminobenzidine (DAB substrate, Thermo, TA 125-HD) was used as a chromogen (17). The slides were examined under light microscope (Olympus BX43, Japan) after they were stained with hematoxylin as a counterstain.

TUNEL Analysis

The sections were deparaffinised and incubated with proteinase K. The TUNEL analysis was performed according to the company guidelines (TUNEL Apoptosis Assay Kit, Elabscience-Cat No: E-CK-A331). At the end of this process, slides were observed under light microscope (Olympus BX43, Japan), and obtained images using cellSens program to analysis.

Biochemical Analysis

Superoxide radicals were formed when xanthine was converted to uric acid by the xanthine oxidase enzyme. The superoxide radicals reacted with nitro blue tetrazolium, and then form blue formazan dye. The SOD activity was measured by using a spectrophotometer (18). The Aebi's method was used for the CAT activity measurement in ovarian tissue. This method is based on measuring the time-dependent decrease in absorbance of H_2O_2 at 240 nm in the tissue homogenate (19). PTEN, PI3K, Akt and mTOR were analysed by using ELISA test kits (PTEN, Cat No: E1081Ra; PI3K, Cat No: E0438Ra; Akt, Cat No: E0201Ra; mTOR, Cat No: E2096Ra, Bioassay Technology Laboratory, China). The easy-to-use microplate, controls, conjugate, dilution buffer, substrate and stop solution were used for ELISA analysis.

Real-Time PCR Analysis

Ovarian tissues were taken for PCR analysis and placed at $-80\text{ }^{\circ}\text{C}$. Total RNA was isolated by using EcoPURE Total RNA kit (EcoTech Biotechnology, Erzurum, Türkiye), which was used in keeping with the instruction specified by the company. We analysed the p53 and TNF- α expression with Real-Time PCR. Their mRNA

expression was quantitatively determined by real-time PCR. Amplification and quantification were done on the StepOne Plus Real Time PCR System.

Statistical Analysis

In this study, biochemical, ELISA and Real-Time PCR results were statistically compared between groups. The significant differences of biochemical and ELISA results were determined by using One-way ANOVA (SPSS, IBM Corp., Armonk, NY, USA). RT-PCR data were analysed with Origin Pro Lab 8.5 data analysis and graphing software. The significant difference between groups was accepted if the P value is <0.5 .

Results

Histological, Immunohistochemical and TUNEL Results

When ovarian tissues stained with H&E were examined, degeneration of follicles was detected in all groups except the control group. Among the groups with degeneration in their follicles, the least degeneration was observed in that of the group VII allowed reperfusion and treated with 600 mg/kg *H. perforatum* after the ischemia (Figure 1A). In the TUNEL staining, apoptosis was seen in the follicle cells in all groups. While the degree of apoptosis in the groups I and VII was lower than that of other groups, the degree of apoptosis in the groups II and V was higher than that of other groups (Figure 1B). In the immunohistochemical examination, it was not observed any difference among groups in terms of p53 immunoreactivity (Figure 1C).

Biochemical Results

Regarding GSH and CAT activity, a significant difference was determined between the groups in ovarian tissue

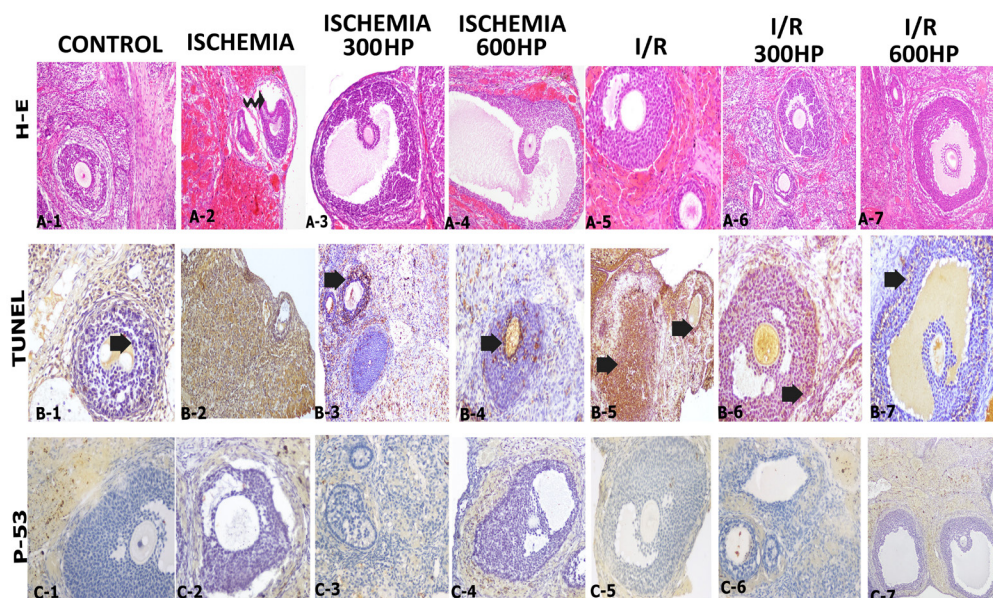


Figure 1. A. H&E staining (Curved arrow: follicle degeneration), A1-7, 20X. B. TUNEL staining (Thick arrow: TUNEL positive cells), B1, 20X; B2-3, 10X; B4, 20X; B5, 10X; B6-7, 20X. C. p-53 immunoreactivity, C1-7, 20X.

($P < 0.05$) but the SOD and MDA did not reflect the statistics difference between the groups. Group I had the highest level of the CAT activity, and was different statistically from group II, III, V and VI, but showed similarities to group IV and VII (Figure 2). According to the statistical analysis of ELISA data, we found an important difference among the groups for PTEN, Akt, and mTOR levels ($P < 0.05$), but no difference between the groups for PI3K levels ($P > 0.05$). Group II had highest PTEN level, and group V had the lowest PTEN level. The

Akt and mTOR levels in group VI was prominently lower than that in group I (Figure 3).

Real-Time PCR Results

In the I/R group, TNF- α mRNA expression was statistically greatest. The level of p53 mRNA expression level varied statistically between the I/R and Ischemia 600HP groups. The highest level of the TNF- α and the p53 mRNAs was also found in the same group (group V) whose ovary had ischemia and reperfusion (Figure 4).

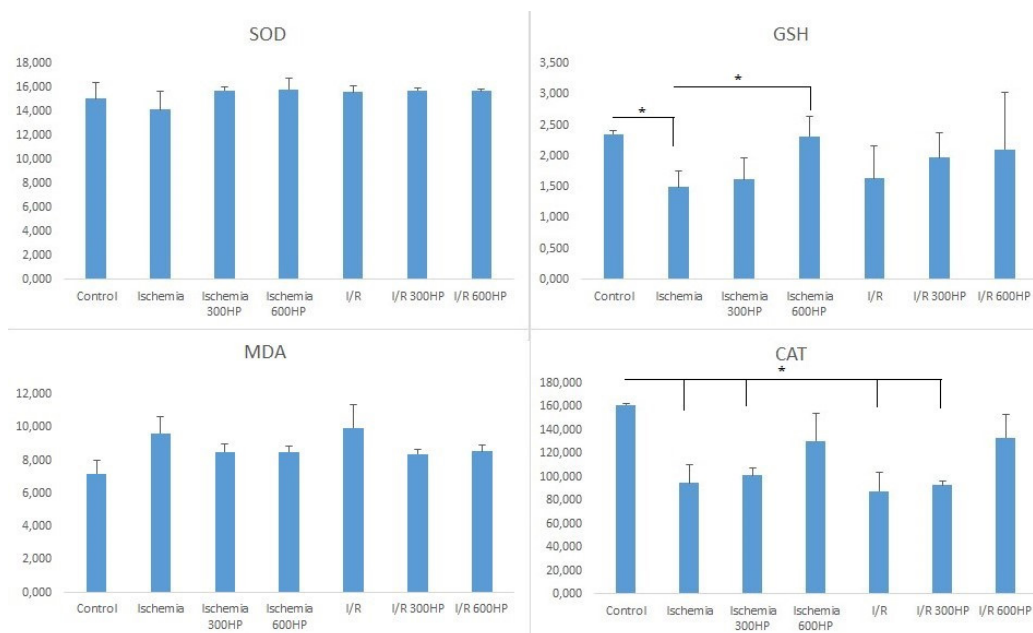


Figure 2. Comparison of SOD, GSH, MDA and CAT Between the Groups. Asterisk sign means $P < 0.05$.

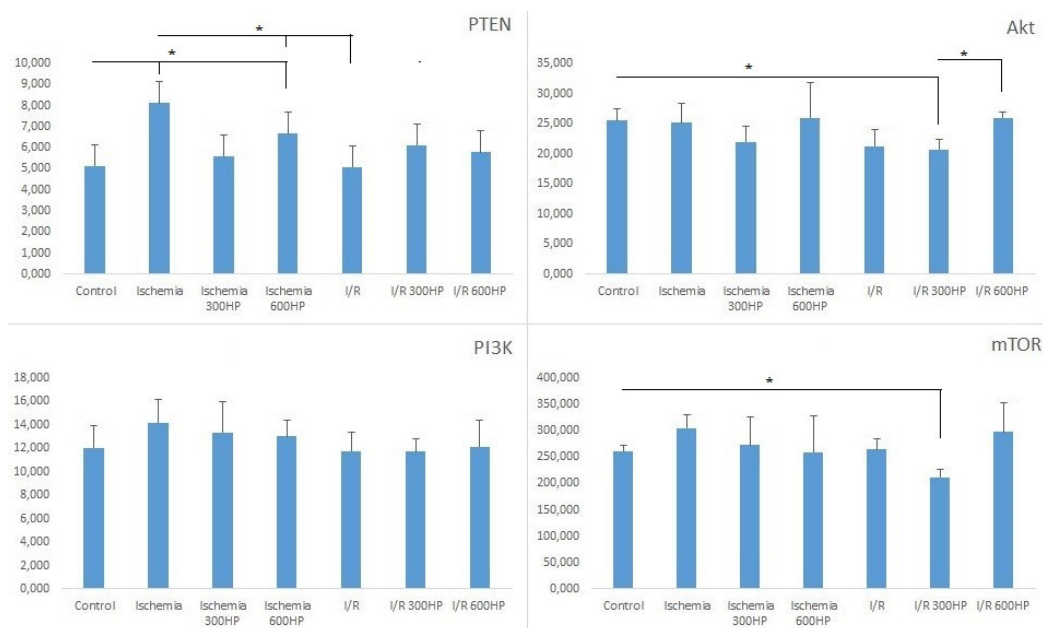


Figure 3. Comparison of PTEN, PI3K, Akt and mTOR Between the Groups. Asterisk sign means $P < 0.05$.

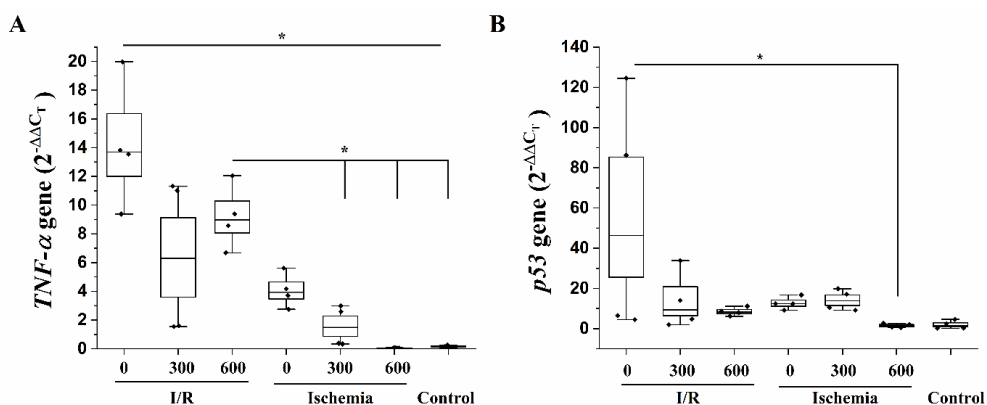


Figure 4. PCR Results of TNF- α (A) and p53 (B). Asterisk sign means $P < 0.05$, $2^{-\Delta\Delta C_T}$ means fold changes.

Discussion

Ovarian torsion continues to be among the most severe gynaecological health problems for women (20). During torsion, the blood flow is blocked so oxygen and any other component, which tissues need, cannot reach to the ovary and waste products in tissues cannot be transported to the blood flow from the ovary (21). All these events cause ovarian ischemia, which requires emergency treatment, and any delay in on its treatment results in oophorectomy and also infertility (22). Because of the severe condition in the torsion and detorsion, our aim was to investigate the effect of *H. perforatum* on both experimental ischemia and ischemia/reperfusion in rat ovarian tissue by using histological and immunohistochemical techniques and analysing p53, TNF- α , antioxidant enzymes, PTEN and PI3K/Akt/mTOR pathway.

Many important organs such as brain, heart, lung, kidney etc. can develop I/R and it may cause serious damage in those organs. Recently, it is tried to reveal the relationship between apoptosis and I/R. And it is also known that follicular degeneration in ovary is seen during I/R (23). Kirmizi et al (24) found that apoptotic cells increased more in the I/R group. Our histological and TUNEL results were similar to the previous studies (23,24) in terms of results in the I/R group. From these results, it was concluded that the reperfusion after ischemia had done serious damage to the tissue and its cells. A previous study determined that p53 immunoreactivity in control group ovaries tissue was hardly observed but it was observed in the ischemia group (25). We found that p53 immunoreactivity did not show a statistical difference between groups. The duration of our study may be too short to determine the p53 immunoreactivity difference between the groups for p53 protein translation after p53 mRNA transcription.

A study determined that CAT and SOD levels in ovarian tissue were statistically lower in the I/R group, and the MDA level was higher in the I/R group (26). In other study, authors mentioned that SOD, CAT, and GSH levels in ovarian tissue of the I/R group were lower than that of

the control group, and the MDA level in the I/R group was found to be higher than that of the control group (27). In the present study, CAT and GSH activity in ovarian tissue decreased in the ischemia and I/R groups, but GSH and CAT in I/R 600HP and Ischemia 600HP groups were similar to the control group. It is considered that high dose of *H. perforatum* supported antioxidant system via CAT and GSH. Unlike the results of the abovementioned studies (26,27), the present study found that the SOD level and the increasing MDA levels did not reflect statistically on results between the groups. Another study, in which cardiac ischemia reperfusion was searched, reported that mTOR and Akt values in I/R group were found higher than that of the sham group (28). He et al (29) found that PTEN was highly expressed after I/R when they studied on human cardiomyocyte. In our study, PTEN, Akt and mTOR levels showed the significant difference between groups but not PI3K level ($P > 0.05$). PTEN had the highest level in the ischemia group, and *H. perforatum* decreased PTEN levels in both doses. The Akt and mTOR levels in the control group were higher than that in I/R 300HP. The protection effect of *H. perforatum* against I/R may be mainly achieved through the PTEN, and also PI3K/Akt/mTOR pathway because of relationship between PTEN and PI3K.

Previous studies on renal (30) and ovarian (31,32) ischemia reperfusion declared that TNF- α and p53 mRNA expression levels were found to be the highest in the I/R group. Similarly, in accordance with our results, TNF- α and p53 mRNA expression values were the highest in the I/R group. We considered that I/R looked like more harmful than ischemia on tissue, and *H. perforatum* reduced the level of its damage. We also considered that *H. perforatum* suppressed the TNF- α and p53 expression and also inflammation in the ovary.

Conclusions

The result of the present study showed that *H. perforatum* decreased the degeneration in the tissue, increased CAT and GSH levels, and also had an effect in decreasing TNF- α

and p53 mRNA expressions levels in the I/R groups. We suggest that *H. perforatum* can be considered as an agent to protect against tissue damage during ischemia reperfusion, but it is important that *H. perforatum* should be investigated in detail, may be in terms of its adverse effect, so further research and clinical practice on *H. perforatum* are necessary.

Limitations of the study

Despite revealing the healing effects of *H. perforatum* on ischemia and I/R, the study has several limitations. The most significant limitation is the lack of adequate laboratory resources to isolate and identify all the molecules of *H. perforatum*, which would allow us to determine the specific molecule or molecules that play a key role during ischemia and I/R. Identifying these key molecules could lead to more precise results. Additionally, the study is limited by the use of a small number of subjects in animal model studies due to ethical regulations governing animal experimentation. Furthermore, the project's insufficient budget prevented the comprehensive analysis of all the molecules investigated in the study, both through PCR and immunohistochemistry.

Directions for Future Research

In this study, we investigated the effects of *H. perforatum* during ischemia and I/R in the ovaries of animal models, but it is essential to conduct similar studies in human models. This is a crucial step for advancing research and clinical practice involving *H. perforatum*. Furthermore, while it is important to examine the potential adverse effects of *H. perforatum*, an even more significant reason for future research with *H. perforatum* is to isolate and study its individual molecules to identify the key molecule or molecules involved in its effects, and then conduct further research with these isolated molecules.

Authors' Contribution

Conceptualization: Seyit Ali Bingöl, Serdar Yiğit, Ergin Taşkın, Hasan Çilgin.

Data curation: Serdar Yiğit, Ergin Taşkın, Muhammed Yayla, Nilnur Eyerici, Fatma Necmiye Kacı, Nurcan Kılıç Baygutalp.

Formal analysis: Ergin Taşkın, Nilnur Eyerici, Fatma Necmiye Kacı, Nurcan Kılıç Baygutalp.

Funding acquisition: Seyit Ali Bingöl, Serdar Yiğit.

Investigation: Seyit Ali Bingöl, Serdar Yiğit, Ergin Taşkın, Muhammed Yayla, Nilnur Eyerici, Fatma Necmiye Kacı, Nurcan Kılıç Baygutalp, Erdem Toktay, Hasan Çilgin.

Methodology: Serdar Yiğit, Muhammed Yayla, Erdem Toktay.

Project administration: Seyit Ali Bingöl, Serdar Yiğit.

Supervision: Seyit Ali Bingöl, Serdar Yiğit.

Visualization: Serdar Yiğit.

Writing—original draft: Seyit Ali Bingöl, Serdar Yiğit.

Writing—review & editing: Seyit Ali Bingöl, Serdar Yiğit.

Conflict of Interests

The authors declare no conflict of interest.

Ethical Issues

The study was carried out in the Experimental Animal Application and Research Center after the approval of Kafkas University Experimental Animal Ethics Committee (KAU/HADYK 2021-148).

Financial Support

This research was funded by Kafkas University Scientific Research Projects Commission, the project number KAU BAP-2020-TS-05.

References

- Saddiqe Z, Naem I, Maimoona A. A review of the antibacterial activity of *Hypericum perforatum* L. J Ethnopharmacol. 2010; 131:511-21. doi:10.1016/j.jep.2010.07.034
- Tanideh N, Ghafari V, Ebrahimi R, Habibagahi R, Koochi-Hosseiniabadi O, Iraj A. Effects of *Calendula Officinalis* and *Hypericum perforatum* on Antioxidant, Anti-Inflammatory, and Histopathology Indices of Induced Periodontitis in Male Rats. J Dent (Shiraz). 2020;21:314-21. doi:10.30476/DENTJODS.2020.83660.1056
- Altan A, Aras MH, Damlar I, Gokce H, Ozcan O, Alpaslan C. The effect of *Hypericum perforatum* on wound healing of oral mucosa in diabetic rats. Eur Oral Res. 2018;52:143-9. doi:10.26650/eor.2018.505
- Nobakht SZ, Akaberi M, Mohammadpour AH, Tafazoli Moghadam A, Emami SA. *Hypericum perforatum*: Traditional uses, clinical trials, and drug interactions. Iran J Basic Med Sci. 2022;25:1045-58. doi:10.22038/IJBMS.2022.65112.14338
- Wattar B, Rimmer M, Rogozinska E, Macmillian M, Khan KS, Al Wattar BH. Accuracy of imaging modalities for adnexal torsion: a systematic review and meta-analysis. BJOG. 2021;128:37-44. doi:10.1111/1471-0528.16371
- Lagana AS, Sofo V, Salmeri FM, Palmara VI, Triolo O, Terzic MM, et al. Oxidative Stress during Ovarian Torsion in Pediatric and Adolescent Patients: Changing The Perspective of The Disease. Int J Fertil Steril. 2016;9:416-23. doi:10.22074/ijfs.2015.4598
- Lawvere S, Mahoney MC. St. John's wort. Am Fam Physician. 2005;72:2249-54.
- Butterweck V. Mechanism of action of St John's wort in depression: what is known? CNS Drugs. 2003;17:539-62. doi:10.2165/00023210-200317080-00001
- Wills RB, Bone K, Morgan M. Herbal products: active constituents, modes of action and quality control. Nutr Res Rev. 2000;13:47-77. doi:10.1079/095442200108729007
- Mestrovic J, Pogorelic Z, Drmic-Hofman I, Vilovic K, Todoric D, Popovic M. Protective effect of urapidil on testicular torsion-detorsion injury in rats. Surg Today. 2017;47:393-8. doi:10.1007/s00595-016-1388-3
- Guler MC, Tanyeli A, Erdogan DG, Eraslan E, Comakli S, Polat E, et al. Urapidil alleviates ovarian torsion detorsion injury via regulating oxidative stress, apoptosis, autophagia, and inflammation. Iran J Basic Med Sci. 2021;24:935-42. doi:10.22038/ijbms.2021.57196.12736
- Simon HU, Haj-Yehia A, Levi-Schaffer F. Role of reactive oxygen species (ROS) in apoptosis induction. Apoptosis. 2000;5:415-8. doi:10.1023/a:1009616228304
- Sapmaz-Metin M, Topcu-Tarlacalisir Y, Uz YH, Inan M, Omurlu IK, Cerkezayabekir A, et al. Vitamin E modulates apoptosis and c-jun N-terminal kinase activation in ovarian torsion-detorsion injury. Exp Mol Pathol. 2013;95:213-9. doi:10.1016/j.yexmp.2013.07.007
- Hassan B, Akcakanat A, Holder AM, Meric-Bernstam F. Targeting the PI3-kinase/Akt/mTOR signaling pathway. Surg Oncol Clin N Am. 2013;22:641-64. doi:10.1016/j.soc.2013.06.008
- Trotman LC, Pandolfi PP. PTEN and p53: who will get the upper hand? Cancer Cell. 2003;3:97-9. doi:10.1016/s1535-6108(03)00022-9
- Afolabi O, Alabi B, Omobowale T, Oluranti O, Iwalewa O. Cysteamine mitigates torsion/detorsion-induced reperfusion injury via inhibition of apoptosis, oxidative stress and inflammatory responses in experimental rat model. Andrologia. 2022;54: e14243. doi:10.1111/and.14243
- Shu SY, Ju G, Fan LZ. The glucose oxidase-DAB-nickel method in peroxidase histochemistry of the nervous system. Neurosci Lett. 1988;85:169-71. doi:10.1016/0304-3940(88)90346-1
- Sun Y, Oberley LW, Li Y. A simple method for clinical assay of superoxide dismutase. Clin Chem. 1988;34:497-500. doi:10.1093/clinchem/34.3.497
- Aebi H. Catalase in vitro. Methods Enzymol 1984;105:121-6. doi:10.1016/s0076-6879(84)05016-3
- Ural DA, Aykal DA, Koçarslan S, Doğaner A. Effect of tadalafil

- treatment on ovarian ischemia injury in rats. *Cukurova Medical Journal*. 2021;46:55-62. doi:10.17826/cumj.784468
21. Kalogeris T, Baines CP, Krenz M, Korthis RJ. Cell biology of ischemia/reperfusion injury. *Int Rev Cell Mol Biol*. 2012;298:229-317. doi:10.1016/B978-0-12-394309-5.00006-7
 22. Balasubramaniam D, Duraisamy KY, Ezhilmani M. Laparoscopic Detorsion and Fertility Preservation in Twisted Ischemic Adnexa - A Single-Center Prospective Study. *Gynecol Minim Invasive Ther*. 2020;9:24-8. doi:10.4103/GMIT.GMIT_20_19
 23. Asir F, Ozgokce C. Momordica charantia reduced ovarian ischemia - reperfusion injury by suppressing APAF-1 expression. *Eur Rev Med Pharmacol Sci*. 2023;27:2182-8. doi:10.26355/eurrev_202303_31751
 24. Kirmizi DA, Baser E, Okan A, Kara M, Yalvac ES, Doganyigit Z. The effect of a natural molecule in ovary ischemia reperfusion damage: does lycopene protect ovary? *Exp Anim*. 2021;70:37-44. doi:10.1538/expanim.20-0080.
 25. Nasr SE, Elgendy MS, Sayed SS, Aly AM. Histological study on the effect of vitamin C on ischemia-reperfusion injury in the adult rat ovary. *Egyptian Journal of Histology*. 2014;37:562-70. doi:10.1097/01.EHX.0000452614.96818.85
 26. İsgüder ÇK, Uysal M, Can ÖK, Pektaş MK, Arici A, Unsal V. Protective effects of apocynin and melatonin on ovarian ischemia/reperfusion injury in rats. *CEOG*. 2021;48:98-104. doi:10.31083/j.ceog.2021.01.5488.
 27. Abdel-Hamid HA, Maqsood NMA, Toni ND, Ahmed RF, Abdel-Hakeem EA. Leptin alleviated ovarian ischemia-reperfusion injury in rats via modulation of Sirt-1/Nrf2 and TLR4/NF-kB/caspase-3 signaling pathways. *Endocr Regul*. 2023;57:25-36. doi:10.2478/enr-2023-0004
 28. Zhang J, Jiang H, Liu DH, Wang GN. Effects of dexmedetomidine on myocardial ischemia-reperfusion injury through PI3K-Akt-mTOR signaling pathway. *Eur Rev Med Pharmacol Sci*. 2019;23:6736-43. doi:10.26355/eurrev_201908_18565
 29. He W, Duan L, Zhang L. LOXL1-AS1 Aggravates Myocardial Ischemia/Reperfusion Injury Through the miR-761/PTEN Axis. *Korean Circ J*. 2023;53:387-403. doi:10.4070/kcj.2022.0301
 30. Zou G, Zhou Z, Xi X, Huang R, Hu H. Pioglitazone Ameliorates Renal Ischemia-Reperfusion Injury via Inhibition of NF-kappaB Activation and Inflammation in Rats. *Front Physiol*. 2021;12:707344. doi:10.3389/fphys.2021.707344
 31. Refaie MMM, El-Hussieny M. Protective effect of pioglitazone on ovarian ischemia reperfusion injury of female rats via modulation of peroxisome proliferator activated receptor gamma and heme-oxygenase 1. *Int Immunopharmacol*. 2018;62:7-14. doi:10.1016/j.intimp.2018.06.037
 32. Jafari Shobeiri M, Hajagaei Saeidi N, Esmaeili HA, et al. Comparison of clinico-pathological features between epithelial ovarian cancer patients with and without endometriosis: a cross-sectional study. *Crescent Journal of Medical and Biological Sciences*. 2024;11(1):38-42.

Copyright © 2024 The Author(s); This is an open-access article distributed under the terms of the Creative Commons Attribution License (<http://creativecommons.org/licenses/by/4.0>), which permits unrestricted use, distribution, and reproduction in any medium, provided the original work is properly cited.