



# The Effect of Fibroblast Growth Factor and Cold Atmospheric Plasma Treatment on Calcaneus Tendon Healing Activity in Rabbits

Alireza Omranifard<sup>1</sup>, Alireza Jahandideh<sup>1\*</sup>, Ahmad Asghari<sup>1</sup>, Saeed Hesaraki<sup>2</sup>

## Abstract

**Objectives:** Tendon recovery after a surgical operation or traumatic injury is still one of the challenges of rehabilitation. Many recently formulated treatments have been designed to improve these procedures. This study aimed to evaluate the effects of recombinant basic fibroblast growth factor (bFGF) and cold atmospheric plasma (CAP) on calcaneus tendon healing and regeneration in rabbit models.

**Material and Methods:** This study subdivided 40 mature male New Zealand white rabbits into four groups (n=10 in each). The defect was made under general conditions, and the wound was closed without treatment. The experimental groups included sham (without treatment), bFGF (operated bFGF in the injured area), CAP (used CAP in the injured area), and bFGF/CAP (used both CAP and bFGF) in the injured area. This study used trichrome and reticulin stains to evaluate collagen production and other tissue factors. Also, hydroxyproline levels were measured for better observation of collagen synthesis. Pathological evaluation of the defective tendon was performed on days 60 and 120 after surgery.

**Results:** The improvement of new and parallel tendon formation was the best in the bFGF/CAP group at both times, especially 120 days after surgery. An increase in hydroxyproline levels was also seen on the sampling days.

**Conclusions:** The experiment showed that bFGF/CAP combination significantly improved tendon remodeling in the injured areas.

**Keywords:** Fibroblast growth factor, Cold atmospheric plasma, Hydroxyproline, Collagen, Reticulin, Histopathology, Tendon healing

## Introduction

Local inflammation, excessive or insufficient loading, and aging are the leading causes of tendon harm (1). Tendon repair is typically slow because of the low turnover, nerve fibers, and blood supply. A tendon injury could lead to rupture, pain, limited motion, granulation tissue, scar, and recumbence (2). Healing is a complex process including overlapping and synchronized multicellular phases of angiogenesis, inflammation, migration, granulation, proliferation, re-epithelialization, tissue formation, matrix formation, and remodeling (3). Fibroblast growth factors (FGFs) are polypeptide growth factors that are abundantly produced in both developing and mature tissues. They can interact with particular receptors on cell membranes to mediate several pathophysiological and biological processes, such as mitogenesis, cellular differentiation, metabolic control, cell migration, angiogenesis, and tissue injury repair (4). Administration of basic fibroblast growth factor (bFGF) at the tendon healing site enhances the healing process by enhancement of collagen fiber alignment and increasing biomechanical resistance (5).

The term “plasma” refers to an ionized neutral gas composed primarily of ions, free electrons, photons, and

atoms that are either stable or wrathful by a neutral net (6). bFGF is a 146-amino acid single-chain polypeptide and a member of the heparin-binding growth factor family. It has been proven that bFGF stimulates cell migration and proliferation. At various time points following the addition of varying quantities of bFGF, the progression of in vitro wound closure was observed, which accelerated the rate of wound healing (7). Cold atmospheric plasma (CAP) is an ionized gas at room temperature that appears to be a practicable route to improving tissue healing. The atmospheric pressure argon plasma (jet plasma) operates on argon gas to produce thermal plasma energy for a field of tissue adjacent to the probe. The argon plasma treatment can increase the absorption of protein and adhesion of the murine osteoblasts over hydroxyapatite (8). The jet plasma can induce the regression of cancer cells in vitro and in vivo. The 10-second application of plasma can cause apoptosis, while over-10-second use can cause necrosis in pancreatic cancer cells (9). Previous studies have presented evidence that plasma jet helps wound healing due to its useful modulation of inflammation and cell activation (9, 10). An in vivo investigation on wound healing development under atmospheric pressure

Received 9 August 2022, Accepted 9 January 2023, Available online 1 January 2024

<sup>1</sup>Department of Clinical Science, Science and Research Branch, Islamic Azad University, Tehran, Iran. <sup>2</sup>Department of Pathobiology, Science and Research Branch, Islamic Azad University, Tehran, Iran.

\*Corresponding Author: Alireza Jahandideh, Email: dr.jahandideh@gmail.com



## Key Messages

- ▶ Recombinant bFGF and CAP possess diverse biological capabilities that include Improving cellular activity and anti-inflammatory properties.
- ▶ This experiment showed that FGFb/CAP combination significantly improves tendon regeneration in damaged areas.

plasma jet revealed that cold plasma could improve wound regeneration. Significant epithelialization was observed 3-9 days after surgery, compared to controls. In the same study, cold plasma could activate keratinocyte and fibroblast migration and accelerate the closure of the wound surface. Their results revealed the benefits of cold plasma in completing current wound therapies (11).

Studies using cold plasma irradiation on the skin to heal damaged tendon tissue found that treatment at 10 kV helped heal the internal injury. However, treatment at 5 kV did not affect the injury (12). Osteoblasts have the potency to differentiate from human bone marrow mesenchymal stem cells (MSCs). The atmospheric plasma treatment can induce direct osteogenesis due to a favorable surface for cell proliferation, conduction, and differentiation. Bone healing in the defect could be accelerated using a scaffold such as hydroxyapatite or chitosan in addition to the atmospheric plasma (13). Some types of CAP have been invented for therapy purposes. Electrical and thermal energies are needed to create and support plasma. Usually, the required discharge to produce CAP is generated electrically. Various methods to make CAP include atmospheric pressure plasma jet, plasma needle, plasma pencil, and dielectric barrier discharge (DBD) (14). FGF, a mediator released by leukocytes, is necessary to start and continue the healing processes of injured tendons, especially by promoting fibroblast proliferation by inducing the growth and proliferation of all types of cells, especially fibroblasts. bFGF can cause them to increase and produce collagen, leading to better repair of damaged tissue (15). Increased bFGF expression implies improvements in Achilles tendon rupture, slight pain, flexibility, and physical ability. Then bFGF is a marker to evaluate proper tendon healing (16). Also, increasing the reticulin fibers (collagen III) implies more tendon strength (17).

This study aimed to speed up the healing process of an experimentally damaged tendon using the bFGF, the benefits of which were mentioned, along with the limited use of atmospheric radiation. In this research, the combination of bFGF with cold plasma rays resulted in faster tendon repair than either treatment alone.

## Material and Methods

### In Vivo Study

The study included 40 mature male New Zealand white rabbits aged 6–8 months, weighing 2.5-3 kg, and randomly

allocated into four research groups. Thus, there were 20 study time points per group (each group consisted of five animals) on days 60 and 120. Rabbits were obtained from the Department of Reproduction and Maintenance of Laboratory Animals (Pasteur Institute of Iran) and kept in special cages. Rabbits were not experimented on for two weeks to prevent stress and allow the animals to adjust to the environment. All animals were kept under the same environmental and nutritional conditions (temperature, humidity, light, type of food ration, and the number of feeding times). They were kept in a room with a constant temperature of  $22 \pm 1^\circ\text{C}$ , a relative humidity of  $40 \pm 1\%$ , and a 12-hour light/dark cycle. Rabbits were fed using pellets specially prepared for laboratory animals, and water was freely available to the animals. The protocol of this study was carried out according to the ethical principles approved by the international committees to protect the rights of laboratory animals. Animals were kept under food restriction conditions for 6 hours before surgery.

### Experimental Protocol

The experimental group included a control: a defect undergoing surgery with the administration of 0.25 mL of distilled water under and above the injury site. FGF: In the second group, 50  $\mu\text{g}$  of human recombinant FGF (HumanKine<sup>®</sup>, Sigma Aldrich, purchased from Safir Azma, Purchase code: 68036787) was dissolved in 0.5 ml of distilled water and injected above and below the calcaneal tendon lesion immediately after surgery. CAP: In the third group, after the injury to the calcaneal tendon, CAP with a voltage of 10 kV and a frequency of 10 kHz was irradiated on the injury site for 30 seconds every day for 21 consecutive days. FGF/CAP: In the fourth group, rabbits were treated with CAP irradiation (as in the third group) and simultaneous injection of FGF solution (as in the second group).

### Surgery Procedure

All animals were anesthetized with an intramuscular injection of 3 mg/kg xylazine and 30 mg/kg ketamine hydrochloride. Each animal's right hind leg was chosen for surgery. The skin over the common calcaneal tendon (CCT) was shaved and disinfected by Lugol's iodine in a surgically aseptic manner. We incised the skin 0.5 cm over the calcaneal tuberosity and 0.5 cm distal to the gastrocnemius muscle. After dissection, the CCT was exposed. After paratenon detection, a 1.5-cm incision was made in the middle of the tendon longitudinally. The incision was distal to the gastrocnemius muscle. Then we covered the operating area with the overlying fascia. The skin was sutured in four knots in a simple pattern for all animals. After surgery, we checked daily to prevent infection or hemorrhagic conditions (18).

### Sample Preparation

Twenty rabbits were euthanized with EUTHASOL (400

mg/mL) at each time point at days 60 and 120 post-surgery. Following the removal of the injured area, a histological workup was initiated. For seven days, the damaged tendon segment was fixed in a buffered 10% formalin solution.

### Histopathology and Staining Procedures

The histopathology evaluation was based on a scoring system to evaluate the inflammatory tissue response and regular connective tissue formation and integration. The following treatments were studied to determine their effectiveness: fiber thickness, regular fiber arrangement, reticular fiber development, inflammation, vascularization, cellularity, and round nuclei are all graded as 0 (0%): non, 1 (less than 25%): mild, 2(25%-50%): moderate, and 3(50%-75%): severe (19, 20).

The sections were stained with the trichrome and reticulon stains to evaluate collagen types I and III production, respectively. The sections were deparaffinized with xylene and alcohol and then diluted with water. The sections were oxidized in acidified potassium permanganate for 3 minutes and rinsed in distilled water. The sections were decolorized with 2% oxalic acid for 1 minute, followed by a rinse in distilled water. After that, the sections were mordanted in 4% iron alum for 10 minutes and rinsed in distilled water. The sections were impregnated in an ammoniacal silver solution for 11 seconds before being quickly rinsed in distilled water. Immediately, they were reduced with 10% aqueous formalin for 2 minutes and washed in running tap water for 2 minutes. The sections were toned in 0.2% gold chloride for 2 minutes and rinsed in distilled water. Also, the sections were fixed with 2% aqueous sodium thiosulfate (hypo) for 2 minutes and washed in water for 2 minutes. They were counterstained

with neutral red for 2 minutes and then dehydrated, cleared, and mounted. Tendon samples were studied with a microscope (Optica-B-500Bi). Thereby, we compared FGF+CAP and FGF, CAP, and Sham (the control group).

### Assay for Hydroxyproline

Tendon samples were hydrolyzed in 6N hydrochloric acid and Chloramine T (a hydroxyproline oxidizer) for 18 hours at 110°C. Then a chromophore was formed when adding Ehrlich's reagent at 60°C. A spectrophotometer (ELx800 absorbance) is used to measure the absorbance of hydrolyzed samples. The amount of hydroxyproline was compared with a standard curve. Data were represented as µg/g of tendon tissue.

### Statistical Analysis

A two-way ANOVA and Dunnett post hoc test were used for statistical analysis via the GraphPad Prism 9.0 software. The data was semi-quantitative. Based on histopathology, the inter-individual consequences would be significant if the p-values were less than 0.05 ( $P \leq 0.05$ ), less than 0.01 ( $P \leq 0.01$ ), less than 0.001 ( $P \leq 0.001$ ), and less than 0.0001 ( $P \leq 0.0001$ ), and ns=Not significant. Finally, the data were presented as means and standard deviations.

## Results

### Histopathology

#### Day 60 Post-injury

The injured region of sham groups was moderately hypercellular and inflamed; also, the pattern of cells and collagen fibers was severely haphazard. The proliferating tenoblasts signed pale, large vesicular nuclei. Numerous capillaries were evident in the lesions in this group. The

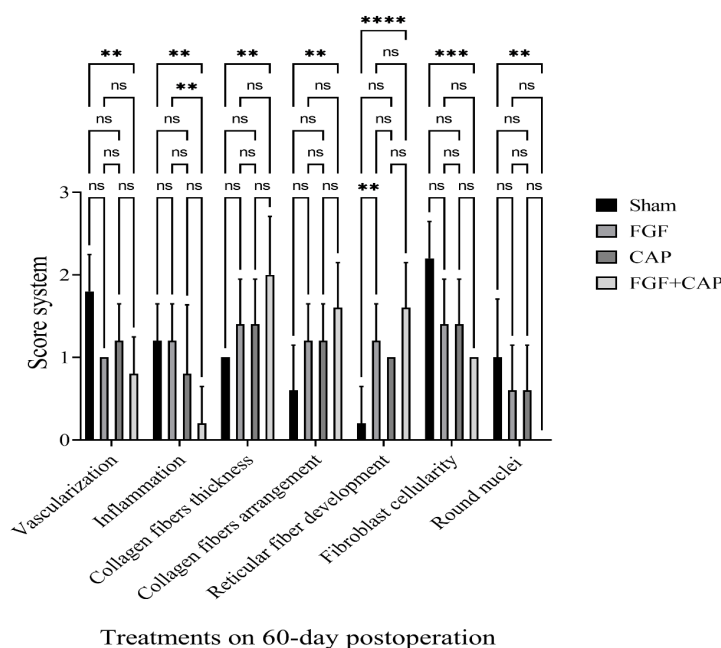


Figure 1. Histological Scoring of the Experimental Groups at 60 Days After Surgery. \*  $P=0.03$ , \*\*  $P=0.002$ , \*\*\*  $P=0.0002$ , \*\*\*\*  $P=0.0001$ , ns= Not significant



sham group showed the least improvement (Figure 1 and Figures 2a and 2e). In contrast, the inflammation and cellularity of the injured area in the FGF+CAP group were the least ( $P \leq 0.01$ ). The rate of collagen thickness, regularity, and reticular fibers were at the best recovery level ( $P \leq 0.001$ ), and the FGF+CAP group gained the highest score (Figure 1 and Figures 2d and 2h). In both FGF (Figure 1 and Figures 2b and 2f) and CAP (Figure 1 and Figures 2c and 2g) groups, their appearance was not as significant as in the latter group. The nuclei of this group were not round, which means the differentiation and maturation of the fibroblasts ( $P \leq 0.05$ ) (Figures 1 and 2).

**Day 120 Post-injury**

The operated area in the FGF+CAP group showed more alignment of fibers, mature tenocytes, and collagen fibers than the control and CAP groups ( $P \leq 0.0001$ ). The decrease of vessels and cells in the lesions was the most improved in the FGF+CAP group ( $P \leq 0.01$ ) (Figure 3 and Figures 4d and 4h). The mature tenocytes of the injured area were significantly higher on day 120 compared to day 60. The round nuclei factor of the FGF+CAP group was at least ( $P \leq 0.05$ ), also vascularization and inflammation were at the lowest level, which showed improvement of the defected tendon (Figure 3 and Figures 4d and 4h). In both FGF (Figure 3 and Figures 4b and 4f) and CAP (Figure 3 and Figures 4c and 4g) groups, their appearance was not significant in inflammation, collagen fiber thickness, arrangement and cellular shape but gained better results than Sham group (Figures 4a and 4e).

**Amount for Hydroxyproline**

**Day 60 Post-injury**

The group FGF+CAP showed the highest induction of hydroxyproline production on this day (68.068  $\mu\text{g/g}$ ) ( $P \leq 0.0001$ ). The CAP (mean 66.92  $\mu\text{g/g}$ ) and FGF (66.18

$\mu\text{g/g}$ ) groups alone showed no significant differences in hydroxyproline production between them but showed significant differences with the sham group (50.52  $\mu\text{g/g}$ ), ( $P \leq 0.0001$ ) (Figure 5).

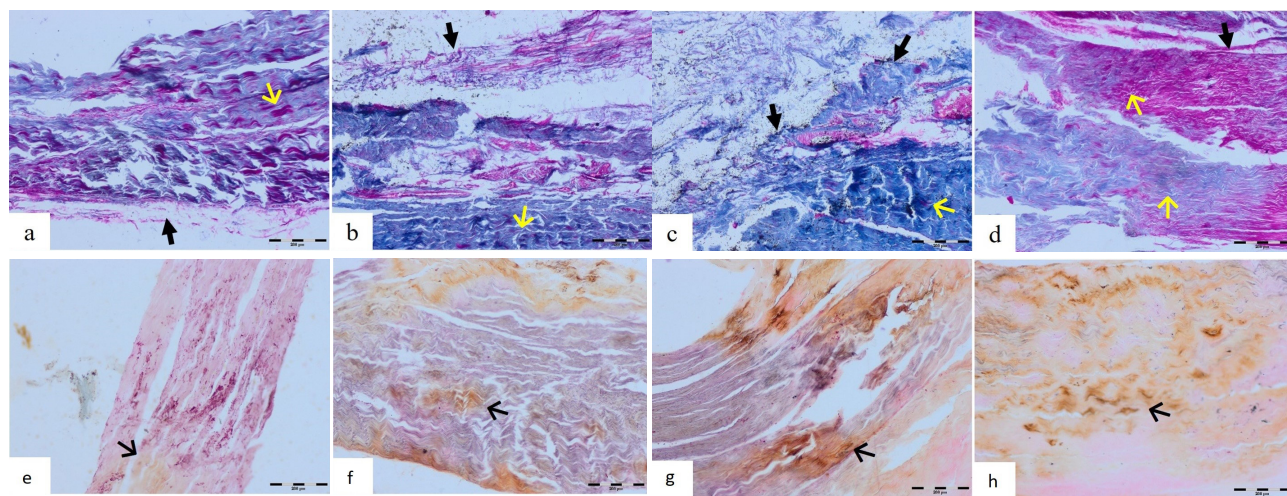
**Day 120 Post-injury**

The amount of hydroxyproline on this day had the highest significance in the group FGF+CAP (87.34  $\mu\text{g/g}$ ), ( $P \leq 0.0001$ ). The CAP (85.68  $\mu\text{g/g}$ ), and FGF (84.72  $\mu\text{g/g}$ ), groups showed significant differences in hydroxyproline rate of production ( $P \leq 0.001$ ) with the sham group (62.02  $\mu\text{g/g}$ ) ( $P \leq 0.0001$ ). (Figure 5).

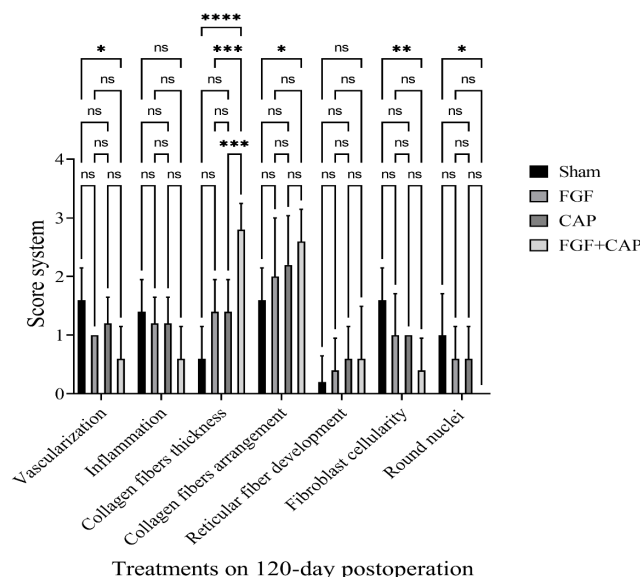
**Discussion**

The extracellular matrix (ECM) of the tendons is produced by tenocytes. The main fibril components of the ECM in the tendon are composed predominantly of collagen types I, III, and V and elastin fibrils. The parallel arrangement of collagen fibers in tendons results in strange tendon stiffness and tensile potency (21). Tendon injuries are common in animals with high levels of exercise and can be very challenging to treat (22). Therapies with clinical applications such as ultrasound, low-power laser, cold plasma, magnetic field, electrical stimulation, injection of platelet-rich plasma, and even implantation of cultured cells have shown significant effects in different conditions (23). More expression of the FGF implies more improvement in Achilles tendon rupture, slight pain, more flexibility, and more physical ability. Then FGF is a marker to evaluate proper tendon healing (16).

In our study, on day 60, the FGF and CAP in the treatment groups reduced the cellularity of the immature fibroblasts, angioblasts, new small blood vessels, and inflammatory cells. These reductions were the greatest when both were used. In contrast, the rate of collagen



**Figure 2.** Histological Evaluations With Masson's Trichrome Staining 60 Days After Surgery. a, b, c and d represented sham, FGF, CAP, and FGF+CAP groups, respectively (100 $\times$ ). The most collagen production is in the FGF+CAP group. Yellow arrow: Collagen synthesis; Black arrow: Epitendineum. Scale bar: 200 $\mu$ . Histological evaluations with Reticulin staining at 60 days after surgery. e, f, g, and h represented sham, FGF, CAP, and FGF+CAP groups, respectively (100 $\times$ ). The most reticulin production is in the FGF+CAP group. Arrow: Reticulin synthesis. Scale bar: 200 $\mu$ .



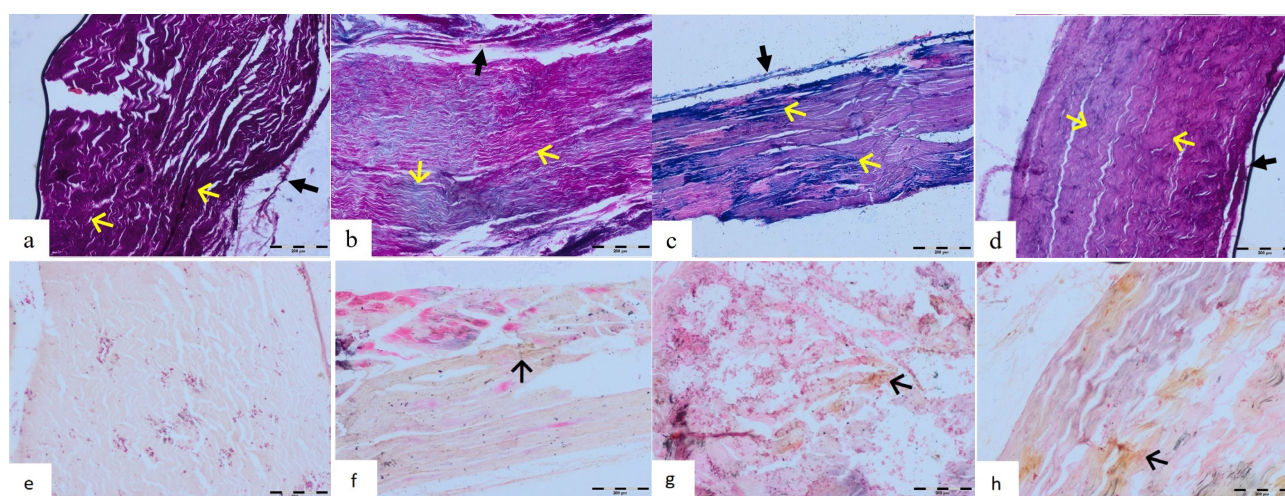
**Figure 3.** Histological scoring of the experimental groups at 120 days after surgery. \*  $P=0.03$ , \*\*  $P=0.002$ , \*\*\*  $P=0.0002$ , \*\*\*\*  $P=0.0001$ , ns= Not significant

density was increased compared to the sham group. This increase was the greatest in the FGF+CAP group. On day 120, the cellularity, consisting of fibroblasts, leukocytes, and new small blood vessels, decreased significantly in all the FGF and CAP-received groups compared to the sham. At this stage, those tendons treated with FGF+CAP had fewer fibroblasts, leukocytes, and new small blood vessels. When compared to the other groups, they had significantly more mature fibrocytes and collagen density. CAP could be used to treat injuries and play a role in healing humans and animals.

Researchers have found that CAP can stimulate fibroblast proliferation (24,25). Jet plasma treatment could induce the expression of the pro-inflammatory cytokines, PCNA, and Ki67 (proliferation markers). It also improves

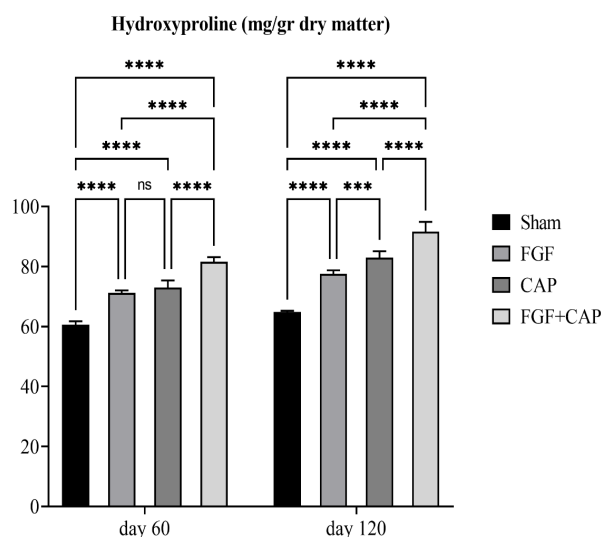
the synthesis of the metalloproteinase matrix and collagen type 1. However, it can decrease the expression of Apaf1 and p53 (apoptotic markers). Then, jet plasma treatment can increase cell viability and proliferation and improve the inflammatory process (10). In 2013, Arndt et al showed that a two-minute treatment with CAP could increase the production of cytokines, growth factors, and skin fibroblast proliferation. This treatment also did not affect the apoptotic process. CAP therapy also induces fibroblast migration, acceleration, and synthesis of type I collagen and alpha-smooth muscle actin, which affect the repair process (26).

In 2018, Arndt et al showed that endothelial cells are more sensitive to CAP, while keratinocytes and fibroblasts are much less sensitive. They also showed that



**Figure 4.** Histological Evaluations with Masson's Trichrome Staining 120 Days After Surgery. a, b, c, and d represented sham, FGF, CAP, and FGF+CAP groups, respectively (100x). The most regularity of collagen production is in the FGF+CAP group. Yellow arrow: collagen synthesis; Black arrow: Epitendineum. Scale bar: 200µ. Histological evaluations with reticulin staining 120 days after surgery. e, f, g, and h represented sham, FGF, CAP, and FGF+CAP groups, respectively (100x). The most reticulin production is in the FGF+CAP group. Arrow: reticulin synthesis. Scale bar: 200µ.





**Figure 5.** Hydroxyproline Scoring of the Experimental Groups 60 and 120 Days After Surgery. \*  $P=0.03$ , \*\*  $P=0.002$ , \*\*\*  $P=0.0002$ , \*\*\*\*  $P=0.0001$ , ns= Not significant.

this treatment induces the production of angiogenesis-related molecules not only in endothelial cells but also in keratinocytes and fibroblasts. It induces tubular formation by endothelial cells (27). In this study, all treatment groups had significantly lower vascularization than the sham, which could be attributed to a long time since surgery in the 60- and 120-day post-surgery periods. The treatment plans should not only be based on new blood vessel development. The ratio of reticulin to collagen fibers is more noticeable in tendon healing. More reticulin fiber expression indicates greater tendon strength. This fiber was detected by using a reticulin stain. With the passage of time, reticulin fiber production replaces collagen production, which excludes reticulin fibers (28,29).

A study reported that on day 30, after surgery, only fine reticulin fibers produced by fibroblasts could be detected by silver stain (30). Therefore, on days 60 and 120 after surgery, the number of reticulin fibers was not as large as that of collagen fibers. This study showed that the rate of reticulin production was the highest in the FGF+CAP group only at day 60. Hydroxyproline amount determination is an index for the evaluation of collagen production in connective tissues. The improving effects of the FGF+CAP in the injury area of the tendon can be determined by the increased hydroxyproline content in tendon tissues. The hydroxyproline content is correlated with collagen production in early tendon healing. The coadministration of bFGF and CAP to treat tendon injuries has not been reported to date.

In this study, we identified a considerable effect of CAP in combination with bFGF in rabbit models with a calcaneal tendon injury. This complex administration significantly decreases the inflammatory response and promotes cell division and collagen synthesis more than that alone.

### Authors' Contribution

**Conceptualization:** Alireza Jahandideh.

**Data curation:** Ahmad Asghari.

**Formal analysis:** Alireza Omranifard; Saeed Hesaraki.

**Funding acquisition:** Alireza Omranifard.

**Investigation:** Alireza Omranifard; Alireza Jahandideh; Saeed Hesaraki.

**Methodology:** Alireza Jahandideh.

**Project administration:** Alireza Jahandideh.

**Resources:** Alireza Omranifard.

**Supervision:** Alireza Jahandideh.

**Validation:** Alireza Omranifard; Saeed Hesaraki.

**Visualization:** Alireza Omranifard; Saeed Hesaraki.

**Writing—original draft:** Alireza Omranifard; Saeed Hesaraki.

**Writing—review & editing:** Alireza Jahandideh; Ahmad Asghari.

### Conflict of Interests

The authors have no conflict of interest.

### Ethical Issues

This study was conducted on animals with the permission of the ethics committee of Islamic Azad University, Science and Research Branch, Tehran (IR.IAU.SRB.REC.1398.376).

### Financial Support

None.

### References

- Merza E, Pearson S, Lichtwark G, Ollason M, Malliaras P. Immediate and long-term effects of mechanical loading on Achilles tendon volume: a systematic review and meta-analysis. *J Biomech.* 2021;118:110289. doi:10.1016/j.jbiomech.2021.110289
- Riley G. Tendinopathy—from basic science to treatment. *Nat Clin Pract Rheumatol.* 2008;4(2):82-89. doi:10.1038/ncprheum0700
- Hassanpour Khodaei S, Roshangar L, Sebetkam S, Soleimani Rad J. The effect of mummy substance on matrix protein synthesis by human adipose-derived stem cells and dermal fibroblast and their behavior on plated PCL scaffold. *Crescent J Med Biol Sci.* 2021;8(3):198-204.
- Seiwert S, Rucman R, Turkovic B, et al. BPC 157 and standard angiogenic growth factors. Gastrointestinal tract healing, lessons from tendon, ligament, muscle and bone healing. *Curr Pharm Des.* 2018;24(18):1972-1989. doi:10.2174/1381612824666180712110447
- Poorpezeshk N, Ghoreishi SK, Bayat M, Pouriran R, Yavari M. Early low-level laser therapy improves the passive range of motion and decreases pain in patients with flexor tendon injury. *Photomed Laser Surg.* 2018;36(10):530-535. doi:10.1089/pho.2018.4458
- Reyna Martínez R, Narro Céspedes RI, Ibarra Alonso MC, Reyes Acosta YK. Use of cold plasma technology in biomaterials and their potential utilization in controlled administration of active substances. *Juniper Online J Mater Sci.* 2018;4(5):555649. doi:10.19080/jojms.2018.04.555649
- Molloy T, Wang Y, Murrell G. The roles of growth factors in tendon and ligament healing. *Sports Med.* 2003;33(5):381-394. doi:10.2165/00007256-200333050-00004
- Canullo L, Peñarrocha D, Clementini M, Iannello G, Micarelli C. Impact of plasma of argon cleaning treatment on implant abutments in patients with a history of periodontal disease and thin biotype: radiographic results at 24-month follow-up of a RCT. *Clin Oral Implants Res.* 2015;26(1):8-14. doi:10.1111/clr.12290
- Partecke LI, Evert K, Haugk J, et al. Tissue tolerable plasma

- (TTP) induces apoptosis in pancreatic cancer cells in vitro and in vivo. *BMC Cancer*. 2012;12:473. doi:10.1186/1471-2407-12-473
10. Kleineidam B, Nokhbehsaim M, Deschner J, Wahl G. Effect of cold plasma on periodontal wound healing-an in vitro study. *Clin Oral Investig*. 2019;23(4):1941-1950. doi:10.1007/s00784-018-2643-3
  11. Schmidt A, Bekeschus S, Wende K, Vollmar B, von Woedtke T. A cold plasma jet accelerates wound healing in a murine model of full-thickness skin wounds. *Exp Dermatol*. 2017;26(2):156-162. doi:10.1111/exd.13156
  12. Amini M, Momeni M, Jahandideh A, et al. Tendon repair by plasma jet treatment. *J Diabetes Metab Disord*. 2021;20(1):621-626. doi:10.1007/s40200-021-00789-0
  13. Wang M, Cheng X, Zhu W, Holmes B, Keidar M, Zhang LG. Design of biomimetic and bioactive cold plasma-modified nanostructured scaffolds for enhanced osteogenic differentiation of bone marrow-derived mesenchymal stem cells. *Tissue Eng Part A*. 2014;20(5-6):1060-1071. doi:10.1089/ten.TEA.2013.0235
  14. Hoffmann C, Berganza C, Zhang J. Cold Atmospheric Plasma: methods of production and application in dentistry and oncology. *Med Gas Res*. 2013;3(1):21. doi:10.1186/2045-9912-3-21
  15. Nilsson-Helander K, Thomeé R, Silbernagel KG, et al. The Achilles tendon Total Rupture Score (ATRS): development and validation. *Am J Sports Med*. 2007;35(3):421-426. doi:10.1177/0363546506294856
  16. Chen J, Svensson J, Sundberg CJ, Ahmed AS, Ackermann PW. FGF gene expression in injured tendons as a prognostic biomarker of 1-year patient outcome after Achilles tendon repair. *J Exp Orthop*. 2021;8(1):20. doi:10.1186/s40634-021-00335-0
  17. Lipar M, Zdilar B, Kreszinger M, et al. Extracellular matrix supports healing of transected rabbit Achilles tendon. *Heliyon*. 2018;4(9):e00781. doi:10.1016/j.heliyon.2018.e00781
  18. Oryan A, Moshiri A, Meimandi-Parizi AH. Short and long terms healing of the experimentally transverse sectioned tendon in rabbits. *Sports Med Arthrosc Rehabil Ther Technol*. 2012;4(1):14. doi:10.1186/1758-2555-4-14
  19. Maffulli N, Longo UG, Franceschi F, Rabitti C, Denaro V. Movin and Bonar scores assess the same characteristics of tendon histology. *Clin Orthop Relat Res*. 2008;466(7):1605-1611. doi:10.1007/s11999-008-0261-0
  20. Rosenbaum AJ, Wicker JF, Dines JS, et al. Histologic stages of healing correlate with restoration of tensile strength in a model of experimental tendon repair. *HSS J*. 2010;6(2):164-170. doi:10.1007/s11420-009-9152-5
  21. Lee TH, Kim SE, Lee JY, Kim JG, Park K, Kim HJ. Wrapping of tendon tissues with diclofenac-immobilized polycaprolactone fibrous sheet improves tendon healing in a rabbit model of collagenase-induced Achilles tendinitis. *J Ind Eng Chem*. 2019;73:152-161. doi:10.1016/j.jiec.2019.01.018
  22. Cervi M, Brebner N, Liptak J. Short- and long-term outcomes of primary Achilles tendon repair in cats: 21 cases. *Vet Comp Orthop Traumatol*. 2010;23(5):348-353. doi:10.3415/vcot-09-10-0109
  23. Roche AJ, Calder JD. Achilles tendinopathy: a review of the current concepts of treatment. *Bone Joint J*. 2013;95-B(10):1299-1307. doi:10.1302/0301-620x.95b10.31881
  24. Chatraie M, Torkaman G, Khani M, Salehi H, Shokri B. In vivo study of non-invasive effects of non-thermal plasma in pressure ulcer treatment. *Sci Rep*. 2018;8(1):5621. doi:10.1038/s41598-018-24049-z
  25. Eisenhauer P, Chernets N, Song Y, et al. Chemical modification of extracellular matrix by cold atmospheric plasma-generated reactive species affects chondrogenesis and bone formation. *J Tissue Eng Regen Med*. 2016;10(9):772-782. doi:10.1002/term.2224
  26. Arndt S, Unger P, Wacker E, et al. Cold atmospheric plasma (CAP) changes gene expression of key molecules of the wound healing machinery and improves wound healing in vitro and in vivo. *PLoS One*. 2013;8(11):e79325. doi:10.1371/journal.pone.0079325
  27. Arndt S, Unger P, Berneburg M, Bosserhoff AK, Karrer S. Cold atmospheric plasma (CAP) activates angiogenesis-related molecules in skin keratinocytes, fibroblasts and endothelial cells and improves wound angiogenesis in an autocrine and paracrine mode. *J Dermatol Sci*. 2018;89(2):181-190. doi:10.1016/j.jdermsci.2017.11.008
  28. Yang X, Coleman DP, Pugh ND, Nokes LD. The volume of the neovascularity and its clinical implications in Achilles tendinopathy. *Ultrasound Med Biol*. 2012;38(11):1887-1895. doi:10.1016/j.ultrasmedbio.2012.07.002
  29. Friedrich T, Schmidt W, Jungmichel D, Horn LC, Josten C. Histopathology in rabbit Achilles tendon after operative tenolysis (longitudinal fiber incisions). *Scand J Med Sci Sports*. 2001;11(1):4-8. doi:10.1034/j.1600-0838.2001.011001004.x
  30. Kumar N, Kumar N, Sharma AK, et al. Modulation of peritendinous adhesions using hyaluronic acid and autogenous synovia: an experimental study in a rabbit model. *Trends Biomater Artif Organs*. 2009;23(1):34-45.

**Copyright** © 2024 The Author(s); This is an open-access article distributed under the terms of the Creative Commons Attribution License (<http://creativecommons.org/licenses/by/4.0>), which permits unrestricted use, distribution, and reproduction in any medium, provided the original work is properly cited.