



# Evaluation of Expression of CD44 and Claudin-1 Markers by Immunohistochemically Methods in Differentiation Between Minimal Change Disease and Focal Segmental Glomerulosclerosis

Tala Pourlak<sup>1</sup>, Masumeh Movahhed<sup>1</sup>, Parham Maroufi<sup>2</sup>, Sima Abedi Azar<sup>3</sup>, Mohammad Reza Ardalan<sup>3</sup>, Monireh Halimi<sup>1\*</sup>

## Abstract

**Objectives:** The present study aimed to examine the expression of CD44 and claudin-1 markers using immunohistochemical methods to differentiate patients with minimal change disease (MCD) from those afflicted with focal segmental glomerulosclerosis (FSGS).

**Materials and Methods:** In this descriptive-analytical study, twenty patients with definite FSGS, twenty patients with FSGS/MCD spectrum, and seven patients with definite MCD were randomly chosen from Imam Reza hospital affiliated with Tabriz University of Medical Sciences. All patients underwent renal biopsy, and then the presence of the immune complex was examined in the obtained samples using immunofluorescence staining. Some renal specimens were paraffin-embedded for the evaluation of the expression levels of CD44 and claudin-1 utilizing the immunohistochemistry method.

**Results:** Among the twenty samples obtained from patients with definite FSGS, 13 samples (65%) were double-positive for CD44 and claudin-1, 3 specimens (15%) were positive only for claudin-1, and 4 samples (20%) were double-negative for CD44 and claudin-1. The percentages of renal specimens expressing claudin-1 in patients with definite FSGS, FSGS/MCD, and MCD were 80%, 85%, and 0%, respectively. Finally, the percentages of renal samples expressing CD44 in patients with definite FSGS, FSGS/MCD, and MCD were 65%, 10%, and 0%, respectively.

**Conclusions:** The results of the present research indicated that the rate of CD44-positive specimens was higher in patients with FSGS while the percentage of claudin-1-positive samples was more frequent in MCD patients compared with FSGS patients.

**Keywords:** Minimal change disease, Focal segmental glomerulosclerosis, Claudin-1, CD44

## Introduction

One of the major renal pathologies causing a nephrotic syndrome in adults and children is minimal change disease (MCD) in which, in contrast to focal segmental glomerulosclerosis (FSGS), no glomerulosclerosis damage is observed (1). Considering that there are similar clinical manifestations in patients with MCD and FSGS, the differential diagnosis is usually made by trained pathologists in which the absence or presence of glomerulosclerosis damages is assessed in glomerular podocytes (2,3). Occasionally, it would be difficult to differentiate patients with MCD from those afflicted with FSGS since biopsy specimens have few glomeruli or the disease is still at the early stages of development so that histopathological events are not readily detected in the samples (4). It was thought that parietal epithelial cells (PECs) could not contribute to non-inflammatory glomerular diseases (5). Nowadays, it is reported that

different degrees of epithelial cell hyperplasia have been detected in various types of FSGS, and it seems that PECs are likely to play a role in activating epithelial cells (6). According to recent studies, PECs are implicated in the development of glomerulosclerosis. A primary glomerular injury causes the activation of the PECs of Bowman's capsule that could lead to phenotypic changes in PECs (7). In general, activated PECs have a cubical appearance with enlarged nuclei and are surrounded by secondary pseudo-membrane (7, 8). It has been shown that in a murine model of the disease, the invasion of PECs into glomerular podocytes has been highlighted during the development of glomerulosclerosis in which the activated PECs are precipitated in the tissue matrix (4). In human cases, the same phenomena have been shown concerning the formation of glomerulosclerosis. However, no definitive laboratory evidence has been so far reported in similar mouse models, and conclusions

Received xx xx 2019, Accepted xx xx 2019, Available online xx xx 2020

<sup>1</sup>Department of Pathology, School of Medicine, Tabriz University of Medical Sciences, Tabriz, Iran. <sup>2</sup>Connective Tissue Research Center, Tabriz University of Medical Sciences, Tabriz, Iran. <sup>3</sup>Department of Internal Medicine, School of Medicine, Kidney Research Center, Tabriz University of Medical Sciences, Tabriz, Iran

\*Corresponding Author: Monireh Halimi, Tel:+989143140987, Email: Monirehhalimi@gmail.com



## Key Messages

- ▶ Detection of patient with FSGS
- ▶ Differentiation of patients with FSGS from patients with MCD.

are made by immunohistochemical markers (1,9). The CD44 marker is the primary receptor for osteopontin and hyaluronic acid and is involved in cell migration, cellular matrix adhesion, and cell adhesion (9,10). In the activated PECs, the re-expression of CD44 has been observed, and they could be detected in tissues affected by FSGS, as well as Bowman's capsule and adjacent to cell junctions (4). Claudin-1 is also a protein encoded by the human CLDN1 gene. Further, the claudin-1 marker is a tight junction molecule (8,11). In a study in 2006, it was observed that this molecule is expressed by PECs inside the glomeruli (12). The two markers of CD44 and claudin-1 are inherently expressed by PECs that can be fully employed for the detection of PECs in cases of their invasive to glomerular podocytes (8). In this regard, the current study aimed to investigate the expression of CD44 and claudin-1 using immunohistochemical methods to differentiate patients with MCD from those afflicted with FSGS.

## Materials and Methods

### Study Design

In this descriptive-analytical study, 60 patients with renal diseases referring to Imam Reza hospital affiliated with Tabriz University of Medical Sciences and undergoing a renal biopsy, were randomly selected and enrolled in the study. To determine the sample size, patients were chosen via convenience sampling method due to the limited number of patients with renal diseases. Patients included those being candidates for renal biopsy and treatment-naïve. The research was conducted in the pathology unit of Imam Reza hospital, Tabriz University of Medical Sciences. The inclusion criteria were candidates for biopsy as a result of kidney diseases, proteinuria caused by nephrotic syndrome, and diagnosed with definite FSGS, FSGS/MCD spectrum, and definite MCD. On the other hand, the exclusion criteria were the inadequacy of samples from biopsy, diagnosed with other renal disorders, and FSGS specimens with advanced glomerulosclerosis.

### Study Procedures

In this study, 20, 20, and 7 patients with definite FSGS, FSGS/MCD spectrum, and definite MCD were randomly chosen from individuals who referred to Imam Reza hospital of the Tabriz University of Medical Sciences and underwent biopsy, respectively. The process of sample collection was based on the convenience sampling technique. The final diagnosis of patients was made using light microscopy and immunofluorescence staining performed by two expert pathologists. All renal samples were evaluated for the presence of the immune complex

using immunofluorescence microscopy. Two paraffinized slides of each sample were selected for the assessment of the expression levels of CD44 and claudin-1. The paraffin-embedded specimens (sectioned at the thickness of 4 µm) were deparaffinized and placed in citrate-based antigen unmasking solution, preheated to 90-100°C for antigen retrieval. The slides were then incubated with primary monoclonal antibodies against CD44 and claudin-1. These two markers were then probed by Vectastain ABC-kit (Vector Laboratories, Burlingame, CA) in which the peroxidase enzyme uses 3,3'-diaminobenzidine as a substrate to visualize the protein bands. The nuclear counterstaining was carried out using Mayers hematoxylin staining. To investigate the histological changes in biopsy samples by the classical diagnostic method, some paraffinized specimens were stained with periodic acid-Schiff. Samples were separately examined by two pathologists after staining procedures. They were referred to the third pathologist in the case of divergence between the two pathologists. Finally, the positivity of each marker was assessed in all three groups of MCD, FSGS, and FSGS/MCD spectrums.

It should be noted that the gold standard and the degree of accuracy in CD44 and claudin-1 staining were defined as the minimum staining of tissue samples. At all stages of the study, the cases were registered, and the variables were collected and recorded as well. Finally, the data were analyzed by SPSS software, version 17. The specificity and sensitivity of markers were determined by the percentage of tissue staining by each marker.

### Measured Parameters

The levels of CD44 and claudin-1 markers were measured in all experimental groups and collected as preliminary data. The principal and specific goals of the study were determined based on the above data.

### Statistical Analysis

SPSS software was applied to investigate the obtained values. The values are expressed as the frequency and percentage.

### Results

The results showed that among 20 samples with definite FSGS, 13 specimens (65%) were double positive for CD44 and claudin-1, 3 samples were only positive for claudin-1, and 4 samples were double negative for CD44 and claudin-1. The percentage of CD44 and claudin-1 positivity in FSGS specimens is depicted in Table 1.

As shown, the sensitivity and accuracy (specificity) of the claudin-1 marker for the diagnosis of FSGS samples were higher compared to the CD44 marker.

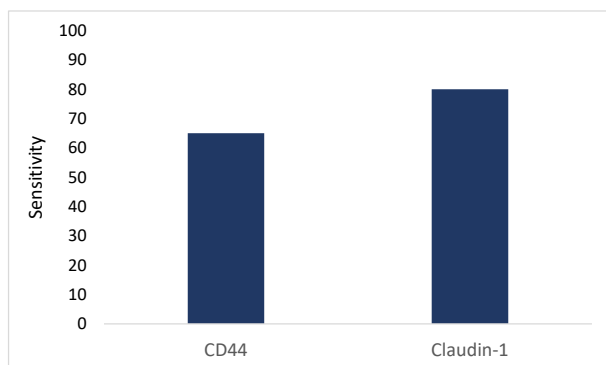
As illustrated in Figure 1, the sensitivity of the claudin-1 marker for the detection of FSGS samples was higher than that of the CD44 marker.

Among 20 specimens diagnosed with FSGS/MCD

**Table 1.** Diagnostic Parameters of CD44 and Claudin-1 Markers in FSGS Samples

| Diagnostic Parameters of Markers | Claudin-1 | CD44 |
|----------------------------------|-----------|------|
| Sensitivity                      | 80%       | 65%  |
| Accuracy                         | 0.8       | 0.65 |

FSGS: Focal segmental glomerulosclerosis; Data is reported as percentage (sensitivity) or rate (diagnostic accuracy).

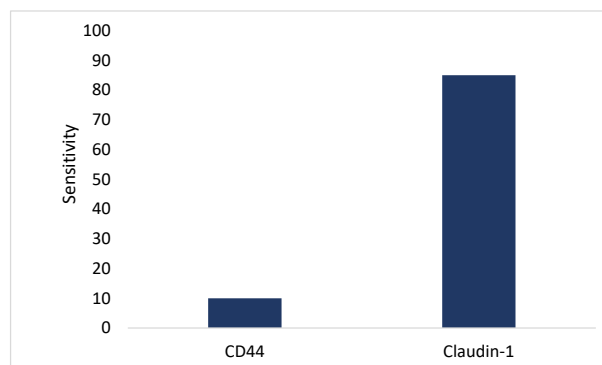


**Figure 1.** Diagnostic Parameters CD44 and Claudin-1 in FSGS Specimens. Note. FSGS: Focal segmental glomerulosclerosis.

**Table 2.** Diagnostic Parameters of CD44 and Claudin-1 Markers in FSGS/MCD Spectrum

| Diagnostic Parameters of Markers | Claudin-1 | CD44 |
|----------------------------------|-----------|------|
| Sensitivity                      | 85%       | 10%  |
| Accuracy                         | 0.85      | 0.1  |

FSGS: Focal segmental glomerulosclerosis; Data is reported as percentage (sensitivity) or rate (diagnostic accuracy).



**Figure 2.** Diagnostic Parameters CD44 and Claudin-1 in FSGS/MCD Specimens. Note. FSGS: Focal segmental glomerulosclerosis.

spectrum, 2 samples (10%) were double positive for CD44 and claudin-1, 15 samples (75%) were only positive for claudin-1, and 3 (15%) specimens were double negative for CD44 and claudin-1. Table 2 presents the percentage of FSGS/MCD spectrum samples.

Based on the obtained data, the sensitivity and accuracy (specificity) of the claudin-1 marker in the FSGS/MCD were more in comparison with the CD44 marker.

As depicted in Figure 2, the sensitivity of the claudin-1 marker for the detection of the FSGS/MCD spectrum was more than that of the CD44 marker.

Among 20 samples obtained from patients diagnosed with definite MCD, all specimens were negative for claudin-1 while the entire samples were negative for CD44. The percentage of positive samples for each of the two markers is presented in Table 3. As shown in Table 3, the sensitivity and accuracy (specificity) of the claudin-1 marker were more than those of the CD44 marker for the detection of MCD samples.

Based on Figure 1, the sensitivity of the claudin-1 marker was higher than that of the CD44 marker regarding the detection of MCD samples.

### Discussion

The results of the study demonstrated that among 20 samples diagnosed with FSGS, 13 specimens (65%) were double positive for CD44 and claudin-1, 3 samples (15%) were only positive for claudin-1, and 4 specimens (20%) were double negative for both CD44 and claudin-1. Hence, the sensitivity and specificity of the claudin-1 marker were considerably higher for the diagnosis of FSGS compared

to the CD44 marker. Among 20 samples diagnosed with the FSGS/MCD spectrum, 2 specimens (10%) were double positive for CD44 and claudin-1, 15 samples (75%) were only positive only for claudin-1, and 3 specimens (15%) were double negative for both CD44 and claudin-1. Therefore, the sensitivity and specificity of the claudin-1 marker were markedly higher for the diagnosis of the FSGS/MCD spectrum in comparison with the marker of CD44. Additionally, among 20 specimens diagnosed with MCD, all samples were negative for claudin-1 while they were all negative for CD44. Thus, the sensitivity and specificity of the claudin-1 marker were significantly higher for the diagnosis of MCD when compared to the CD44 marker.

During the 1970s and 1980s, membranous nephropathy followed by MCD and FSGS syndrome were the most common causes of nephrotic syndrome. However, there has been an increase in the prevalence of FSGS and MCD in recent years so that primary or idiopathic FSGS syndrome in adults and children is one of the leading causes of nephrotic syndrome with a high risk of progression to end-stage renal disease (1-3). FSGS is characterized by the presence of mesangial sclerosis, hypertrophy, and the

**Table 3.** Diagnostic Parameters of CD44 and Claudin-1 Markers in MCD Samples

| Diagnostic Parameters of Markers | Claudin-1 | CD44 |
|----------------------------------|-----------|------|
| Sensitivity                      | 0%        | 0%   |
| Accuracy                         | 0         | 0    |

FSGS: Focal segmental glomerulosclerosis; Data is reported as percentage (sensitivity) or rate (diagnostic accuracy).

hyperplasia of epithelial cells, as well as the destruction of glomerular capillaries and connections between glomeruli and Bowman's capsule (2). Due to similar clinical manifestations presented in MCD and FSGS, the differential diagnosis between these two disorders is highly important and made by pathologists, and numerous studies have been so far conducted to help differentiate between patients with MCD and FSGS. Considering the development of the use of immunohistochemical markers in laboratory studies, the present study examined the sensitivity of CD44 and claudin-1 markers in patients with definite FSGS, FSGS/MCD spectrum, and definite MCD. In the present study, all patients were selected from among newly diagnosed patients who were treatment-naïve in order to eliminate confounding factors. Both of these markers were studied in all three groups (13). In this regard, Enck et al also investigated claudin-2 in the renal nephron of mice. In this study, *in situ* hybridization and immunohistochemistry were used by including polyclonal antibodies against the COOH terminal of the protein. Claudin-2 and its cognate mRNA were found throughout the proximal tubule, and the segment of the thin descending limb of Henle's loop in the contiguous early. The level of claudin-2 expression indicated an axial increase from proximal to distal segments. Eventually, the findings of this study showed that claudin-2 is an element belonging to the para-cellular pathway of the most proximal segments of nephrons (13). The results of Enck et al suggested the fidelity of immunohistochemical markers in pathologic diagnosis. In another study, Gong et al examined the claudin-1 protein in glomerular podocytes using a transgenic murine model (13, 14). They produced a claudin-1 transgenic mouse model with doxycycline-inducible transgene expression, specifically in the glomerular podocytes. The other transgenic mouse line (i.e., TRE-CLDN1) encoding the full-length mouse claudin-1 cDNA was used as a control group. A significant expression of the claudin-1 protein could be evident within the glomerular tuft in transgenic mice that received doxycycline for four weeks while the expression of claudin-1 in PECs remained similar when compared with the control mice (13,14).

In this context, Fatima et al studied whether the activated PECs increase in the early recurrence of FSGS in patients undergoing kidney transplantation. CD44 staining was conducted in renal allograft biopsies that were obtained from twelve patients diagnosed with recurrent FSGS, and then they were compared with native kidneys with MCD or FSGS and normal control native and transplant kidneys without FSGS. The epithelial cells expressing CD44 were evaluated throughout the Bowman's capsule (15). They showed a marked increase in CD44+ visceral epithelial cells involving 29.0% vs. 2.6% of glomeruli in MCD and 0% in non-FSGS transplants. They also demonstrated that CD44 positivity in parietal locations substantially increased in recurrent FSGS. In other transplant biopsies,

glomeruli possessing segmental lesions represented higher CD44 positivity in visceral epithelial cells compared with glomeruli without lesions. In the present study, the percentage of CD44 positivity in FSGS samples was reported 65% while none of the specimens in MCD samples expressed CD44, which is in agreement with the results of Fatima et al (15).

In another study, Smeets et al examined the activated PECs of the glomerular tissue in FSGS and MCD specimens. In this study, they collected 95 renal biopsies from patients with nephrotic syndrome. Then, the obtained samples were stained with antibodies against claudin-1 (as a marker of PECs), CD44 (as a marker of activated PECs), and LKIV69 (as a marker of the PEC matrix). Among the recruited patients, 38 and 57 cases were diagnosed as early primary FSGS and MCD, respectively. They showed that 87% of the obtained biopsies from patients diagnosed as primary FSGS were positive for the PEC marker expressed on the tuft. Their findings indicated that PEC markers were trackable in FSGS lesions as of the earliest stages of the disease (4). In MCD, no PEC activation was detected by immunohistochemistry. However, the existence of small lesions denoting the glomerular sclerotic process was noticeable in 25% of biopsies that were initially diagnosed as MCD. The authors indicated that such small lesions were indiscernible on standard periodic acid-Schiff staining. Finally, Smeets et al found that LKIV69 is capable of detecting lesions with the highest sensitivity, which is in line with the findings of Fatima et al and those of our research. In the present study, claudin-1 was positive in 80% of FSGS cases, similar to that of Smeets et al (4).

In another study, Froes et al evaluated the role of the CD44 marker in patients with FSGS. In this retrospective study, they enrolled 26 patients with FSGS who underwent renal biopsy between 1985 and 2010. Immunohistochemistry for the expression of CD44 was carried out in all patients. Then, they divided patients into two groups according to whether they were positive or negative for CD44 in PECs. They found a decrease in the baseline estimated glomerular filtration rate (eGFR) of 50% or more. Compared with PEC CD44-negative patients (n = 18), PECs derived from CD44-positive patients (n = 8) exhibited lower baseline values of eGFR and a significant reduction in eGFR. Based on their findings, the rate of CD44 expression on PECs was significantly associated with a decrease in the baseline eGFR of 50% or more. Renal survival markedly diminished in the PECs of patients who were positive for CD44 (3.8 in comparison with 14.6 years). In the present study, CD44 was positive in 65% of patients with FSGS (16).

Regarding the limited time of our study, the association between CD44 expression and survival /prognosis was not feasible, but according to Froes et al, FSGS patients who had a less survival rate and poorer prognosis compared with negative CD44 patients. Regarding the study conducted by Fatima et al, PECs increased prematurely



in FSGS compared with MCD. The results of the study by Fatima et al had the most similarities with the present research, indicating a significant increase in the expression of CD44 in FSGS samples compared with those with MCD. The results of this study are most closely related to those of Smeets et al, concerning the degree of the positive expression of claudin-1 in FSGS specimens (4,15).

In general, most studies performed on the evaluation of immunohistochemical markers in various diseases addressed the feasibility of using these markers. However, discrepancies in the obtained results from different studies might be owing to the difference in the selection of samples, the way of choosing the statistical target population, and the intrinsic difference in the samples. Due to the lack of a study in our geographical region and the northwestern part of Iran investigating the presence of CD44 and claudin-1 markers in patients with FSGS and MCD, a direct comparison of the results of our study with other research would not be possible, and further studies are needed to elucidate this issue. According to the results of the current study and similar investigations, the rate of CD44 positivity was substantially higher in FSGS specimens in comparison with MCD samples whereas the number of specimens positive for claudin-1 was significantly higher in MCD samples compared to FSGS samples.

Finally, due to the significance of the application of immunohistochemical markers and the need for increased diagnostic accuracy and ease of diagnosis, as well as the clinical importance and the lack of consensus agreement in medical reference books, further studies are essential for understanding how these markers contribute to the pathogenesis of FSGS and MCD.

### Conclusions

In the present study, CD44 and claudin-1 were immunohistochemically applied to differentiate FSGS from MCD. Among the collected specimens, 65% of cases were diagnosed with FSGS, and 10% of samples diagnosed with the FSGS/MCD spectrum were positive for CD44 whereas none of the samples were positive for this marker. On the other hand, 80% of FSGS samples, 85% of FSGS/MCD spectrum, 100% of MCD samples were negative for claudin-1. Therefore, according to the results of this study, claudin-1 is a valuable carrier in FSGS, but more studies are necessary in this field.

### Authors' Contribution

TP and MM: concept and design. PM, SAA: data collection and interpretation of the data. MRA and MH: performing of the study and writing of the draft. All authors read and approved the study.

### Conflict of Interests

Authors have no conflict of interests.

### Ethical Issues

The present study was performed after the approval of the Ethics

Committee of the Tabriz University of Medical Sciences, and the information of all patients was kept confidential. Throughout the study, there were no additional diagnostic and therapeutic interventions except for the evaluation of CD44 and claudin-1 markers. Moreover, the cost of analyzing tissue slides was provided by the principal investigator and supported by the Vice-chancellor of Tabriz University of Medical Sciences. No additional charges were received from patients and their families.

### Financial Support

This study was supported by Tabriz University of Medical Sciences.

### References

1. Smeets B, Stucker F, Wetzels J, et al. Detection of activated parietal epithelial cells on the glomerular tuft distinguishes early focal segmental glomerulosclerosis from minimal change disease. *Am J Pathol.* 2014;184(12):3239-3248. doi:10.1016/j.ajpath.2014.08.007
2. D'Agati VD, Kaskel FJ, Falk RJ. Focal segmental glomerulosclerosis. *N Engl J Med.* 2011;365(25):2398-2411. doi:10.1056/NEJMra1106556
3. Braden GL, Mulhern JG, O'Shea MH, Nash SV, Ucci AA Jr, Germain MJ. Changing incidence of glomerular diseases in adults. *Am J Kidney Dis.* 2000;35(5):878-883. doi:10.1016/s0272-6386(00)70258-7
4. Smeets B, Moeller MJ. Parietal epithelial cells and podocytes in glomerular diseases. *Semin Nephrol.* 2012;32(4):357-367. doi:10.1016/j.semnephrol.2012.06.007
5. Ohse T, Pippin JW, Chang AM, et al. The enigmatic parietal epithelial cell is finally getting noticed: a review. *Kidney Int.* 2009;76(12):1225-1238. doi:10.1038/ki.2009.386
6. Appel D, Kershaw DB, Smeets B, et al. Recruitment of podocytes from glomerular parietal epithelial cells. *J Am Soc Nephrol.* 2009;20(2):333-343. doi:10.1681/asn.2008070795
7. Berger K, Schulte K, Boor P, et al. The regenerative potential of parietal epithelial cells in adult mice. *J Am Soc Nephrol.* 2014;25(4):693-705. doi:10.1681/asn.2013050481
8. Goodison S, Urquidí V, Tarin D. CD44 cell adhesion molecules. *Mol Pathol.* 1999;52(4):189-196. doi:10.1136/mp.52.4.189
9. Zhang J, Pippin JW, Krofft RD, Naito S, Liu ZH, Shankland SJ. Podocyte repopulation by renal progenitor cells following glucocorticoids treatment in experimental FSGS. *Am J Physiol Renal Physiol.* 2013;304(11):F1375-1389. doi:10.1152/ajprenal.00020.2013
10. Halford S, Spencer P, Greenwood J, Winton H, Hunt DM, Adamson P. Assignment of claudin-1 (CLDN1) to human chromosome 3q28-->q29 with somatic cell hybrids. *Cytogenet Cell Genet.* 2000;88(3-4):217. doi:10.1159/000015553
11. Tsukita S, Furuse M. Occludin and claudins in tight-junction strands: leading or supporting players? *Trends Cell Biol.* 1999;9(7):268-273. doi:10.1016/s0962-8924(99)01578-0
12. Van Itallie CM, Rogan S, Yu A, Vidal LS, Holmes J, Anderson JM. Two splice variants of claudin-10 in the kidney create paracellular pores with different ion selectivities. *Am J Physiol Renal Physiol.* 2006;291(6):F1288-1299. doi:10.1152/ajprenal.00138.2006
13. Enck AH, Berger UV, Yu AS. Claudin-2 is selectively expressed in proximal nephron in mouse kidney. *Am J Physiol Renal Physiol.* 2001;281(5):F966-974. doi:10.1152/ajprenal.2001.281.5.F966
14. Gong Y, Sunq A, Roth RA, Hou J. Inducible expression of claudin-1 in glomerular podocytes generates aberrant tight junctions and proteinuria through slit diaphragm

- destabilization. *J Am Soc Nephrol.* 2017;28(1):106-117. doi:10.1681/asn.2015121324
15. Fatima H, Moeller MJ, Smeets B, et al. Parietal epithelial cell activation marker in early recurrence of FSGS in the transplant. *Clin J Am Soc Nephrol.* 2012;7(11):1852-1858. doi:10.2215/cjn.10571011
16. Froes BP, de Almeida Araújo S, Bambirra EA, Oliveira EA, Simões ESAC, Pinheiro SVB. Is CD44 in glomerular parietal epithelial cells a pathological marker of renal function deterioration in primary focal segmental glomerulosclerosis? *Pediatr Nephrol.* 2017;32(11):2165-2169. doi:10.1007/s00467-017-3775-4

**Copyright** © 2021 The Author(s); This is an open-access article distributed under the terms of the Creative Commons Attribution License (<http://creativecommons.org/licenses/by/4.0>), which permits unrestricted use, distribution, and reproduction in any medium, provided the original work is properly cited.