



# Unusual Presentation of Hydatid Cyst With Hemoptysis: Diagnosis With Bronchoscopy

Nesrin Ceylan<sup>1\*</sup>, Hulya Gunbatır<sup>2</sup>, Selvi Asker<sup>2</sup>, Nihat Demir<sup>1</sup>

## Abstract

**Introduction:** Hydatidosis can be counted among the most important zoonotic diseases in the world. Echinococcosis is an endemic disease especially in Turkey; however, hydatid disease of the lung is rare and usually results from *Echinococcus granulosus*.

**Case Presentation:** A 12-year-old boy was admitted in the hospital with a history of cough and hemoptysis for one year. Bronchoscopy showed endobronchial lesion and the diagnosis of hydatid disease was confirmed by pathological examination.

**Conclusion:** In spite of being one of the less common causes of hemoptysis, hydatid disease of the lung requires greater attention in countries such as Turkey, where hydatid cyst disease can be seen so common.

**Keywords:** Child, Hemoptysis, Hydatid cyst

## Introduction

Hydatidosis is a zoonotic disease, caused by the *Echinococcus granulosus* (*E. granulosus*) which is one of the major health problems in endemic countries including Turkey (1,2). In our country, the incidence has been reported in rural areas as 20/1000000 (3). Although liver cysts are more common but in children lungs are the most frequent location for hydatid cysts (1,4). Chest pain, cough and hemoptysis are the main findings (1,2). Uncomplicated cysts are seen as round opaque lesions on chest radiography. Infection and perforation may change the radiographic appearance of hydatid cyst, causing an incorrect diagnosis (5,6). Bronchoscopy may be necessary in children with atypical presentation of hydatid disease (7,8). There is limited information in the literature about bronchoscopic evaluation in the diagnosis of hydatid disease in childhood (9,10). This case report presents a child with pulmonary hydatid disease diagnosed by bronchoscopy.

## Case Presentation

A 14-year-old boy was admitted to Yuzuncu Yil University Dursun Odabas Medical Center, Van, with a history of cough and hemoptysis for one year. He had scattered hemoptysis for 4-5 times in one month, which had increased in the past month. He had right hilar and right upper mediastinum enlargement on chest x-ray. There were no prior respiratory symptoms. The patient's history was unremarkable for tuberculosis in family members, contact with animals, or foreign body aspiration.

On physical examination, his respiratory rate was 22 breaths per minute with no fever. Breath sounds were significantly diminished over the upper right lung. Results of laboratory studies showed a leukocyte count of 9400/mm<sup>3</sup>, a hemoglobin level of 16.4 g/dL, a platelet count of 458000/mm<sup>3</sup> with erythrocyte sedimentation rate of 30 mm/h. Chest radiography showed right hilar and right upper mediastinum enlargement and computerized tomography revealed a consolidation with focal bronchiectasis and tree in buds in the right upper lobe anterior. Also about 10 mm diameter cavity area was monitored in this area (tuberculosis, pneumonia), (Figure 1A-C).

Tuberculin skin testing was measured as 5 mm. Flexible bronchoscopy (Olympus®, BF 3C160, 2.8.) was performed for differential diagnosis of nonresolving pneumonia and hemoptysis. Bronchoscopy showed a whitish endobronchial lesion that protruded with coughing and occluding the orifice of the right upper anterior segment totally (Figure 2A-B). He was operated; the 4×4 cm cavity located in the anterior of upper lobe was explored. Material was sent for both pathological and microbiological examination. Acid-fast bacilli and culture of other microorganisms were negative. Pathological examination showed typical three-layered structure of hydatid cyst with an inner germinal layer, a middle acellular layer and an outer fibrous capsule with eosinophils.

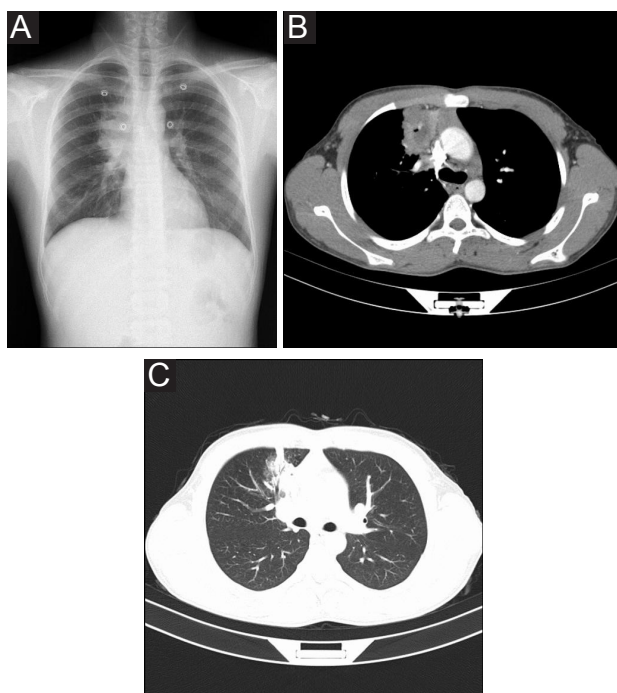
## Discussion

Hydatid cyst diagnosis is made by medical history, ultrasound and other imaging techniques (lung x-ray, computed tomog-

Received 19 October 2015, Accepted 21 January 2016, Available online 1 April 2016

<sup>1</sup>Yüzüncü Yil University, Dursun Odabaş Medical Center, Department of Child Health and Diseases, Van, Turkey. <sup>2</sup>Yüzüncü Yil University, Dursun Odabaş Medical Center, Department of Chest Diseases, Van, Turkey.

\*Corresponding author: Nesrin Ceylan, Tel: +90532 431 85 22, Email: dnesrinceylan@hotmail.com

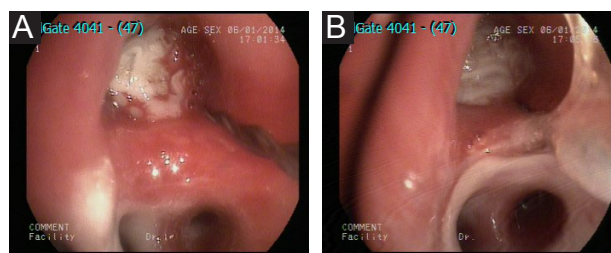


**Figure 1.** (A) Right hilar and upper mediastinum enlargement. (B) A consolidation including about 10 mm diameter cavity area in the right upper lobe anteriorly. (C) A consolidation with focal bronchiectasis and tree in buds in the right upper lobe anteriorly.

raphy, magnetic resonance imaging, etc), serological tests and microscopic examination. The initial phase of primary infection is always asymptomatic.

The clinical presentation of *E. granulosus* infection depends upon the site of the cysts and their size. Small and/or calcified cysts may remain asymptomatic indefinitely. However, symptoms due to mass effect within organs, obstruction of blood or lymphatic flow, or complications such as rupture or secondary bacterial infections can result (1). The most common symptoms of pulmonary cystic echinococcosis (CE) described in the literature include cough (53%-62%), chest pain (49%-91%), dyspnea (10%-70%), and hemoptysis (12%-21%). Less frequent symptoms include malaise, nausea and vomiting and thoracic deformations (1,2). Bronchial tree involvement can lead to cough, chest pain, hemoptysis, or emesis; pleural cavity involvement can cause pneumothorax, pleural effusion, or empyema. Secondary bacterial infection of the cyst can manifest as a pulmonary abscess with poorly defined margins (11,12). Bronchoscopy is unnecessary in patients with a typical clinical and radiological picture but it can be performed for differential diagnosis in cases of atypical radiological appearance. Lung abscess may be evaluated via bronchoscopy or aspiration.

The symptoms of our patient were cough and hemoptysis which is in accordance with hydatid disease but he did not have a typical radiological picture. The initial diagnosis was tuberculosis or pneumonia. Bronchoscopy detected a whitish endobronchial lesion that protruded with coughing, occluding the orifice of the right upper anterior segment totally. The microbiological investigation for *Mycobacterium tuberculosis* was negative. Pathological



**Figure 2.** A whitish endobronchial lesion that protrudes with coughing, occluding the orifice of the right upper anterior segment totally.

and microbiological examination of the material showed features of a pulmonary hydatid cyst and the diagnosis was confirmed by serology.

However unlike adult, there is little information in the literature about the bronchoscopic findings of hydatid disease in childhood (9,10). This case contributes to the literature in an aspect that hydatid cyst should be kept in mind in differential diagnosis of endobronchial lesion.

Management options for CE include surgery, percutaneous management, drug therapy and observation (13). Surgery has been the traditional approach for treatment of CE; subsequently, alternative approaches have been introduced and have replaced surgery as the treatment of choice in some cases (14). Adjunctive drug therapy should be administered to minimize risk of secondary echinococcosis from seeding of protoscolices. Albendazole is generally administered beginning one week prior to surgery and continued for at least four weeks postoperatively. Our case was successfully operated and treated with oral albendazole.

In conclusion, bronchoscopic examination in childhood is valuable in the diagnosis of pulmonary hydatid disease without a typical radiological picture.

#### Ethical issues

The study was completed due to defined rules by the Local Ethics Commission (Yuzuncu Yil University, Ethic Commissions) guidelines and audits.

#### Conflict of interests

The authors declare they have no potential conflicts of interest with respect to the research, authorship, and/or publication of this article.

#### Acknowledgments

we would like to thank to Dursun Odabaş Medical Center, Department of Child Health and Diseases personnel for their contribution.

#### References

1. Santivanez S, Garcia HH. Pulmonary cystic echinococcosis. *Curr Opin Pulm Med.* 2010;16(3):257-261.
2. Arinc S, Kosif A, Ertugrul M, Arpag H, Alpay L, Ünal Ö, et al. Evaluation of pulmonary hydatid cyst cases. *Int J Surg.* 2009;7(3):192-195.

3. Doğan R, Yüksel M, Çetin G, et al. Surgical treatment of the hydatid cyst of the lung: report on 1055 patients. *Thorax*. 1989;44(3):192-199.
4. Todorov T, Boeva V. Echinococcosis in children and adolescents in Bulgaria: a comparative study. *Ann Trop Med Parasitol*. 2000;94(2):135-144.
5. Beggs I. The radiology of the hydatid disease. *Am J Roentgenol*. 1985;145(3):639-48.
6. Turgut AT, Altin L, Topcu S, et al. Unusual imaging characteristics of complicated hydatid disease. *Eur J Radiol*. 2007;63(1):84-93.
7. Saygi A, Otek I, Guder M, Sungun F, Arman B. Value of fiberoptic bronchoscopy in the diagnosis of complicated pulmonary unilocular cystic hydatidosis. *Eur Respir J*. 1997;10(4):811-814.
8. Yilmaz A, Tuncer LY, Damadoglu E, Sulu E, Takir HB, Selvi UB. Pulmonary hydatid disease diagnosed by bronchoscopy: A report of three cases. *Respirology* 2009;14(1):141-143.
9. Hatem K, Dalenda N, Hela H, Mohamed F. An unusual bronchial foreign body: an hydatid cyst membrane. *Tunis Med*. 2000;78(2):143-145.
10. Henry P, Khalfallah A, Lakhal A, Hafsa K, Karoni H. Bronchoscopy in the diagnosis of complicated pulmonary hydatid cyst in children (French). *Rev Mal Respir*. 1984;1(5):313-317.
11. Turgut AT, Altinok T, Topçu S, Koşar U. Local complications of hydatid disease involving thoracic cavity: imaging findings. *Eur J Radiol*. 2009;70(1):49-56.
12. Dziri C, Haouet K, Fingerhut A, Zaouche A. Management of cystic echinococcosis complications and dissemination: where is the evidence? *World J Surg*. 2009;33(6):1266-1273.
13. Brunetti E, Kern P, Vuitton DA; Writing Panel for the WHO-IWGE. Expert consensus for the diagnosis and treatment of cystic and alveolar echinococcosis in humans. *Acta Trop*. 2010;114(1):1-16.
14. Dervenis C, Delis S, Avgerinos C, Madariaga J, Milicevic M. Changing concepts in the management of liver hydatid disease. *J Gastrointest Surg*. 2005;9(6):869-877.

**Copyright** © 2016 The Author(s); This is an open-access article distributed under the terms of the Creative Commons Attribution License (<http://creativecommons.org/licenses/by/4.0>), which permits unrestricted use, distribution, and reproduction in any medium, provided the original work is properly cited.