



# Protective Effects of Vitamin E and Selenium on Liver Tissue Damages Induced by Electromagnetic Field: An Ultrastructural Study

Effat Kiafar<sup>1</sup>, Hamid Tayefi Nasrabadi<sup>1</sup>, Ali Abedelahi<sup>1</sup>, Hamed Shoorei<sup>1</sup>, Abbas Majdi Seghinsara<sup>1\*</sup> 

## Abstract

**Objectives:** The aim of this study was to investigate the effects of vitamin E and selenium (Se) on some liver enzymes, some oxidative stress markers, and the liver structure of mice using light and transmission electron microscope (TEM) following long-term electromagnetic field (EMF) exposure.

**Materials and Methods:** Forty-eight female Balb/c mice were randomly divided into 6 groups (n = 8) as follows: control, EMF, EMF plus vitamin E, EMF plus Se, EMF plus vitamin E and Se, and vitamin E and Se groups. Mice in EMF group were exposed to EMF (3 mT and 50 Hz), 4 hours a day for 2 months. Treated mice received 0.1 mg/kg Se and/or 1.35 mg/kg vitamin E for 2 months intraperitoneally and daily. Anesthesia in mice were induced by ketamine/xylazine (10/2 mg/kg) and after taking blood samples for investigating some liver enzymes, mice were killed by cervical dislocation and their liver were removed by light and TEM for morphological studies and also evaluating some oxidative stress factors.

**Results:** The level of malondialdehyde (MDA) increased in the liver of mice under EMF while the levels of superoxide dismutase (SOD), glutathione peroxidase (GPx), and total antioxidant capacity (TAC) decreased ( $P < 0.05$ ). Treated EMF groups by vitamin E plus Se and vitamin E alone significantly improved the levels of SOD, GPx, and TAC ( $P < 0.05$ ) while treatment with Se did not result in a significant effect. Histopathological analysis revealed that the livers of the mice' that received vitamin E plus Se and vitamin E had fewer morphological changes compared to those of EMF groups. Moreover, some liver enzymes such as serum aminotransferase (AST), serum alanine aminotransferase (ALT), and alkaline phosphatase (ALP) significantly increased in the EMF group in comparison with those of other groups except for the EMF group treated with Se.

**Conclusions:** The results of the study indicated that although Se had no significant effects per se, vitamin E and vitamin E + Se significantly reduced oxidative stress and some liver enzymes.

**Keywords:** Electromagnetic field, Oxidative stress, Vitamin E, Selenium, Liver

## Introduction

Nowadays, development of technological devices has greatly affected the daily life of mankind. Electromagnetic waves or electromagnetic radiations (EMRs), which are emitted by many natural or man-made sources such as the earth's magnetic field, x-rays, radio and television stations, mobile phone stations, and so on, are invisible phenomena having every day effect on more than 3 billion people all over the world (1-4). It has been reported that EMRs have 2 major biological impacts, thermal and non-thermal (3,5). For example, rising of the temperature in living tissues, which is caused by an interaction between EMRs and body's tissues, is one of the effects related to the thermal condition (3). On the other hand, it has been also reported that temperature increase in some body organs such as the brain, is related to the non-thermal radiations,

in which EMRs are absorbed by superficial tissues like the skin; however, non-thermal impacts of MRFs are more related to the amount of energy absorption than temperature changes (2,3). Moreover, it has been pointed out that non-thermal impacts of EMRs are mediated by generation of reactive oxygen species (ROS) (2,3). The ROS have been considered as normal products of cellular oxidative metabolism in mitochondria and also may arise from exogenous sources such as EMRs (3,6-8). They consist of 2 forms including free radical molecules such as hydroxyl radical ( $\text{HO}^{\bullet}$ ) and/or superoxide anion ( $\text{O}_2^{\bullet-}$ ) and non-radical molecules like hydrogen peroxide ( $\text{H}_2\text{O}_2$ ) and/or singlet oxygen ( $^1\text{O}_2$ ) (9). Several studies have stated that electromagnetic field (EMF) could act through the Fenton reaction (a process that converts  $\text{H}_2\text{O}_2$  into  $\text{HO}^{\bullet}$ ) (1,3,6); hence, EMF can promote the activity of

Received 20 August 2017, Accepted 7 March 2018, Available online 26 June 2018

<sup>1</sup>Department of Anatomical Sciences, Faculty of Medicine, Tabriz University of Medical Sciences, Tabriz, Iran.

\*Corresponding Author: Abbas Majdi Seghinsara, Tel: +98-41-33342086; Fax: +98-41-33342086; Mobile: +989148964264; Email: abbas.majdi@yahoo.com



free radicals in body cells and lead to a damage in cellular components including DNA, proteins as well as lipids (1,3,6). Moreover, it was reported that exposure to EMF led to the formation of oxidative stress in some tissues of the body (10). Antioxidant defense systems are naturally developed in the body in order to control the formation of free radicals and to prevent their harmful effects (4,7,8,11). If these systems are unable in preventing the harmful effects of free radicals, the balance between free radicals and antioxidants disrupt and therefore, oxidative stress occurs (9). In a study investigating the effects of EMFs on hepatocyte cells, the results showed that EMFs led to severe steatohepatitis, degenerated hepatocytes, cell membrane disruptions, abnormal lipid accumulations as well as vacuolizations (12). In another study, it was found that EMF resulted in an increase in oxidative stress biomarkers in the endometrium of the rat while the use of vitamin E and C decreased the harmful effects of EMF on mentioned markers (13). In addition, Razavi et al reported that the consumption of vitamin E and Se significantly decreased the deleterious effects of EMF on ovaries of immature mice (4). The Se as an essential trace mineral element, is one of the highly effective antioxidants that can protect body cells against destructive effects caused by free radicals (14). It has been revealed that Se can increase the activity of glutathione peroxidase (GPx) (one of the components of antioxidant enzymes) and also decrease the levels of malondialdehyde (MDA) which is formed by EMF (4). Vitamin E is one of the most powerful naturally occurring antioxidants that acts as scavenging free radicals and also can reduce the cytotoxic effect of lipid peroxidation (LPO) (15). Therefore, it has a major role in preventing the cell and tissue damage induced by free radicals. However, the main aim of this study was to investigate the effects of vitamin E and Se on the ultrastructural properties of liver of mice exposed to EMF.

## Materials and Methods

### Animals and Experimental Design

Forty-eight female Balb/c mice (3-4 weeks old) with average weighting 24 g were used. These mice were purchased from the central house of animals at Tabriz University of Medical Sciences. They were kept in the animal house of Medicine School under standard conditions (light/dark cycle: 12 h, temperature: 24°C, and humidity: 65%) while having free access to water and food. Then, mice were randomly divided into 6 groups (n = 8). 1) Control group; 2) Experimental 1 (EMF): mice were exposed to EMF (3 mT and 50 Hz), 4 hours per day for 2 months; 3) Experimental 2 (EMF + Se): mice were exposed to EMF similar to the previous group and intraperitoneally received 0.1 mg/kg Se per day for 2 months; 4) Experimental 3 (EMF + vitamin E): mice were exposed to EMF similar to the experimental group 2 and intraperitoneally received 1.35 mg/kg vitamin E per day for 2 months; 5) Experimental 4 (EMF + Se

+ vitamin E): mice were exposed to EMF similar to the experimental group 2 and intraperitoneally received 0.1 mg/kg Se + 1.35 mg/kg vitamin E per day for 2 months; 6) Experimental group 5 (without EMF + Se + vitamin E): mice were not exposed to EMF, but intraperitoneally received 0.1 mg/kg Se + 1.35 mg/kg vitamin E per day for 2 months. These doses of Se and vitamin E have been considered based on our previous study. In the last day of experimental period (day 60th), all the mice were first anesthetized using ketamine/xylazine (10/2 mg/kg) and then, their abdomens were exposed and the livers were removed in order to study the tissue damages by toluidine blue (TB) staining and transmission electron microscope (TEM) and also some oxidative stress markers such as MDA, superoxide dismutase (SOD), GPx as well as total antioxidant capacity (TAC).

### The MDA, GPx, SOD, and TAC Assessment

The MDA levels of mice' livers were measured by the method described by Janero based on thiobarbituric acid reaction (TBARS) (16). Moreover, in order to measure cytosolic enzymes such as SOD and GPx, the liver tissue was homogenized in 1.15% KCL, then, the level of SOD was measured using a spectrophotometer based on a method described by Paoletti et al (17) while the level of GPx was measured by Randox kit (UK) based on a method belonging to Paglia and Valentine (18). In addition, using Randox kit, the TAC was measured based on the action ABTS (2,2'-Azino-bis(3-ethylbenzthiazoline-6-sulfonic acid)) + and its inhibition activity by antioxidant compounds of the sample (19).

### Measurement of Liver Variables

To measure liver variables including aminotransferase (AST), alanine aminotransferase (ALT), alkaline phosphatase (ALP), high-density lipoprotein (HDL), and low-density lipoprotein (LDL), about 1 mL of blood sample, depending on the mouse weight, was collected through the left ventricle of the heart then poured into a centrifuge tube without any anticoagulant. The AST and ALT enzymes were measured by phosphate buffer DGKC method and ALP enzyme was measured by P-nitrophenyl phosphate AMP method as well (20). Moreover, serum levels of HDL and LDL were measured using commercial kits (Sigma, Germany) (11,20).

### Histopathological Study

In order to investigate the histopathology of the livers, some of them were prepared for TB staining and TEM. For TB staining, livers were fixed in 10% formaldehyde for 48 hours at the room temperature. Then, using an ascending ethanol sequence, samples were dehydrated and afterward, were cleared with xylene and embedded in paraffin. Finally, sections (3 µm) obtained from the samples were stained with TB. In addition, for ultrastructural analysis, some tissue pieces of livers were fixed in 1%

(v/v) glutaraldehyde (ProSciTech, Thuringowa, Australia) in 0.1 M phosphate buffer, then, post-fixed in 1% (v/v) osmium tetroxide (OSO<sub>4</sub>) (TAAB, Berkshire, UK) in order to analyze ultrastructural characteristics by an electron microscope. Following the fixation, samples were dehydrated using graded concentration of ethanol and were then embedded in the resin. Next, semi-thin sections (1  $\mu$ m) were stained with TB and ultra-thin-sections were also stained with uranyl acetate and lead citrate. Finally, samples were visualized by LEO 906 TEM (Oberkochen, Germany).

### Statistical Analysis

Kolmogorov–Smirnov test was used to determine whether or not the parameters were normal. All the obtained results were assessed by one-way analysis of variance (ANOVA) followed by Tukey test and presented as mean  $\pm$  standard deviation (SD). Differences with  $P < 0.05$  were considered statistically significant.

## Results


### Histopathological Evaluation

Histopathological evaluation of the livers from EMF group showed that EMF caused hepatocyte destruction and also portal space reduction while the sinusoids were dilated (Figure 1A). Histopathological evaluation of the control group revealed that the central vein (CV) was clearly visible with endothelial cell lining in classic lobules. Besides,

polyhedral hepatocytes with their nucleus and cytoplasm, the liver sinusoid with normal morphology and lipid droplets were observed (Figure 1E). Moreover, in the EMF + Se group (Figure 1C), sinusoids showed a decrease in width relative to sinusoids of EMF group and hepatocytes had a little more regular arrangement compared to EMF group. In EMF groups receiving vitamin E and vitamin E + Se (Figures 1B and D), degeneration of hepatocytes was reduced, a regular arrangement of hepatocytes could be seen, and the sinusoids showed a decrease in width compared to EMF group. In addition, histopathological evaluation of the group that only received vitamin E and Se, showed a structure similar to that of the control group (Figure 1.F).

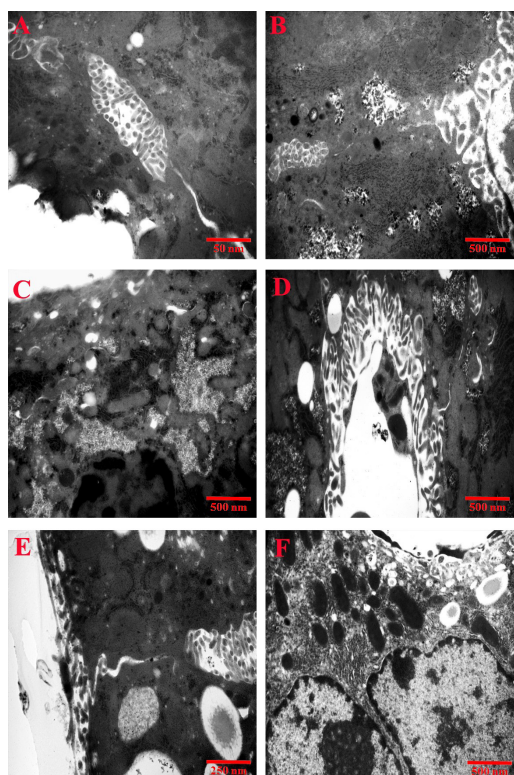
### Ultrastructure

In EMF group (Figure 2A), the ultrastructural alteration in livers showed hepatocytes with condensation and irregularity in shape and heterochromatic nuclei. Moreover, the number of mitochondria decreased, organelles such as RER were sparsely distributed throughout the cytoplasm, and no lipid droplets were seen while some vacuoles could be observed in the hepatocyte cytoplasm. In addition, the space of Disse was wider than the control group. In EMF + vitamin E group (Figure 2B), the number of microvilli within the spaces of Disse had increased in comparison with EMF group; also, cell junctions were observable and the amount of glycogen droplets was increased. The integrity



**Figure 1.** Light Microscopy of the Liver Tissue in Different Groups (T B staining). A: EMF group shows degenerated hepatocytes. B: EMF + Vit. E group shows that degeneration of hepatocytes has reduced compared to EMF group. C: EMF + Se group demonstrates that the width of sinusoids has decreased and hepatocytes displays a little more regular arrangement compared to EMF group. D: EMF + Vit. E + Se group denotes that the degeneration of hepatocytes has reduced compared to EMF group. E: Control group shows classic lobules and CV with regular endothelial cell lining. And finally, F: Vit. E + Se group illustrates a structure similar to control group.





**Figure 2.** The TEM of the Liver Tissue in Different Groups. A: EMF group shows hepatocytes with condensation and irregularity in shape and heterochromatic nuclei. B: EMF + Vit. E group indicates that the number of microvilli within the spaces of Disse has increased in comparison with EMF group. C: EMF + Se group demonstrates that some vacuoles and more glycogens are observable in the hepatocyte cytoplasm. D: EMF + Vit. E + Se group shows that the number of microvilli within the spaces of Disse has increased as compared with EMF group. E: Control group denotes hepatocytes with round and euchromatic nuclei. F: Vit. E + Se group shows that hepatocytes have round and euchromatic nuclei, normal oval or round mitochondria, and regular ERs around nuclei. In addition, lipid droplets can be seen in the cytoplasm of hepatocytes.

of the plasma membrane was maintained and some organelles such as ERs and the Golgi apparatus were easily observable. The number of lipid droplet had decreased as compared with that of the control group. In EMF + Se group (Figure 2C), hepatocytes have pyknotic nuclei, ERs were irregular, the inner membrane of mitochondria was degenerated, and some vacuoles and more glycogens were observable in the hepatocyte cytoplasm as compared to control group. Moreover, the wide of Disse's spaces had increased and the number of microvilli within it had decreased as well. In EMF + vitamin E + Se group (Figure 2D), the number of microvilli within the spaces of Disse had decreased in comparison with the control group while they had increased as compared with EMF group. The wide of Disse's spaces as compared with EMF group had decreased and cell junctions were observable in some areas. The ERs and mitochondria were regular than EMF group and also the number of glycogen droplets had increased in comparison with those of EMF group while being lower than those of the control group. Furthermore,

some vacuolated lysosomes could be seen in the cytoplasm of hepatocytes. The ultrastructural morphology of liver specimens in the control group (Figure 2E) showed hepatocytes with round and euchromatic nuclei, normal oval or round mitochondria, and regular endoplasmic reticulums (ERs). In addition, the cytoplasm contained some lipid and glycogen droplets. The lysosomal vesicles were also observable in the cytoplasm. The number of microvilli within the spaces of Disse was normal. In vitamin E + Se group (Figure 2F), the cell membrane of hepatocytes was regular and the nucleolus could be easily observed. Hepatocytes have round and euchromatic nuclei, normal oval or round mitochondria, and regular ERs around nuclei. The space of Disse was also normal and the number of microvilli within it was increased. Lipid droplets could be observed in cytoplasm of the hepatocytes as well.

#### Serum Levels of ALP, ALT, AST, and Lipid Profiles: HDL and LDL

Serum levels of ALP, ALT, AST, HDL, and LDL are summarized and presented in Table 1. Lipid profiles of the EMF exposed mice showed a significant difference from those of the control mice ( $P < 0.05$ ). Moreover, our results showed that ALP, ALT, and AST significantly increased in EMG group compared to those of the control group ( $P < 0.05$ ). Furthermore, Se could not make any changes when used separately.

#### Oxidative Stress Markers

The levels of oxidative stress markers are summarized and displayed in Table 2.

The level of MDA in the liver tissues of mice under EMF significantly increased in comparison with that of the control group ( $P < 0.05$ ). Moreover, although MDA level of the liver of the mice treated by Se did not show any significant changes in EMF group ( $P > 0.05$ ), in EMF groups receiving vitamin E and vitamin E + Se, the level of MDA significantly reduced in comparison with that of the EMF group ( $P < 0.05$ ). The activity of GPx, MDA as well as TAC was significantly lower in EMF group than control group ( $P < 0.05$ ). Besides, their activities were significantly increased in EMF groups receiving vitamin E and vitamin E + Se compared to those of EMF group ( $P < 0.05$ ). For none of the markers, Se could not make any changes when used separately.

#### Discussion

During 2 last decades, the major focus of EMFs research was to determine whether or not the EMFs increase the risk of developing various diseases such as cancer in human. For example, it has been reported that ELF-EMF could increase the risk of acute and chronic leukemia in children (21). Moreover, numerous studies have been conducted to investigate the effects of EMFs on several organs and tissues of humans and animals (4,13,15). It

Table 1. Levels of Liver Variables

Groups	HDL (mg/dL)	LDL (mg/dL)	ALP (U/mL)	ALT (SGPT) (U/mL)	AST (SGOT) (U/mL)
Control	80.128 ± 32	1620.08 ± 39	243.01 ± 41	80.23 ± 14	228.34 ± 19
EMF	51.92 ± 11*	1924.75 ± 58*	67.375 ± 14*	152.12 ± 19*	334.85 ± 18*
EMF + Vit. E	67.11 ± 19**	1718.62 ± 51**	156.37 ± 19**	86.12 ± 51**	260.75 ± 29**
EMF + Se	57.75 ± 23	1781.12 ± 55	76.12 ± 11	148.25 ± 25	318.37 ± 28
EMF + Se + Vit. E	73.12 ± 15**	1688.19 ± 32**	202.21 ± 23**	101.62 ± 32**	237.57 ± 26**
Se + Vit. E	92.01 ± 12	1543.17 ± 29	375.51 ± 11	78.81 ± 12	225.47 ± 12

Abbreviations: EMF, electromagnetic field; AST, aminotransferase; ALT, alanine aminotransferase; ALP, alkaline phosphatase; HDL, high-density lipoprotein; LDL, low-density lipoprotein.

\* and \*\* show a significant difference compared to control and EMF groups, respectively, for EMF and treated EMF groups.

Table 2. Levels of Oxidative Stress Markers

Groups	MDA (U/mg)	SOD (U/mg)	GPx (U/mg)	TAC (nmol/mL)
Control	1.31 ± 0.14	2.71 ± 0.62	1.35 ± 0.19	1.45 ± 0.11
EMF	1.74 ± 0.32*	1.49 ± 0.71*	0.62 ± 0.81*	0.87 ± 0.53*
EMF + Vit. E	1.43 ± 0.22**	2.32 ± 0.46**	0.88 ± 0.68**	1.24 ± 0.33**
EMF + Se	1.64 ± 0.73	1.91 ± 0.37	0.69 ± 0.43	1.22 ± 0.42
EMF + Se + Vit. E	1.38 ± 0.29**	2.42 ± 0.52**	1.05 ± 0.93**	1.27 ± 0.15**
Se + Vit. E	1.01 ± 0.87	2.75 ± 0.23	1.39 ± 0.51	1.46 ± 0.39

Abbreviations: EMF, electromagnetic field; SOD, superoxide dismutase; MDA, malondialdehyde; TAC, total antioxidant capacity; GPx, glutathione peroxidase.

\* and \*\* show a significant difference compared to control and EMF groups, respectively, for EMF and treated EMF groups.

was reported that EMFs could increase rectal temperature (2°C-4°C) and neutrophil counts, activate macrophages, lead to both bradycardia and tachycardia and also morphological changes in ovaries, fallopian tubes, and uterus epithelium. They also could decrease natural killer cell activity, alter the cell membrane potential, and decrease activity of antioxidant enzymes and incidence of oxidative stress (13,22-24). Oxidative stress has been defined as an imbalance between production of free radicals and elimination of them by antioxidant defense system (7,9). The ROS, through several mechanisms such as oxidation of lipids, proteins, and DNA results in damaging cell membrane and subsequently, cell death occurs via apoptosis and/or necrosis pathways (9). Besides, antioxidant enzyme systems such as SOD, GPx, catalase (CTZ), and several vitamins—A, E, and C—defense from body in contrast to overproduction of ROS (4,25). Moreover, it has been stated that during embryonic development, several tissues and organs including some internal organs, nervous system, bone, and eyes are affected by EMFs (26). Our results showed that the level of MDA, as the marker of LPO, was significantly increased in experimental group 1 while it was decreased in EMF groups which received antioxidants, EMF + vitamin E and EMF + vitamin E + Se. Moreover, in EMF group, the activity levels of SOD, GPx, and TAC were significantly decreased compared to those of control group. In agreement with this section of our results, Razavi et al reported similar results as well (4). Additionally, serum transaminases

(i.e. AST & ALT) significantly increased in EMF group compared to those of control group which is in agreement with the result of the present study (20). The ALT and AST, as specific liver enzymes, have been considered as deleterious enzymes that an increase in their levels can result in hepatic diseases and toxic damage of the liver cells (27). Furthermore, in EMF treated mice, the levels of ALP demonstrated a significant increase in comparison with the control group. In a study, it was found that EMF could increase the level of ALP (28). Our results showed that some lipid profiles, HDL, and LDL, significantly changed in EMF group as compared to those of control group. In line with our result, Aweda et al investigating the effects of microwave radiation, as one of the types of EMF source, on rats reported that EMF caused an increase in the levels of HDL and LDL (29). In addition, in the present research, numerous autophagic and phagocytic vacuoles were observed in the livers of EMF group. Since autophagic vacuoles contain acid phosphatase activity, they are responsible for the degeneration of hepatocytes (30). Moreover, in the liver parenchyma of EMF group, the presence of neutrophils and lymphocytes and also sinusoidal dilatation demonstrated that EMF had a toxic effect on the liver structure. Furthermore, the results of the present study showed that the ultrastructure of mice' liver exposed to 3 mT and 50 Hz for 2 months/4 hours per day led to a severe breakdown and reduction of cell organelles, swollen mitochondria with disappearance of its cristae, and appearance of pro-apoptotic features (vacuoles) which

are responsible for the liver damage. Our study revealed that the treated EMF group alone with Se in comparison with the treated EMF group which received vitamin E, had not enough protective ability. It was found that EMF can lead to mitochondrial swelling due to altering the mitochondrial membrane permeability (31); therefore, this situation resulted in hepatocyte degeneration. In addition, the EMF groups which were treated by vitamin E and Se + vitamin E, had better protective ability compared to EMF group. It is suggested that protective effects of vitamin E along with Se can be attributed to their anti-inflammatory and antioxidant properties (32,33).

### Conclusions

Nowadays, among the developing industrialized countries, EMF is considered as one of the most dangerous environmental pollutants that can increase oxidative stress impact on body systems including the digestive system, especially the liver. Besides, antioxidant supplements can dramatically reduce the amount of damage induced by oxidative stress. The results of the present study showed that IP (intraperitoneal injection) administration of vitamin E + Se and only vitamin E to mice could decrease histopathological hepatic injury induced by EMF.

### Conflict of Interests

Authors have no conflict of interests.

### Ethical Issues

All the experimental procedures were conducted according to the guide for the care and use of laboratory animals of the Tabriz University of Medical Sciences, with an ethical code of IR.TBZMED.REC.1395.119.

### Financial Support

This study was supported by a grant for M.Sc. level at Tabriz University of Medical Sciences from Stem Cell Research Center.

### Acknowledgments

Authors would like to thank Dr. Dariush Mohammad Nejad for TEM imaging.

### References

- Gharamaleki H, Parivar K, Soleimani Rad J, Roshangar L, Shariati M. Effects of extremely low-frequency electromagnetic field exposure during the prenatal period on biomarkers of oxidative stress and pathology of ovarian tissue in F1 generation. *Int J Curr Res Rev*. 2013;5(21):23-29.
- Kiray A, Tayefi H, Kiray M, et al. The effects of exposure to electromagnetic field on rat myocardium. *Toxicol Ind Health*. 2013;29(5):418-425. doi:10.1177/0748233711434957
- Meral I, Mert H, Mert N, et al. Effects of 900-MHz electromagnetic field emitted from cellular phone on brain oxidative stress and some vitamin levels of guinea pigs. *Brain Res*. 2007;1169:120-124. doi:10.1016/j.brainres.2007.07.015
- Razavi SM, Majdi Seghinsara A, Abedelahi A, Salimnejad R, Tayefi H. Effect of Vitamin E and Selenium on Oxidative Stress and Tissue Damages Induced by Electromagnetic Fields in Immature Mice Ovarian. *Crescent J Med Biol Sci*. 2017;4(3):120-125.
- Roshangar L, Hamdi B, Khaki A, Rad JS, Soleimani-Rad S. Effect of low-frequency electromagnetic field exposure on oocyte differentiation and follicular development. *Adv Biomed Res*. 2014;3:76. doi: 10.4103/2277-9175.125874.
- Dröge W. Free radicals in the physiological control of cell function. *Physiol Rev*. 2002;82(1):47-95. doi:10.1152/physrev.00018.2001
- Shoorei H, Khaki A, Ainehchi N, et al. Effects of Matricaria chamomilla Extract on Growth and Maturation of Isolated Mouse Ovarian Follicles in a Three-dimensional Culture System. *Chin Med J (Engl)*. 2018;131(2):218-225. doi:10.4103/0366-6999.222324
- Soltani M, Moghimian M, Abtahi-Eivari SH, Shoorei H, Khaki A, Shokoohi M. Protective Effects of Matricaria chamomilla Extract on Torsion/ Detorsion-Induced Tissue Damage and Oxidative Stress in Adult Rat Testis. *Int J Fertil Steril*. 2018;12(3):242-248. doi:10.22074/ijfs.2018.5324
- Simon HU, Haj-Yehia A, Levi-Schaffer F. Role of reactive oxygen species (ROS) in apoptosis induction. *Apoptosis*. 2000;5(5):415-418.
- Alchalabi ASH, Rahim H, Akilil E, et al. Histopathological changes associated with oxidative stress induced by electromagnetic waves in rats' ovarian and uterine tissues. *Asian Pac J Reprod*. 2016;5(4):301-310. doi:10.1016/j.apjr.2016.06.008
- Abtahi-Evari SH, Shokoohi M, Abbasi A, Rajabzade A, Shoorei H, Kalarestaghi H. Protective Effect of Galega officinalis Extract on Streptozotocin-Induced Kidney Damage and Biochemical Factor in Diabetic Rats. *Crescent J Med Biol Sci*. 2017;4(3):108-114.
- Mahmoud NH. Ultrastructure study on the effect of alternating magnetic field on mice liver. *Egypt J Hosp Med*. 2005;19:168-178.
- Guney M, Ozguner F, Oral B, Karahan N, Mungan T. 900 MHz radiofrequency-induced histopathologic changes and oxidative stress in rat endometrium: protection by vitamins E and C. *Toxicol Ind Health*. 2007;23(7):411-420. doi:10.1177/0748233707080906
- Abedelahi A, Rezaei-Tavirani M, Mohammadnejad D. Fertility preservation among the cancer patients by ovarian tissue cryopreservation, transplantation, and follicular development. *Iran J Cancer Prev*. 2013;6(3):123-132.
- Asghari A, Montaseri A, Khaki AA. An Ultrastructural Study of the Antioxidant Effects of Vitamin E and Fennel Extract on Zona Pellucida Cell Changes of Rat Ovaries under Non-Ionizing 50 Hz Electromagnetic Fields. *Crescent J Med Biol Sci*. 2015;2(2):37-41.
- Janero DR. Malondialdehyde and thiobarbituric acid-reactivity as diagnostic indices of lipid peroxidation and peroxidative tissue injury. *Free Radic Biol Med*. 1990;9(6):515-40.
- Paoletti F, Aldinucci D, Mocali A, Caparrini A. A sensitive spectrophotometric method for the determination of superoxide dismutase activity in tissue extracts. *Anal Biochem* 1986;154(2):536-41.

18. Paglia DE, Valentine WN. Studies on the quantitative and qualitative characterization of erythrocyte glutathione peroxidase. *J Lab Clin Med.* 1967;70(1):158-69.
19. Somi MH, Hajipour B, Asl NA, et al. Pioglitazone attenuates ischemia/reperfusion-induced liver injury in rats. *Transplant Proc.* 2009;41(10):4105-4109. doi:10.1016/j.transproceed.2009.09.075
20. Assasa MF. Effect of cellular phone field on body weight, liver enzymes, blood indices and role of some antioxidant in albino rats. *Al-Azhar Assiut Med J.* 2010;8(3):68-83.
21. Kheifets L, Repacholi M, Saunders R, van Deventer E. The sensitivity of children to electromagnetic fields. *Pediatrics.* 2005;116(2):e303-313. doi:10.1542/peds.2004-2541
22. Fiocchi S, Parazzini M, Liorni I, Samaras T, Ravazzani P. Temperature increase in the fetus exposed to UHF RFID readers. *IEEE Trans Biomed Eng.* 2014;61(7):2011-2019. doi:10.1109/tbme.2014.2312023
23. Jauchem JR. Exposure to extremely-low-frequency electromagnetic fields and radiofrequency radiation: cardiovascular effects in humans. *Int Arch Occup Environ Health.* 1997;70(1):9-21.
24. El-Gohary OA, Said MA. Effect of electromagnetic waves from mobile phone on immune status of male rats: possible protective role of vitamin D. *Can J Physiol Pharmacol.* 2017;95(2):151-156. doi:10.1139/cjpp-2016-0218
25. Ding Z, Li J, Li F, et al. Vitamin C and Vitamin E Protected B95-8 and Balb/c-3T3 Cells from Apoptosis Induced by Intermittent 50Hz ELF-EMF Radiation. *Iran J Public Health.* 2017;46(1):23-34.
26. Gherardini L, Ciuti G, Tognarelli S, Cinti C. Searching for the perfect wave: the effect of radiofrequency electromagnetic fields on cells. *Int J Mol Sci.* 2014;15(4):5366-5387. doi:10.3390/ijms15045366
27. Pashovkina MS, Akoev TG. The liver enzymes which increase in hepatic diseases and toxic damage of liver cells. *Radiats Biol Radioecol.* 2001;41:62-68.
28. Moussa SA. Oxidative stress in rats exposed to microwave radiation. *Rom J Biophys.* 2009;19(2):149-158.
29. Aweda MA, Gbeneditise S, Meindinyo RO. Microwave radiation exposures affect the ldl, hdl, tcl and trg status in rats. *Int J Phys Sci.* 2010;5(7):1015-1022.
30. Elmore S. Apoptosis: a review of programmed cell death. *Toxicol Pathol.* 2007;35(4):495-516. doi:10.1080/01926230701320337
31. Destefanis M, Viano M, Leo C, Gervino G, Ponzetto A, Silvagno F. Extremely low frequency electromagnetic fields affect proliferation and mitochondrial activity of human cancer cell lines. *Int J Radiat Biol.* 2015;91(12):964-972. doi:10.3109/09553002.2015.1101648
32. Tahan G, Aytac E, Aytakin H, et al. Vitamin E has a dual effect of anti-inflammatory and antioxidant activities in acetic acid-induced ulcerative colitis in rats. *Can J Surg.* 2011;54(5):333-338. doi:10.1503/cjs.013610
33. Kim Y, Kim DC, Cho ES, et al. Antioxidant and anti-inflammatory effects of selenium in oral buccal mucosa and small intestinal mucosa during intestinal ischemia-reperfusion injury. *J Inflamm (Lond).* 2014;11(1):36. doi:10.1186/s12950-014-0036-1

**Copyright** © 2018 The Author(s); This is an open-access article distributed under the terms of the Creative Commons Attribution License (<http://creativecommons.org/licenses/by/4.0>), which permits unrestricted use, distribution, and reproduction in any medium, provided the original work is properly cited.