



# A Case Report of Childhood Systemic Lupus Erythematosus Complicated With Bronchiectasis

Soheila Aleyasin<sup>1</sup>, Reza Amin<sup>1</sup>, Mohammadmehdi Araghi<sup>1\*</sup>, Maryam Khosrozadeh<sup>2</sup>

## Abstract

Systemic lupus erythematosus (SLE) is one of the chronic autoimmune diseases affecting the internal organs. Most studies of childhood lupus showed respiratory manifestations in 30% to 50% of cases. Bronchiectasis involves the lung rarely in SLE, specially in children. In a cross-sectional study on 60 Norwegian adults of childhood-onset SLE, only 1 patient (<2%) showed bronchiectasis in high-resolution computed tomography (HRCT) scan without any symptoms of bronchiectasis. Our patient was a girl aged 14 years old who was referred to our center with manifestations of arthritis, cough, pleural effusion, malar rash, photosensitivity, convulsion, anemia, positive ANA, and high titer anti-dsDNA. After 3 years, she was admitted for productive cough. HRCT scan was done, showing bilateral bronchiectasis. The purpose of this presentation was to report bronchiectasis as a rare pulmonary manifestations of SLE in young patients.

**Keywords:** SLE, Bronchiectasis, Young patients, HRCT scan

## Introduction

Systemic lupus erythematosus (SLE) is one of the chronic autoimmune diseases affecting the internal organs such as skin, joints, kidneys, nervous system, heart, blood vessels, blood cells and lungs by deposition of immune complex (1,2). Children have more severe disease in comparison with adults. SLE affects the lungs more than other connective tissue diseases (3). Most reports of childhood lupus show respiratory manifestations in 30% to 50% of cases including pleuritis, acute pulmonary hemorrhage, pneumonia, shrinking lung syndrome, pneumonitis, and pneumothorax (2,4). Pleuritis is the most common disorder (3,5,6) in SLE. Bronchiectasis involves the lungs rarely in SLE, especially in children. In a cross-sectional study on 60 Norwegian adults of childhood-onset SLE, only 1 patient (<2%) showed bronchiectasis in high-resolution computed tomography (HRCT) scan without any symptoms of bronchiectasis (7). These patients were evaluated after 11 years of affliction with the disease. Fenlon et al showed no relationship between HRCT scan chest abnormalities and SLE activity (8). In contrast, Bankier et al indicated a statistically significant relationship between abnormal HRCT scans and SLE duration (9). Moreover, it was reported that the only risk factor related to development of pulmonary manifestations was SLE duration (10).

## Case Report

A girl aged 14 years old was admitted to our center with manifestation including arthritis, cough, pleural effusion, malar rash and photosensitivity. Vital signs on presentation included blood pressure 120/70 mm Hg, pulse rate 85 per minute with regular rhythm, body temperature 37.0°C, and respiration 26 per minute. In the joint examination, symptoms of arthritis including swelling, erythema and severe tenderness were seen in the knees and ankle joints.

There were decreased breathing sounds at the base of both lungs. The abdomen was soft and flat. Other abdominal physical exams were unremarkable. Neurological status was normal. Laboratory evaluation (Table 1) revealed anemia and positive ANA and high titer anti-dsDNA. Urine analysis was normal without cast or protein. Bone marrow aspiration and biopsy was unremarkable and malignant cells were not found. Abdominal and pelvic sonography was normal, but mild bilateral pleural effusion was reported. Based on clinical manifestations, history and laboratory test, our diagnosis was SLE on the basis of 1997 American College of Rheumatology (ACR) revised criteria used to classify SLE, based on the presence of anemia, positive ANA, high titer anti-ds DNA, polyarthritis, malar rash, photosensitivity, and pleural effusion. The patient was administered methylprednisolone 1 g daily for 3 days as well as hydroxychloroquine 200 mg daily. Then, she received prednisolone as 50 mg (1 mg/kg) daily for 2 weeks. The dose of prednisolone was cut down gradually to 10 mg daily. After 3 weeks, she was discharged in good condition. Two weeks later, she was admitted again for convulsion

**Table 1.** Laboratory Data on Admission

WBC	11 700/ $\mu$ L (seg: 70% & lym: 29%)
Hb	7.6 g/L
MCV	85 fl
PLT	450 000/ $\mu$ L
ANA	100 ( neg <20 )
Anti-dsDNA	126 IU/mL (elevated >30)
BUN	16 mg/dL
Cr	0.9 mg/dL
U/A	NL

Abbreviations: WBC, white blood cell; Hb, hemoglobin; MCV, mean corpuscular volume; PLT, platelets; BUN, blood urea nitrogen; Cr, creatinine; ANA, antinuclear antibody.



and high blood pressure. Brain magnetic resonance imaging (MRI) and electroencephalogram (EEG) were normal. Blood pressure was 140/100 mm Hg, so phenytoin, cyclophosphamide and amlodipine were started. She received 750 mg cyclophosphamide stat monthly for 6 months. When the patient was 17, she was admitted for pneumonia. In the lung examination, crackle and wheezing were heard at both lungs. HRCT scan was done, showing bilateral bronchiectasis (Figure 1).

### Discussion

SLE is one of the chronic autoimmune diseases with characteristics as multisystem inflammation together with autoantibodies circulating directed against self-antigens. Most reviews of childhood lupus report respiratory findings in 30% to 50% of cases. Bronchiectasis is a rare complication of SLE. Our patient showed bronchiectasis at age of 17 just 3 years after diagnosis of SLE. Bronchiectasis is uncommon rarely occurring disease which is most often secondary to an infectious process; it leads to abnormal and permanent distortion of one or more of the conducting bronchi or airways. Bronchiectasis is caused by primary infections, bronchial obstruction, aspiration, cystic fibrosis, primary ciliary dyskinesia, allergic bronchopulmonary aspergillosis, and immunodeficiency states. The other causes include congenital anatomic defects, connective-tissue disorders, alpha1-antitrypsin (AAT) deficiency, autoimmune diseases, idiopathic inflammatory disorders, autosomal dominant polycystic kidney disease, and toxic gas exposure. To diagnose the disease, the physicians use HRCT scanning as the standard test (11-13). In our patient, other causes of bronchiectasis were ruled out, so it seems SLE is the only cause for it. Accordingly, it was decided to report this case to show that bronchiectasis can occur early in young people with lupus.

### Conflict of Interests

The authors declare no conflict of interests.

### Ethical Issues

Written informed consent was obtained from the patient and her parents for publication of this case report.

### Financial Support

Not applicable.

### Acknowledgements

The authors would like to thank Shiraz University of Medical Sciences, Shiraz, Iran and also Center for Development of Clinical Research of Nemazee hospital and Dr. Nasrin Shokrpour for editorial assistance.

### References

1. Tan EM, Cohen AS, Fries JF, et al. The 1982 revised criteria for

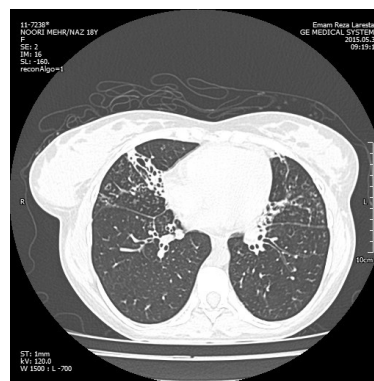


Figure 1. HRCT Scan Showing Bronchiectasis.

the classification of systemic lupus erythematosus. *Arthritis Rheum.* 1982;25(11):1271-1277.

2. Tucker L, Menon S, Schaller J, Isenberg D. Adult- and childhood-onset systemic lupus erythematosus: a comparison of onset, clinical features, serology, and outcome. *Rheumatology.* 1995;34(9):866-72.
3. Murin S, Wiedemann HP, Matthay RA. Pulmonary manifestations of systemic lupus erythematosus. *Clin Chest Med.* 1998;19(4):641-665.
4. Bae SC, Fraser P, Liang MH. The epidemiology of systemic lupus erythematosus in populations of African ancestry: a critical review of the "prevalence gradient hypothesis". *Arthritis Rheum.* 1998;41(12):2091-2099.
5. King KK, Kornreich H, Bernstein B, Singen B, Hanson V. The clinical spectrum of systemic lupus erythematosus in childhood. *Arthritis Rheum.* 1977;20(2 Suppl):287-294.
6. Trapani S, Camiciottoli G, Ermini M, Castellani W, Falcini F. Pulmonary involvement in juvenile systemic lupus erythematosus: a study on lung function in patients asymptomatic for respiratory disease. *Lupus.* 1998;7(8):545-550.
7. Lilleby V, Aaløkken T, Johansen B, Førre Ø. Pediatric rheumatology pulmonary involvement in patients with childhood-onset systemic lupus erythematosus. *Clin Exp Rheumatol.* 2006;24:203-208.
8. Fenlon HM, Doran M, Sant SM, Breatnach E. High-resolution chest CT in systemic lupus erythematosus. *Am J Roentgenol.* 1996;166:301-307.
9. Bankier AA, Kiener HP, Wiesmayr MN, et al. Discrete lung involvement in systemic lupus erythematosus: CT assessment. *Radiology.* 1995;196:835-840.
10. Memet B, Ginzler EM. Pulmonary manifestations of systemic lupus erythematosus. *Semin Respir Crit Care Med.* 2014;35(2):249-254. doi:10.1055/s-0034-1371537.
11. Tiddens HA. Chest computed tomography scans should be considered as a routine investigation in cystic fibrosis. *Paediatr Respir Rev.* 2006;7(3):202-208.
12. Young K, Aspestrand F, Kolbenstvedt A. High resolution CT and bronchography in the assessment of bronchiectasis. *Acta Radiologica.* 1991;32(6):439-441.
13. Smith IE, Flower CDR. Imaging in bronchiectasis. *The Br J Radiol.* 1996;69(823):589-593.