



# Effect of Vitamin E and Selenium on Oxidative Stress and Tissue Damages Induced by Electromagnetic Fields in Immature Mice Ovarian

Seyed Mohsen Razavi<sup>1</sup>, Abbas Majdi Seghinsara<sup>1</sup>, Ali Abedelahi<sup>1</sup>, Ramin Salimnejad<sup>1</sup>, Hamid Tayefi<sup>1\*</sup>

## Abstract

**Objective:** Electromagnetic fields (EMF) due to increased oxidative stress impact on body systems including female reproductive system and reduce fertility. The use of antioxidants decreases the amount of damage through the oxidative stress reduction. The present research studies the effect of vitamin E and selenium on oxidative stress factors level resulting from EMF in immature mice ovarian tissue.

**Materials and Methods:** In this study, 48 immature mice were randomly divided into 6 groups (n=8): (1) control, (2) EMF, (3) EMF with Vitamin E, (4) EMF with selenium, (5) EMF with vitamin E and selenium and (6) vitamin E and selenium. Finally, after 2 months the mice were killed by cervical dislocation and the ovaries were removed to evaluate tissue damages and oxidative stress factors including malondialdehyde (MDA), glutathione peroxidase (GPx), superoxide dismutase (SOD) and total antioxidant (TAC).

**Results:** In mice under EMF, MDA level increased and SOD, GPX and TAC decreased in ovarian tissue ( $P < 0.05$ ). Treatment of mice under EMF via vitamin E with selenium and by vitamin E alone significantly improved these parameters ( $P < 0.05$ ); though, treatment with selenium did not show any significant effect. Histological analysis exhibited the ovaries of the animals that received vitamin E and selenium showed fewer morphological changes than the EMF group.

**Conclusion:** The results of this study indicated that vitamin E and selenium plus vitamin E significantly reduced oxidative stress in ovarian tissue of the mice exposed to EMF, but prescribing selenium alone had no significant effect.

**Keywords:** Electromagnetic field, Oxidative stress, Vitamin E, Selenium, Ovary

## Introduction

Electromagnetic wave or electromagnetic radiation (EMR) is a phenomenon that spreads as propagated in a vacuum or material. These waves include electric and magnetic fields oscillating perpendicular to each other and perpendicular to the direction of energy (1,2). Since the past few decades human has ever been exposed to industrial electric (ELF) and electromagnetic fields (EMFs) from power transmission lines or household electromagnetic waves such as radio, television and mobile phones. EMFs not only are produced in advanced industries such as strong power transmission lines and cell phones but also are widely used in medical diagnosis such as magnetic resonance imaging (MRI) (1,3).

Considering the increasing use of electrical wave generator devices in modern life, exposure to EMF is inevitable. Today, there are discussions on adverse biological effects of these fields on the human body (1,4). Given the huge technological advances in EMFs, there are many controversies among researchers in studying the effects of EMFs on biological tissues (4,5). Yet, there is not a precise molecular mechanism of EMFs impact that causes different human diseases; although, hypotheses

have been proposed in relation to changes in the cell cycle, apoptosis induction, proteins expression change and particularly oxidative stress (6,7).

In general, it is believed that magnetic and electric fields available in the environment increase the probability of DNA damage due to long-term stability of free radicals (5,8,9). The effects of EMFs have been reported on the reproductive process as fertility decline, reduction in implantation rate, live births and the incidence of congenital anomalies (10). Studies have shown that exposure to EMFs can cause morphological changes in the epithelium of uterus, uterus tubes and ovaries as well as cause changes in oxidative stress indices. In this regard, it has been shown that EMF causes increased levels of malondialdehyde (MDA) and decreased activity of ovarian tissue glutathione peroxidase (GPx) and leads to oxidative stress (11). Also, Guney et al indicated that EMF causes changes in biomarkers of oxidative stress in rats' endometrium and the use of vitamin E and C improves the above parameters (12). Due to the increasing expansion of devices generating electromagnetic waves and adverse effects on the reproductive system, it is necessary to look for ways to reduce the side effects caused by EMF. Studies



have shown that the use of antioxidants can reduce the effects of EMF (13,14). Antioxidants such as vitamin E and selenium can be noted.

Vitamin E is a powerful antioxidant that prevents cell damage by destroying free radicals so that it has been observed that vitamin E is able to compensate for the adverse effects of arsenic on thickness of zona pellucida in secondary and antral follicles (15). Selenium is an essential element in human health. There is much evidence suggesting that this mineral plays an important role in normal growth and reproduction in animals and humans (16,17).

In the present study the effect of vitamin E and selenium on oxidative stress and tissue damages induced by EMFs in immature mice ovarian have been investigated.

## Materials and Methods

### Animals

In this experimental study 48 immature female mice (Balb/C) weighing about 24-28 g (3-4 weeks) were used. Animals were prepared of the animals' house of Tabriz University of Medical Sciences and were kept under standard conditions (temperature of 22-24°C with the cycle of light/dark for 12 hours).

### Study Design and Experimental Groups

The animals were randomly divided into 6 groups (n=8): 1) control, 2) EMF, 3) EMF + vitamin E (EMF+ E), 4) EMF + selenium (EMF + S), 5) EMF + vitamin E and selenium (EMF + V & S), and 6) vitamin E and selenium (V + S).

EMR was 4 hours daily for 2 months with 3 mT and 50 Hz. Vitamin E (1.35 mg/kg of body weight) and selenium (0.1 mg/kg of body weight) were also prescribed as gavage daily for 2 months. The doses of vitamin E and selenium were selected on the basis of previous studies. At the end of the experiment, the mice were killed by cervical dislocation and their ovaries were removed to study the tissue damages and oxidative stress factors including MDA, GPx, superoxide dismutase (SOD) and total antioxidant (TAC).

### Malondialdehyde Assessment

Measurement of MDA level is based on thiobarbituric acid reaction (TBARS). Tissue MDA level was measured by the method described by Kaya (18).

### Glutathione Peroxidase and Superoxide Dismutase Assessment

To measure cytosolic enzymes, ovarian tissue was homogenized in 1.15% KCL. The tissue SOD activity was measured based on the method described by Paoletti using a spectrophotometer. Moreover, GPx enzyme activity was measured by Randox (United Kingdom) based on Paglia and Valentine descriptive method (18).

### Total Antioxidant Capacity Assessment

TAC capacity was measured using Randox (United Kingdom). This measure is based on the formation of

cation ABTS + and then its inhibition by antioxidant compounds of the sample.

### Histological Study

Some ovaries were removed and then fixed in formaldehyde (10%) at the room temperature. After fixation, the ovaries were dehydrated with an ascending ethanol sequence, cleared with xylene, and embedded in paraffin. Sections (5 µm) were obtained and stained with hematoxylin and eosin (H&E) for histological examination.

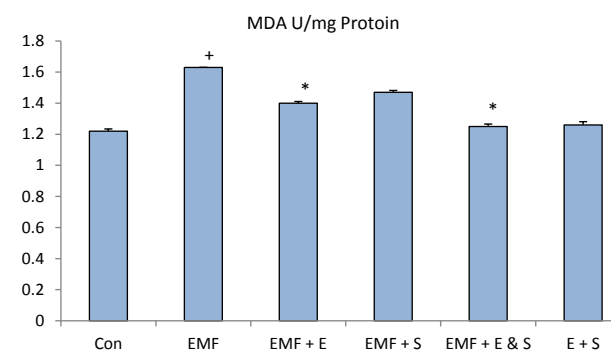
### Statistical Analysis

All statistical analyses were performed via SPSS software. All values were expressed as (mean ± SEM). Finally, the data was analyzed using one-way analysis of variance (ANOVA) followed by Tukey. The results with  $P < 0.05$  were considered statistically significant.

### Results

Figure 1 shows the level of MDA in ovarian tissue. MDA level in the ovarian tissue of the mice under EMF significantly increases as compared to the control group ( $P=0.001$ ). Mice treatment by selenium did not show any significant impact on the decrease of MDA level compared to EMF group ( $P=0.24$ ), while the statistical analysis indicated that the prescription of vitamin E with EMF significantly reduce the level of tissue MDA compared to EMF group ( $P=0.02$ ). In addition, in the group that received vitamin E and selenium with EMF simultaneously, significant MDA reduction was observed ( $P=0.001$ ). The group that received only selenium and vitamin E didn't show significant change in level of MDA compared to the control group ( $P=0.99$ ). MDA level in the group that received vitamin E and selenium with EMF showed no significant effect compared to the group EMF with vitamin E ( $P=0.32$ ), but compared to the group treated with selenium it had a significant reduction ( $P=0.03$ ).

Statistical analysis showed that GPx activity in the ovarian tissue of EMF group significantly decreased compared to the control group ( $P=0.001$ ). GPx activity in mice treated with vitamin E ( $p = 0.009$ ) as well as vitamin E



**Figure 1.** Comparing the MDA Level of Ovarian Tissue in Different Groups.

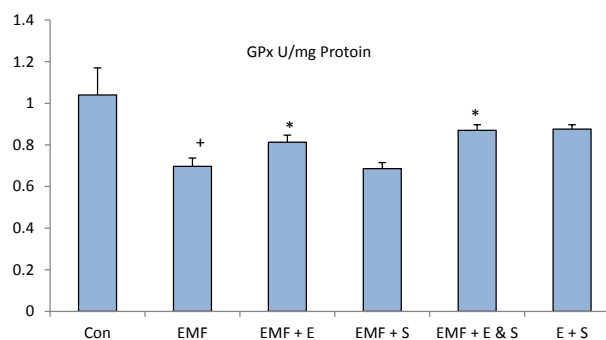
+ shows significant difference with the control group and \* shows significant difference with the EMF group.

plus selenium ( $P=0.001$ ) increased significantly compared to the EMF group; although, prescribed selenium didn't show any significant effect on the GPx activity compared to the EMF group ( $P=0.99$ ). Comparison between the groups treated with vitamin E and selenium with vitamin E group showed no significant difference ( $P=0.5$ ) but a significant increase in GPx activity was observed compared with the selenium group ( $P=0.001$ ) (Figure 2).

Investigation of SOD enzyme activity in ovarian tissue indicated that in EMF group the activity of this enzyme is significantly lower than the control group ( $P=0.001$ ). The comparison between the groups treated with EMF showed a significant increase in the SOD enzyme activity level in mice received vitamin E ( $P=0.001$ ) as well as vitamin E plus selenium ( $P=0.001$ ). However, the mice that only received selenium did not show a significant change than the EMF group ( $P=0.08$ ). The group receiving selenium and vitamin E showed no significant change compared to the control group ( $P=0.41$ ). According to the statistical analysis, the group receiving vitamin E and selenium significantly increased compared to the selenium group ( $P=0.01$ ), but there was no significant difference compared with the vitamin E group ( $P=0.99$ ) (Figure 3).

The results of this study showed that the TAC activity in the ovarian tissue of the mice under the EMF significantly decreased compared to the control group ( $P<0.001$ ). In addition, the enzyme activity in all groups treated with selenium ( $P=0.039$ ), vitamin E ( $P=0.01$ ) and vitamin E + selenium ( $P=0.025$ ) showed a significant increase compared to the EMF group. There was no significant difference between treatment groups ( $P=0.87$ ) (Figure 4).

In the present study, the ovaries and follicles of the control group had normal histology (Figure 5A). Morphological analysis exhibited degenerative changes in cell's arrangement of follicles in ovaries of EMF exposed mice. Also the ovaries of the EMF group showed moderate hemorrhage and congestion on histopathologic examination (Figure 5B). The ovaries of the animals that received vitamin E and selenium showed fewer morphological changes of hemorrhage and congestion than did the EMF group (Figure 5C-F).



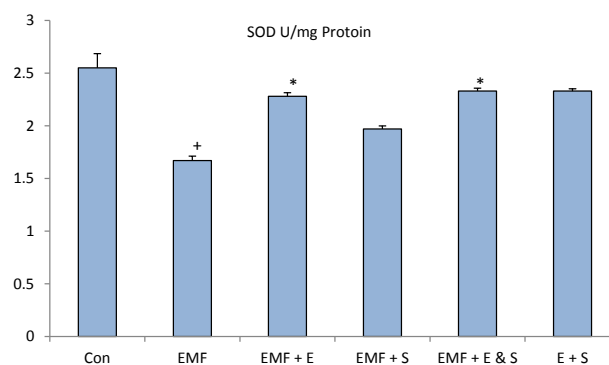
**Figure 2.** Comparing the GPx activity of Ovarian Tissue in Different Groups. + shows significant difference with the control group and \* shows significant difference with the EMF group.

## Discussion

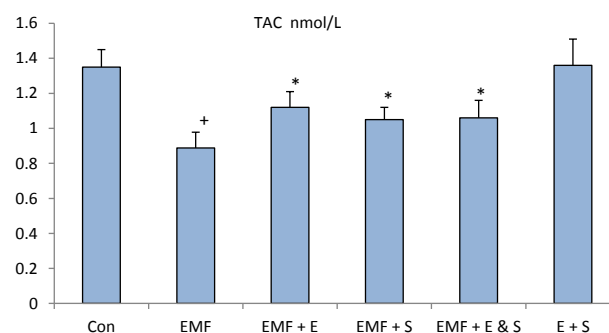
The results of this study suggest that exposure to EMF alters the factors causing oxidative stress and results in oxidative damage. Moreover, the use of antioxidants during the radiation period can reduce the effects of the EMF.

One of the strongest hypotheses that explain EMF effects on different body structures is the imbalance between production and elimination of free radicals and molecules such as peroxides and normal redirections of removing these substances (5,10). EMF can alter the cell membrane potential and ions concentration due to penetration into the cell and through the decreased activity of antioxidant enzymes lead to the change of reactive oxygen species (ROS) and incidence of the oxidative stress (7,19). Oxidative stress through mechanisms such as lipid peroxidation and oxidative damage of protein and DNA cause cell damage (20).

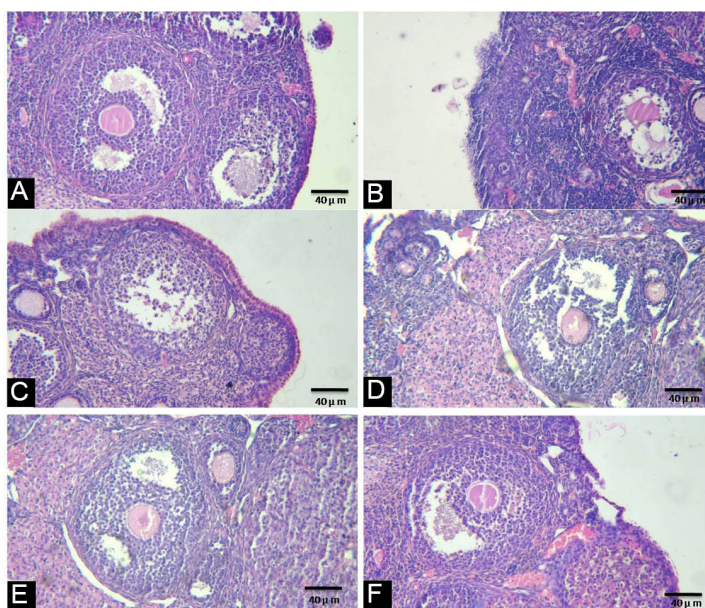
Our results showed that EMF causes significant increase of MDA level (as the marker of lipid peroxidation) and decrease of SOD, GPx and TAC activity level compared to the control group. These findings are consistent with previous studies (21). In this regard, Alchalabi et al



**Figure 3.** Comparing the SOD activity of Ovarian Tissue in Different Groups. + shows significant difference with the control group and \* shows significant difference with the EMF group.



**Figure 4.** Comparing the TAC level of Ovarian Tissue in Different Groups. + shows significant difference with the control group and \* shows significant difference with the EMF group.



**Figure 5.** Light microscopy of ovarian tissue in different groups (H&E). Normal ovarian morphology in the control group (A). Moderate congestion and hemorrhage in an ovary from the EMF group (B). Administration of vitamin E and selenium reduce the morphological change in treatment groups (C,D,E). Se + E group had normal morphology (F).

have shown that exposure to EMF increases the MDA level and decreases GPx activity in ovarian tissue and uterine of rats (11). GPx is an antioxidant enzyme that using glutathione participates in the process of reducing lipid hydroperoxides and hydrogen peroxide to reduce oxidative damage (22). GPx activity decrease suggests the excess use of glutathione and reflects the increasing levels of tissue MDA and oxidative damage. GPx activity decrease and MDA levels increase in ovarian tissue of the group under EMF in this study can be an emphasis on lipid peroxidation increase.

SOD is also one of the most important antioxidant system enzymes that decompose superoxide anion radicals to  $H_2O_2$ . In this way, the toxicity of superoxide disappears and free radicals caused by superoxide aren't created. In the present study it was observed that EMF significantly reduced SOD enzyme activity. This finding is consistent with the results of previous studies (2,12).

In the present study it was seen that treating mice with vitamin E and combination of vitamin E with selenium reduces the level of MDA and increases the activity of GPx and SOD of ovarian tissue in the mice under the EMF; however, prescribed selenium alone did not show significant effect on the factors mentioned above.

Vitamin E is a powerful antioxidant that is able to prevent cell damage by holding sulfhydryl groups of proteins binding to the membrane and eliminating free radicals (6). In this regard, Khaki et al have shown that vitamin E administration can protect ovarian tissue against oxidative damages caused by EMF that our results correspond with their study (15).

Selenium is one of the antioxidant supplements that can be found in large quantities in marine products, liver and cereals (16). There is conflicting information

about the effects of selenium on various tissues and some studies suggest that this mineral can have negative effects on different tissues (23). In the present study, though administration of selenium caused changes in oxidative stress factors, these changes were not significant compared to the EMF group that can be due to the dose used or duration of treatment.

Some previous studies have noted that a combination of vitamin E and selenium can reduce the damage caused by oxidative stress since this element acts as a peroxidase glutathione enzyme cofactor for intracellular antioxidant system and because peroxidase glutathione enzyme completes vitamin E's effects thus combining vitamin E and selenium can increase its antioxidant effects (24). The present study also indicated that combined administration of selenium with vitamin E improves the oxidative stress factors compared to the EMF.

Previous studies have suggested that antioxidants destroy free radicals created during lipid peroxidation (12,15). Therefore, reduced levels of MDA and increased activity of ovarian tissue GPx and SOD in this study in groups treated with vitamin E and selenium and combination of vitamin E may also be related to their antioxidant effects.

Reduced activity of the body's antioxidant system is another factor involved in oxidative damages (25). Therefore, in this study, TAC was also measured. The results showed that EMF reduces the activity of ovarian tissue antioxidant system. But, treating the mice exposed to EMF by vitamin E, selenium and vitamin E with selenium significantly increased the TAC capacity. This finding is consistent with the results of the research conducted by Khaki et al and they have also reported that exposure to EMF leads to the reduction of TAC and treatment by antioxidant prevents this process (14).



Histological study from this research shows that, EMF causes degenerative damages on ovarian tissue such as follicular cell detachment, hemorrhage and congestion in interstitial tissue. These findings conform results of previous study. Bakacak et al shows EMF causes decrees in number of ovarian follicles and degenerative change in interstitial tissue (5). Uses of antioxidant reduce degenerative effects of EMF in treatment groups. Histological examination shows vitamin E and combination of vitamin E with selenium is more effective than selenium.

### Conclusion

The results of this study suggest that exposure to EMF causes damage resulted from oxidative stress. Prescription of vitamin E and vitamin E with selenium can prevent damage caused by EMF due to the elimination of free radicals and increase of the body's antioxidant system activity. The administration of selenium alone showed no significant impact; but, since there is conflicting information about the effects of selenium on various tissues, it is recommended that the effects of different doses of selenium on damages caused by EMF in ovarian tissue to be examined in future studies.

### Ethical Issues

All procedures with animals and working methods were conducted in accordance with the Ethics Committee protocol of Tabriz University of Medical Sciences (IR.TBZMED.REC.1395.119).

### Conflict of Interests

The authors have no conflict of interest in this study.

### Financial Support

Women's Reproductive Health Research Center, Tabriz University of Medical Sciences, Tabriz, Iran.

### Acknowledgements

This study has been done as a MSc thesis of Seyed Mohsen Razavi in Women's Reproductive Health Research Center, Tabriz University of Medical Sciences.

### Reference

1. Tayefi H, Kiray A, Kiray M, et al. The effects of prenatal and neonatal exposure to electromagnetic fields on infant rat myocardium. *Arch Med Sci*. 2010;6(6):837-42. doi: 10.5114/aoms.2010.19288.
2. Gharamaleki H, Parivar K, Rad JS, Shariati RM. Effects of extremely low-frequency electromagnetic field exposure during the prenatal period on biomarkers of oxidative stress and pathology of ovarian tissue in F1 generation. *Int J Curr Res Rev*. 2013;5(21):23-27.
3. Hemayatkhah-Jahromi V, Dehghani K, Fatahi E, et al. The effects of mobile phone waves on the reproductive physiology in adult female rats. *Adv Environ Biol*. 2012;6(10):2735-2741
4. Kiray A, Tayefi H, Kiray M, et al. The effects of exposure to electromagnetic field on rat myocardium. *Toxicol Ind Health*. 2013;29(5):418-25. doi: 10.1177/0748233711434957.
5. Bakacak M, Bostancı MS, Attar R, et al. The effects of electromagnetic fields on the number of ovarian primordial follicles: an experimental study. *Kaohsiung J Med Sci*. 2015;31(6):287-92. doi:10.1016/j.kjms.2015.03.004.
6. Abd El Rahman N, Abd El Hady A, Eltahawy N. Silymarin and vitamin E modulate 950 MHz electromagnetic field-induced oxidative stress and hormonal changes in male albino rats. *J Am Sci*. 2014;10(9):170-176.
7. Meral I, Mert H, Mert N, et al. Effects of 900-MHz electromagnetic field emitted from cellular phone on brain oxidative stress and some vitamin levels of guinea pigs. *Brain Res*. 2007;1169:120-124. doi: 10.1016/j.brainres.2007.07.015.
8. Sies H. *Oxidative stress: introductory remarks*. London: Academic Press; 1985.
9. Roushangar L, Rad JS. Ultrastructural alterations and occurrence of apoptosis in developing follicles exposed to low frequency electromagnetic field in rat ovary. *Pakistan J Biol Sci*. 2007;10(24):4413-4419.
10. Asghari A, Khaki AA, Rajabzadeh A, Khaki A. A review on electromagnetic fields (EMFs) and the reproductive system. *Electronic Physician*. 2016;8(7):2655. doi: 10.19082/2655.
11. Alchalabi AS, Rahim H, Aklilu E, et al. Histopathological changes associated with oxidative stress induced by electromagnetic waves in rats' ovarian and uterine tissues. *Asian Pacific Journal of Reproduction*. 2016;5(4):301-10. doi: 10.1016/j.apjr.2016.06.008.
12. Guney M, Ozguner F, Oral B, Karahan N, Mungan T. 900 MHz radiofrequency-induced histopathologic changes and oxidative stress in rat endometrium: protection by vitamins E and C. *Toxicol Ind Health*. 2007;23(7):411-420. doi: 10.1177/0748233707080906.
13. Hajhosseini L, Khaki A, Merat E, Ainehchi N. Effect of rosmarinic acid on sertoli cells apoptosis and serum antioxidant levels in rats after exposure to electromagnetic fields. *African Journal of Traditional, Complementary and Alternative Medicines*. 2013;10(6):477-480. doi: 10.4314/ajtcam.v10i6.14.
14. Khaki A, Khaki AA, Zahedi A. Effect of *Ocimum basilicum* on ovary tissue apoptosis after exposed with extremely low frequency electromagnetic fields (ELF-EMF) in rats. *Life Sci J*. 2013;10(3):44-50.
15. Asghari A, Montaseri A, Khaki AA. An ultrastructural study of the antioxidant effects of vitamin E and fennel extract on zona pellucida cell changes of rat ovaries under non-ionizing 50 Hz electromagnetic fields. *Crescent Journal of Medical and Biological Sciences*. 2015;2(2):37-41.
16. Said RS, Nada AS, El-Demerdash E. Sodium selenite improves folliculogenesis in radiation-induced ovarian failure: a mechanistic approach. *PloS One*. 2012;7(12):e50928. doi: 10.1371/journal.pone.0050928.
17. Abedelahi A, Rezaei-Tavirani M, Mohammadnejad D. Fertility preservation among the cancer patients by ovarian tissue cryopreservation, transplantation, and follicular development. *Iran J Cancer Prev*. 2013;6(3):123.
18. Somi M, Hajipour B, Asl N, et al. Pioglitazone attenuates ischemia/reperfusion-induced liver injury in rats. *Transplant Proc*. 2009;41:4105-4109. doi: 10.1016/j.transproceed.2009.09.075.
19. Droge W. Free radicals in the physiological control of cell function. *Physiol Rev*. 2002;82(1):47-95. doi: 10.1152/physrev.00018.2001.

20. Salimnejad R, Jalali M, Nikravesh MR, Fazel AR. Protective effects of *Garlic aqueous* extract on germ cells' apoptosis in the male diabetic rats. *IJCLS*. 2014;4(4):1451-155.
21. Odacı E, Ünal D, Mercantepe T, et al. Pathological effects of prenatal exposure to a 900 MHz electromagnetic field on the 21-day-old male rat kidney. *Biotechnic & Histochemistry*. 2015;90(2):93-101. doi:10.3109/10520295.2014.947322.
22. Mittler R. Oxidative stress, antioxidants and stress tolerance. *Trends Plant Sci*. 2002;7(9):405-410. doi:10.1016/S1360-1385(02)02312-9.
23. Hussein AM, Saleh HA, Mustafa H. Effect of sodium selenite and vitamin E on the renal cortex in rats: an ultrastructure study. *Tissue Cell*. 2014;46(3):170-177. doi: 10.1016/j.tice.2014.03.002
24. Mistry HD, Pipkin FB, Redman CW, Poston L. Selenium in reproductive health. *Am J Obstet Gynecol*. 2012;206(1):21-30. doi: 10.1016/j.ajog.2011.07.034.
25. Cunningham MW, Sasser JM, West CA, Baylis C. Renal redox response to normal pregnancy in the rat. *Am J Physiol Regul Integr Comp Physiol*. 2013;304(6):443-449. doi: 10.1152/ajpregu.00496.2012.

**Copyright** © 2017 The Author(s); This is an open-access article distributed under the terms of the Creative Commons Attribution License (<http://creativecommons.org/licenses/by/4.0>), which permits unrestricted use, distribution, and reproduction in any medium, provided the original work is properly cited.