



Intralesional Cryotherapy Versus Intralesional Corticosteroid and 5-Fluorouracil in the Treatment of Hypertrophic Scars and Keloids: A Clinical Trial

Hamideh Azimi Alamdari¹, Ghazaleh Davarnia^{1*}, Hamideh Herizchi Ghadim¹, Asal Sadri¹

Abstract

Objectives: Keloids are raised fibrous scars that extend beyond the boundaries of the original wound and usually reappear after surgical excision. Hypertrophic scars are similar lesions but are limited to wound edges and may regress over time. The aim of the present study was to provide a comparative assessment of intralesional cryotherapy with 2 methods of intralesional injection of triamcinolone and 5-fluorouracil.

Materials and Methods: The study was conducted on Iranian Azeri patients with hypertrophic and keloid scars in Sina hospital (Tabriz-Iran) from August 2016 to May 2017. Twenty-one scars were assigned to each group. The first group received intralesional cryotherapy and the second and third groups were treated with intralesional triamcinolone acetonide (40 mg/mL) 0.2 mL/cm² and 5-fluorouracil (50 mg/mL) 0.2 mL/cm², respectively. Dimensions of the scars (including surface area, height and volume) were measured before and after the study. Therapies were repeated every 4 weeks and would be reapplied for 6 sessions depending on the presence of scar tissue.

Results: A significant decline was found in surface area, height and volume of the scars with cryotherapy after the first session compared to other 2 methods. The decline in surface area, height and volume after the sixth session was 52.9%, 61.37%, and 78.06% respectively with steroid injection and 32.16%, 58.07%, and 60.67% with 5-FU injection. Results also showed that in terms of surface area, height and volume of the disease, there was a significant difference between steroid and 5-FU groups in the sixth session, with the results being more favorable in the former group. Side effects were permanent hypopigmentation, telangiectasia and atrophy in the steroid group; surface wound, hyperpigmentation and increased pain in the 5-FU group; and temporary hypopigmentation in the cryotherapy group.

Conclusions: Results showed that intralesional cryotherapy accelerates keloid healing and has fewer side effects than other treatments.

Keywords: Keloid, Cryotherapy, Steroid, 5-Fluorouracil, Hypertrophic scar

Introduction

Keloid and hypertrophic scars are benign fibroproliferative dermal lesions developed due to overproduction of collagen at the site of an earlier skin wound. Common causes include surgery, vaccination, burns, ear piercing and acne (1).

Keloids are raised fibrous scars that extend beyond the boundaries of the original wound and while not regressing, they usually relapse after surgical excision. The name comes from the Greek *cheloides* meaning crab's claw (2).

Hypertrophic scars are similar lesions but are limited to wound edges and may regress over time. They usually appear one month after the injury while keloids may take 3 months or years to develop. Both lesions are caused by body's abnormal response to dermal damage and are related to excessive collagen deposition in three stages: 1)

inflammation (first 3-10 days), 2) proliferation (next 10-14 days), 3) maturation or remodeling (3 weeks to several years later). Keloids and hypertrophic scars have similar treatments, but the latter has better prognosis (3).

Keloid is a rather painful mass with clear edges, rubbery texture and shiny surface and is mostly telangiectatic. Common affected places are anterior chest, shoulders, earlobes, cheeks, and the skin on joints. Patients complain about pain, itching, and hyperesthesia of the lesions and these symptoms are because of stretched scar tissue and cause discomfort for the patients. The risk of developing keloids is probable in all individuals (except for albinos), but the highest incidence rate is related to dark-skinned people (4).

Treatment of scars is an old challenge and a single effective treatment has not yet been proven for it. Although many therapeutic protocols show varying



degrees of effectiveness, there is little systematic research on this issue (5). Therapeutic modalities for hypertrophic scars and keloids include pressure therapies, silicone gel dressing, intralesional injection (corticosteroid, 5-FU, methotrexate, bleomycin), radiotherapy, cryotherapy and laser (1). Intralesional steroid injection has been used since 1960 to treat hypertrophic and keloid scars. Steroid reduces collagen and glycosaminoglycan synthesis, inflammatory processes, and fibroblast proliferation and raises hypoxia in the scar tissue (6). Its side effects include atrophy, hypopigmentation and telangiectasia (1). In recent decades, intralesional 5-FU, either alone or in combination with steroid, has been suggested for treatment (7). It has been shown that 5-FU reduces fibroblast proliferation in the tissue. The only side effects reported are painful injection, hypopigmentation, purpura, and sometimes wound at the site (1). Intralesional steroid and 5-FU have played a successful role in decreasing pain, itching and volume of scar; however, several therapy sessions are required and the rate of relapse is high (8).

Intralesional cryotherapy is a new therapeutic method that freezes the scar tissue from inside. Intralesional probe allows the destruction of scar by forming intracellular ice crystals and cellular anoxia; in fact, cold damages the endothelial cell connections and causes blood stasis and vascular injury and necrosis (9). Numerous studies have confirmed the effectiveness of intralesional cryotherapy as a monotherapy for scars. Given the intralesional nature of the treatment, complications such as hypopigmentation (compared to normal surface cryotherapy) are much less and the patients experience a shorter recovery period (4). Intralesional cryotherapy reduces the volume and relapse of keloids.

Considering the fact that treatment of hypertrophic and keloid scars is difficult and that no single therapeutic method has been suggested, and since these scars cause aesthetic problems and symptoms for the patients, therefore, the purpose of this study was to compare intralesional cryotherapy with intralesional injection of steroid and 5-FU.

Materials and Methods

This experimental, interventional, double-blind, clinical trial was conducted on Iranian Azeri patients with hypertrophic and keloid scars who had referred to the Dermatology Clinic of Sina hospital (Tabriz-Iran) from August 2016 to May 2017. Patients were first clinically diagnosed and type of scar (hypertrophic or keloid) was determined. Exclusion criteria were pregnancy, breastfeeding, age less than 12 years, history of sensitivity to medications used in this study, uncontrolled blood pressure, liver and kidney diseases, immunodeficiency, and reduction of blood cell count.

A checklist was prepared by the research administrator and completed separately for each patient. Patients were then randomly assigned to three groups based on a random number table. The number of scars in each group

was 21 (sample size included 33 patients with 63 scars) that were distributed in the three groups.

The first group received intralesional cryotherapy alone. The second and third groups were treated with intralesional steroid and 5-FU respectively. Type of the scars (hypertrophic or keloid) was identified prior to the treatments and their dimensions were measured and recorded along with physical appearance such as color, erythema, telangiectasia and accompanying symptoms.

Intralesional cryotherapy was performed using a special needle (designed by an engineer from Sarma Darman Co., Tehran, Iran) and freezing by liquid nitrogen into the scar tissue (Figure 1). Type of the steroid used in this study was triamcinolone acetonide (Triamhexal) 40 mg/mL and 0.2 mL/cm² of it was injected intralesionally using insulin syringe (gauge 27). Then, 0.2 mL/cm² of 5-FU 250 mg/5 mL (EBEWE) was injected intralesionally. The maximum dose of triamcinolone and 5-FU injected in each session was 30 mg/mL and 100 mg/mL, respectively. The treatments were repeated every 4 weeks and would be reapplied for further 6 sessions depending on the presence of scar tissue. Lesions were imaged before and after the treatment. Dimensions (including height) of the scars were measured by means of Vernier scale. Moreover, scar size and physical appearance were examined in each session and recorded in the checklist. Prior to the treatment in the 5-FU group, blood cell count and liver function tests were performed and repeated after the first and sixth sessions.

Collected data were analyzed in SPSS 17.0 using descriptive statistics (mean, standard deviation and frequency, means comparison test, one-way ANOVA and chi-square test). $P < 0.05$ was assumed to be statistically significant.

Results

A total of 63 scars were examined in this study on 33 patients including 20 women, 13 men (13 patients with 2 scars, 12 with 1 scar, 7 with 3 scars and 1 with 4 scars). Patients aged 20-52 years. Of the scars under study, 52 were keloid ranging from 8-month to 2-year scars and 11 were hypertrophic ranging from 4-month to 10-month scars. Ten scars were located on retroauricular region, 36 on torso, 11 on upper limb, 3 on lower limb, 2 on neck and 1 scar was located on the face.



Figure 1. Cryoneedle for intralesional freezing.

One patient with one scar was excluded from the study in the 5-FU group because of increased pain after the third session. In total, of the 63 scars, 56 were itching, 2 scars caused pain and others showed no symptom.

Considering the changes in scar color compared to surrounding skin, 39 scars had mild erythema, 20 showed marked redness, and 4 had the same color as the skin.

Comparison of the means of height, surface area and volume of scars in the steroid group showed that the effect of therapies was manifested for scar height in short term and for surface area and volume in long term. The χ^2 values of the measured qualities of surface area and height of scare during the therapy sessions, age, gender and itching showed that no statistically significant difference existed between observations measurement and calculations in the steroid group (Figure 2).

Results showed that in the 5-FU group, the effect of therapies on scar height and volume became clear after the sixth session and that no significant difference was found between therapy sessions in the surface area. The χ^2 values of the measured qualities of surface area and height of scar during the therapy sessions, age and gender showed that the difference between observations measurement and calculations was statistically insignificant ($P > 0.05$) (Figure 3).

Results in the cryotherapy group showed that the qualities of surface area, height and volume of scar, original size and the size after the first session were significantly different ($P > 0.05$). The χ^2 values of the measured qualities during the therapy sessions, age and gender showed that the difference between observations measurement and calculations was statistically insignificant.

Results of the study showed that the three methods of cryotherapy, 5-FU and steroid had a significant difference at $P < 0.01$ in terms of the original size of scars and the size after the first therapy session.

Comparison of the means of scar height and surface area in the 3 groups showed that the original size of scars in the cryotherapy group was larger than that in the other 2 groups. However, after the first therapy session, the size in this group was smaller than that in other groups; therefore, results showed a remarkable reduction in scar surface area in the cryotherapy than the other 2 groups.

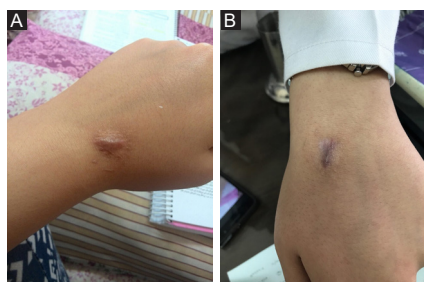

Figure 2. (A) Hypertrophic scar before treatment. (B) flattened scar after 3 session intralesional Triamcinolone therapy. Hypopigmentation is one of the steroid complication.

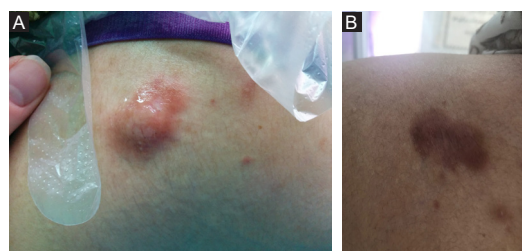

Figure 3. (A) keloid resulted from Acne vulgaris on shoulder before treatment. (B) same keloid after 6 session treatment by intralesional 5-FU. Hyperpigmentation due to 5-FU is notable.

Explicit change in scar volume was noticed after the first session in the cryotherapy group and after the sixth session in the steroid and 5-FU groups (Tables 1 and 2).

The biggest reduction in scar height after the first therapy session was observed in the cryotherapy group (Figures 4-6). After the sixth session of steroid and 5-FU therapy, the smallest size of surface area and height was found in the steroid group indicating the greater effect of steroid on the reduction of scar height and surface area compared to 5-FU. Results showed that the effect of steroid therapy on the reduction of scar volume after the sixth session was greater than the effect of 5FU.

Side effects in the steroid group included permanent hypopigmentation: 4 cases, telangiectasia: 4 cases, and atrophy: 3 cases. In the 5-FU group, side effects were surface wound: 4 cases, hyperpigmentation: 16 cases, and increased pain: 1 case (excluded from the study after 3 months) (Figure 7). Side effects in the cryotherapy group included 3 cases of temporary scar hypopigmentation that disappeared in the follow-up 6 months after the treatment. No infection, liver enzymes disorder or hematologic disorder was observed (Table 3).

Discussion

Keloids and hypertrophic scars are rather prevalent diseases that generally develop in response to the injuries in which damage to the skin is associated with proliferation of dense fibrous tissues developed after dermal lesion recovery. Hypertrophic scars can occur in all races, but keloids are more common in specific races, especially in the individuals who have more pigmented skin (10). Some reports indicate the effect of hormones on the growth and development of these diseases. After 3-4 weeks, the tissue inflammation becomes bigger and thicker. The injury usually becomes tough and turns pink to red and grows for months or years. The surface of keloids is smoother and rounder and continues to grow beyond the original lesion. Various techniques have been used to remove this lesion, but results have not been completely satisfactory (11). Therefore, the purpose of this study was to provide a comparative assessment of three different therapeutic methods, namely steroid, 5-FU, and cryotherapy in the keloid treatment.

Table 1. The Effect of Applied Methods on Height, Surface Area and Volume of Scar at Different Stages of the Study

		Cryotherapy	5-FU	Steroid
Scar height	Original size	3.482 ^a	2.0450 ^a	1/8600 ^a
	After the 1st session	0.783 ^b	1.9300 ^a	1/5525 ^b
	After the 6th session	-	1.5015 ^b	0/7855 ^c
	Significance	0.0001	0.004	0.0001
Scar surface area	Original size	129.1545 ^a	98.5050 ^a	44/1995 ^a
	After the 1st session	23.7805 ^b	97.6750 ^a	43/3820 ^a
	After the 6th session	-	69.8300 ^a	20/8240 ^b
	Significance	0.00001	0/556	0.0001
Scar volume	Original size	460.58 a	221.41 ^a	103/87 ^a
	After the 1st session	18.76 ^b	213.30 ^a	91/15 ^{ab}
	After the 6th session	-	85.08 ^b	22/78 ^b
	Significance	0.0001	0.0001	0.0001

* Letters in each column of the qualities scar surface area, height and volume show statistically significant difference.

Table 2. Comparison of the Qualities of Surface Area, Height and Volume of the Scar in the 3 Therapy Groups at Different Stages

Therapy	Original Size			After the 1st Session			After the 6th Session		
	Surface area (mm ²)	Height (mm)	Volume (mm ³)	Surface Area (mm ²)	Height (mm)	Volume (mm ³)	Surface Area (mm ²)	Height (mm)	Volume (mm ³)
Cryotherapy	129.15 ^a	3.4820 ^a	460.58 ^a	23.7805 ^c	0.7830 ^c	18.76 ^c	-	-	-
Steroid	44.1995 ^c	1.8600 ^b	103.87 ^c	43.3820 ^{ab}	1.5525 ^{ab}	91.15 ^b	20.82 ^b	0.79 ^b	22.78 ^b
5-FU	98.5050 ^b	2.0450 ^b	221.41 ^b	97.6750 ^a	1.9300 ^a	213.30 ^a	66.83 ^a	1.46 ^a	85.08 ^c

* Letters in each column of the qualities scar surface area, height and volume show statistically significant difference.

Table 3. Side effects Associated With Different Therapies

	Side Effects					
	Atrophy	Telangiectasia	Increased Pain	Hyperpigmentation	Hypopigmentation	Surface Wound
5-FU	-	-	5%	80%	-	20%
Steroid	15%	20%	-	-	20%	-
Cryotherapy	-	-	-	-	Temporary 15%	-

Intralesional 5-FU injection acts by restraining the proliferation of fibroblasts and activity of antimetabolites. It also has a preventive effect on type 1 collagen gene expression stimulated by TGF- β in the human fibroblasts (12). 5-FU interrupts DNA and RNA synthesis at different levels by preventing thymidylate synthase and production of toxic metabolites (13). Intralesional triamcinolone injection also prevents protein synthesis and fibroblast migration. Steroids prevent collagen synthesis and have anti-inflammatory effects. Atrophy is a side effect of steroids which are used in the keloid treatment (14).

One research in 2004 showed that the average recovery in cryotherapy and intralesional triamcinolone injection was 67.22 ± 3.5 (15). Another study showed that the therapeutic response to this type of treatment varied from 50% to 100% and that the chance of lesion relapse was up to 50% (2).

Results of a study by Sharma et al on 5-FU and triamcinolone acetate intralesional injection revealed that following the therapies, 96% and 72% of the cases recovered in triamcinolone acetate group and 5-FU group, respectively. The recovery was also better in the

triamcinolone group than in the 5-FU group. Side effects in the 5-FU group including itching, pain, dryness, limited mobility, and aesthetic problems were more than those in the triamcinolone group. No relapse was observed in the scars (11).

Researcher found that atrophy occurred only in 8% of the cases following 5-FU injection, no case of telangiectasia was reported and hyperpigmentation and hypopigmentation were found in 4% of the cases. On the other hand, in the triamcinolone group, atrophy was observed in 12% of the cases, hypopigmentation in 8%, hyperpigmentation in 4%, and telangiectasia in 4% of the cases (11). Some studies report that unless other easier therapies are effective, steroid (TAC, triamcinolone) is the first line therapy for keloid treatment and the second line therapy for HTSs with a response rate of 50% to 100% and relapse rate of 9% to 50% (16). Roques and Teot also showed that intralesional steroid injection caused pain and that 63% of the patients who received therapy reported post-therapy complications including hypopigmentation, subcutaneous atrophy and skin fat, telangiectasia, and ineffectiveness (17).

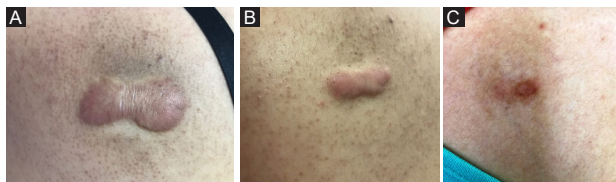


Figure 4. (A) keloid on back region before treatment. (B) Reduction near 50% in size after 1 session intralesional cryotherapy. (C) complete remission of keloid after second cryosurgery.

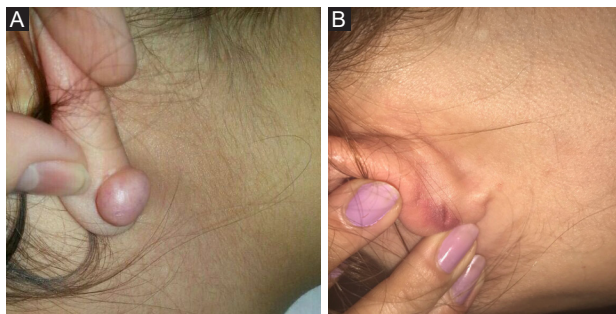

Figure 5. (A) Ear lobe keloid induced after piercing. (B) After one session cryotherapy the keloid is flattened.

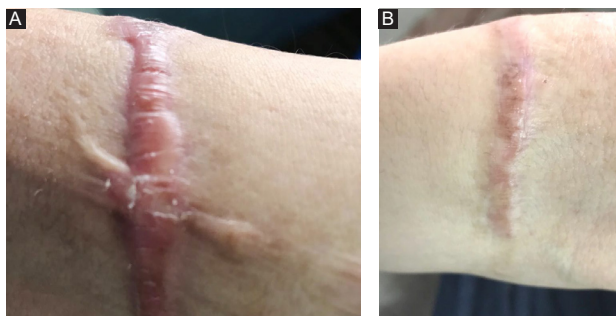

Figure 6. (A) keloid on forearm before treatment by cryosurgery. (B) Notable reduction in keloid size after one session cryosurgery.

In one study by Khan et al in 2014, 150 patients were divided into 2 groups of TAC therapy alone and TAC/5-FU combination therapy. Results showed that in the TAC alone group, recovery was 68% and in the TAC/5-FU group recovery was 84%. In the former group, 24% of the cases showed side effects and in the latter group, side effects were reported in 8% of the cases. Results of the same study showed that TAC/5-FU combination had better outcomes for keloid treatment (18).

Nanda and Reddy treated the keloid scars of 28 patients by intralesional injection of 50 mg/mL 5-FU weekly for 12 weeks. Results showed that 78.5% of the patients reported a recovery rate (in terms of keloid size, height and related symptoms) above 50% and none of the patients reported relapse 24 weeks after the treatment (19). Similar results were reported for small keloids (20). Results of another study showed that recovery rate was above 50% in 85% of the patients (21). One study reported the one-year relapse

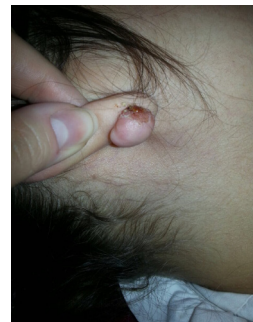


Figure 7. Superficial ulcer is a complication of 5FU injection.

rate at 47.4% (19). Another study in China also showed that the success rate of 5-FU therapy was 62.5% while it was 92% in 5-FU therapy combined with glucocorticoid (22).

In 2012, Prabhu et al in a randomized controlled trial compared the efficacy of intralesional triamcinolone and 5-FU and showed that the treatment with triamcinolone (71.23%) was significantly better than the treatment with 5-FU (57.48%) ($P=0.04$). Pain reduction was 18% in the 5-FU group and 24% in the TAC group, though the difference was not significant. Although side effects in the 5-FU group were 5 times greater than the side effects in the TAC group, their difference was not significant (5). Nevertheless, keloid size reduction in the TAC group was significantly better than that in the 5-FU group (5).

Results of a research in 2017 showed that TAC/5-FU combination instead of TAC alone led to a significant improvement in itching, pain, dryness, mobility limitation, and aesthetic complications (23).

Research has also shown that cryotherapy with liquid nitrogen combined with corticosteroid has been highly successful in treating keloid scars (24). Findings of Har-Shai et al showed that intralesional cryotherapy is capable of concentrating cold temperature inside the wound and thus less affects the external skin tissue. In one study using CryoProbe, a 67.4% size reduction was observed 6 months after the cryotherapy. The redness also decreased and none of the patients developed hypopigmentation or relapse (25). Results of a review study in 2015 showed that in 8 studies conducted, scar volume had decreased from 51% to 63%, but scars had not been removed completely in any of the cases. In addition, relapse rate ranged from 0% to 24%. Post-treatment hypopigmentation was reported in some studies. Pain and itching had been significantly decreased in most of the studies (8). Researchers have reported that intralesional cryotherapy leads to reductions in lesion volume, hypopigmentation and other dermal complications (26). Two different studies showed that no permanent or specific hypopigmentation developed after cryotherapy in white patients (25,26). However, other studies reported hypopigmentation in most of the patients including those with lighter Fitzpatrick skin types. Although hypopigmentation was improved over

time in both studies, it remained permanent in 31% to 37% of the cases (27,28). Research also showed that skin redness decreased by 52%-83% after therapies (8).

Findings of a review study revealed that pain decreased by 52.5% (35%-78%) after treatments and itching decreased 43.6% (28%-61%) but did not completely disappear (8).

In most of the studies, post-treatment lesion volume decreased by more than 50% (8). However, researchers reported that lesions did not disappear after 10 sessions of intralesional cryotherapy (29).

Significant reduction in scar volume, deformity, hardness, redness, itching, dryness and aesthetic complications through cryotherapy has been reported by researchers (30). In addition, hypopigmentation is the most common side effect of contact cryotherapy (91.7) which is less observed in intralesional cryotherapy because of increased viability of melanocytes (26,31). Treatment of the patients with intralesional cryotherapy changes the structure of scar, and collagen fibers are arranged in parallel rows and form the natural structure of dermis (26).

Researchers have suggested that numerous cryotherapy sessions have functional effects on keloids and hypertrophic scars and prevent relapse (32,33). Results also showed that cryotherapy is more effective (85%) than intralesional steroid injection (34). Findings of another study also showed that the combination of cryotherapy and intralesional steroid injection is much more effective than cryotherapy or steroid therapies alone (35).

Researchers treated 25 keloid lesions with intralesional cryotherapy and silicone gel and 7 keloids with cryotherapy. Results showed that keloid volume decreased significantly in all of the cases. In the combinatory method, hardness and patients' pain and discomfort were more favorable while redness and itching in cryotherapy were less than those in the combination therapy (36).

Results of the present study in reducing the surface area, height and volume of keloids with different therapy methods are consistent with the literature. Most of the previous studies have highlighted the better effectiveness of steroid in healing the keloid and its lesser side effects compared to 5-FU method. The present findings also indicated better effectiveness and fewer side effects of steroid in comparison with 5-FU.

Previous studies have confirmed better effectiveness of cryotherapy compared to steroid therapy. Present results also show that cryotherapy have better outcomes than steroid and 5-FU which is in line with previous findings. Although different complications have been reported for cryotherapy, similar to previous studies, only temporary hypopigmentation was observed in this study in 15% of the cases which is consistent with previous studies.

Results of this study showed that cryotherapy is more effective than steroid and 5-FU in treating keloids, and it provides better outcomes in shorter timeframes, and has

fewer complications. Intralesional cryotherapy is effective in reducing the volume of scars in fewer sessions and can be used as the primary treatment for scar followed by other modalities such as steroids to achieve good results.

Conflict of Interests

Authors declare that they have no conflict of interests.

Ethical Issues

This study was approved by Ministry of Health and Medical Education, Iran, and confirmed (identifier: [IRCT20100314003566N9](#)) by the Research and Ethics Committee of Tabriz University of Medical Sciences, Iran.

Financial Support

None.

Acknowledgments

The authors would like to thank Engineer Framarz Jenabi for designing the probe.

References

1. Mutalik S. Treatment of keloids and hypertrophic scars. *Indian J Dermatol Venereol Leprol.* 2005;71(1):3-8. doi:10.4103/0378-6323.13777
2. Dunsy K, Brissett A. Keloids and Hypertrophic Scars. In: Sataloff RT, ed. *Sataloff's Comprehensive Textbook of Otolaryngology: Head & Neck Surgery: Facial Plastic and Reconstructive Surgery.* Jp Medical Ltd; 2015.
3. Thareja S, Kundu RV. Keloids and Hypertrophic Scarring. In: Neelam A, Vashi NA, Maibach HI, eds. *Dermatoanthropology of Ethnic Skin and Hair.* Springer; 2017:233-255.
4. Goldenberg G, Luber AJ. Use of intralesional cryosurgery as an innovative therapy for keloid scars and a review of current treatments. *J Clin Aesthet Dermatol.* 2013;6(7):23-26.
5. Prabhu A, Sreekar H, Powar R, Uppin V. A randomized controlled trial comparing the efficacy of intralesional 5-fluorouracil versus triamcinolone acetonide in the treatment of keloids. *J Sci Soc.* 2012;39(1):19-25. doi:10.4103/0974-5009.96466
6. Wong TS, Li JZ, Chen S, Chan JY, Gao W. The Efficacy of Triamcinolone Acetonide in Keloid Treatment: A Systematic Review and Meta-analysis. *Front Med (Lausanne).* 2016;3:71. doi:10.3389/fmed.2016.00071
7. Rabello FB, Souza CD, Farina Junior JA. Update on hypertrophic scar treatment. *Clinics (Sao Paulo).* 2014;69(8):565-573.
8. van Leeuwen MC, Bulstra AE, Ket JC, Ritt MJ, van Leeuwen PA, Niessen FB. Intralesional Cryotherapy for the Treatment of Keloid Scars: Evaluating Effectiveness. *Plast Reconstr Surg Glob Open.* 2015;3(6):e437. doi:10.1097/gox.0000000000000348
9. Har-Shai Y, Mettanes I, Zilberstein Y, Genin O, Spector I, Pines M. Keloid histopathology after intralesional cryosurgery treatment. *J Eur Acad Dermatol Venereol.* 2011;25(9):1027-1036. doi:10.1111/j.1468-3083.2010.03911.x
10. Shaffer JJ, Taylor SC, Cook-Bolden F. Keloidal scars: a review with a critical look at therapeutic options. *J Am Acad*

- Dermatol. 2002;46(2 Suppl Understanding):S63-97.
11. Sharma S, Bassi R, Gupta A. Treatment of small keloids with intralesional 5-fluorouracil alone vs. intralesional triamcinolone acetonide with 5-fluorouracil. *J Pak Assoc Dermatol.* 2012;22(1):35-40.
 12. Wendling J, Marchand A, Mauviel A, Verrecchia F. 5-fluorouracil blocks transforming growth factor-beta-induced alpha 2 type I collagen gene (COL1A2) expression in human fibroblasts via c-Jun NH2-terminal kinase/activator protein-1 activation. *Mol Pharmacol.* 2003;64(3):707-713. doi:10.1124/mol.64.3.707
 13. Bulstrode NW, Mudera V, McGrouther DA, Grobelaar AO, Cambrey AD. 5-fluorouracil selectively inhibits collagen synthesis. *Plast Reconstr Surg.* 2005;116(1):209-221; discussion 222-203.
 14. Ahuja RB, Chatterjee P. Comparative efficacy of intralesional verapamil hydrochloride and triamcinolone acetonide in hypertrophic scars and keloids. *Burns.* 2014;40(4):583-588. doi:10.1016/j.burns.2013.09.029
 15. Fatemi F, Ahmadpoor K. Evaluation of therapeutic response of Keloid and Hypertrophic scars to bleomycin tattoo and to cryotherapy followed by intralesional triamcinolone injection. *J Shahrekord Univ Med Sci.* 2004;5(4):5-10.
 16. Ho WS, Ying SY, Chan PC, Chan HH. Use of onion extract, heparin, allantoin gel in prevention of scarring in chinese patients having laser removal of tattoos: a prospective randomized controlled trial. *Dermatol Surg.* 2006;32(7):891-896. doi:10.1111/j.1524-4725.2006.32192.x
 17. Roques C, Teot L. The use of corticosteroids to treat keloids: a review. *Int J Low Extrem Wounds.* 2008;7(3):137-145. doi:10.1177/1534734608320786
 18. Khan MA, Bashir MM, Khan FA. Intralesional triamcinolone alone and in combination with 5-fluorouracil for the treatment of keloid and hypertrophic scars. *J Pak Med Assoc.* 2014;64(9):1003-1007.
 19. Nanda S, Reddy BS. Intralesional 5-fluorouracil as a treatment modality of keloids. *Dermatol Surg.* 2004;30(1):54-56.
 20. Gupta S, Kalra A. Efficacy and safety of intralesional 5-fluorouracil in the treatment of keloids. *Dermatology.* 2002;204(2):130-132. doi:10.1159/000051830
 21. Kontochristopoulos G, Stefanaki C, Panagiotopoulos A, et al. Intralesional 5-fluorouracil in the treatment of keloids: an open clinical and histopathologic study. *J Am Acad Dermatol.* 2005;52(3 Pt 1):474-479. doi:10.1016/j.jaad.2004.09.018
 22. Zhang GY, Gao WY, Li X, et al. Effect of camptothecin on collagen synthesis in fibroblasts from patients with keloid. *Ann Plast Surg.* 2009;63(1):94-99. doi:10.1097/SAP.0b013e3181872775
 23. Paul A, Kumar N, Moirangthem T, Singh MK, Hussain KA. Comparative study of intralesional triamcinolone alone and in combination with 5-fluorouracil for the treatment of keloid and hypertrophic scars. *Hellenic Journal of Surgery.* 2017;89(1):13-17. doi:10.1007/s13126-017-0371-9
 24. Zouboulis CC, Blume U, Buttner P, Orfanos CE. Outcomes of cryosurgery in keloids and hypertrophic scars. A prospective consecutive trial of case series. *Arch Dermatol.* 1993;129(9):1146-1151.
 25. Har-Shai Y, Sabo E, Rohde E, Hyams M, Assaf C, Zouboulis CC. Intralesional cryosurgery enhances the involution of recalcitrant auricular keloids: a new clinical approach supported by experimental studies. *Wound Repair Regen.* 2006;14(1):18-27. doi:10.1111/j.1743-6109.2005.00084.x
 26. Har-Shai Y, Amar M, Sabo E. Intralesional cryotherapy for enhancing the involution of hypertrophic scars and keloids. *Plast Reconstr Surg.* 2003;111(6):1841-1852. doi:10.1097/01.prs.0000056868.42679.05
 27. van Leeuwen MC, Bulstra AE, van Leeuwen PA, Niessen FB. A new argon gas-based device for the treatment of keloid scars with the use of intralesional cryotherapy. *J Plast Reconstr Aesthet Surg.* 2014;67(12):1703-1710. doi:10.1016/j.bjps.2014.08.046
 28. van Leeuwen MC, van der Wal MB, Bulstra AE, et al. Intralesional cryotherapy for treatment of keloid scars: a prospective study. *Plast Reconstr Surg.* 2015;135(2):580-589. doi:10.1097/prs.0000000000000911
 29. Gupta S, Kumar B. Intralesional cryosurgery using lumbar puncture and/or hypodermic needles for large, bulky, recalcitrant keloids. *Int J Dermatol.* 2001;40(5):349-353.
 30. Har-Shai Y, Brown W, Labbe D, et al. Intralesional cryosurgery for the treatment of hypertrophic scars and keloids following aesthetic surgery: the results of a prospective observational study. *Int J Low Extrem Wounds.* 2008;7(3):169-175. doi:10.1177/1534734608322813
 31. Har-Shai Y, Dujovny E, Rohde E, Zouboulis CC. Effect of skin surface temperature on skin pigmentation during contact and intralesional cryosurgery of keloids. *J Eur Acad Dermatol Venereol.* 2007;21(2):191-198. doi:10.1111/j.1468-3083.2006.01890.x
 32. Rusciani L, Rossi G, Bono R. Use of cryotherapy in the treatment of keloids. *J Dermatol Surg Oncol.* 1993;19(6):529-534.
 33. Zouboulis CC, Zouridaki E, Rosenberger A, Dalkowski A. Current developments and uses of cryosurgery in the treatment of keloids and hypertrophic scars. *Wound Repair Regen.* 2002;10(2):98-102.
 34. Layton AM, Yip J, Cunliffe WJ. A comparison of intralesional triamcinolone and cryosurgery in the treatment of acne keloids. *Br J Dermatol.* 1994;130(4):498-501.
 35. Yosipovitch G, Widijanti Sugeng M, Goon A, Chan YH, Goh CL. A comparison of the combined effect of cryotherapy and corticosteroid injections versus corticosteroids and cryotherapy alone on keloids: a controlled study. *J Dermatolog Treat.* 2001;12(2):87-90. doi:10.1080/095466301317085363
 36. Stromps JP, Dunda S, Eppstein RJ, Babic D, Har-Shai Y, Pallua N. Intralesional cryosurgery combined with topical silicone gel sheeting for the treatment of refractory keloids. *Dermatol Surg.* 2014;40(9):996-1003.