



# Pseudomonas Sepsis and Multiple Brain Abscesses in a Newborn Infant Following Neurosurgical Procedure for Meningocele

Gökmen Bilgili<sup>1\*</sup>, Ezgi Yangın Ergon<sup>2</sup>, Burcu Kara<sup>2</sup>, Merve Özyurt<sup>2</sup>, Gülgün Yılmaz Ovalı<sup>3</sup>, Ahmet Şükrü Umur<sup>4</sup>, Mehmet Selçuki<sup>4</sup>

## Abstract

**Introduction:** Postneurosurgical brain abscess carries a high risk of neurologic morbidity and mortality.

**Case Presentation:** A newborn infant had *Pseudomonas sepsis* and multiple brain abscesses after meningocele repair, and was successfully treated medically.

**Conclusion:** Prompt recognition of this life-threatening condition is crucial.

**Keywords:** Multiple brain abscesses, *Pseudomonas aeruginosa*, Newborn.

## Introduction

Brain abscesses may develop following neurosurgical procedures, though not being common. However, they can result in substantial mortality and neurologic morbidity. Thus, prompt diagnosis and treatment is crucial in these cases. In this case report, we present a male newborn infant who suffered *Pseudomonas sepsis* and multiple cerebral abscesses following neurosurgical procedure for meningocele, and recovered on medical treatment without surgical drainage.

## Case Report

A meningocele sac was identified at lumbosacral L5-S1 level in 6x6 cm dimension in a fetus in the intrauterine period. In the neonatal period, preoperative cranial magnetic resonance imaging (MRI) of the infant was normal, and spinal MRI showed posterior fusion defect at L5-S1 level, a large sac concordant with a meningocele, and a low-set conus medullaris. The infant underwent a neurosurgical intervention at 27th postnatal day, and was followed up in the neonatal intensive care unit postoperatively. Pathological examination did not reveal neurological tissue, and hence a diagnosis of meningocele was made. The infant deteriorated clinically at the third postoperative day, had signs of a bulging anterior fontanel, poor sucking and fever, and had elevated acute phase reactants. Empiric treatment with intravenous cefotaxime and vancomycin was commenced with a presumptive diagnosis of sepsis and meningitis after obtaining blood culture. Iv phenytoin was commenced for his tonic-clonic

convulsions. *Pseudomonas aeruginosa* was recovered in blood culture, and the antibiotic therapy was switched to meropenem and netilmicin based on antibiotic susceptibility test results. Cranial MRI with contrast administration and diffusion MRI was obtained on the 14<sup>th</sup> day of treatment, that showed foci of extraaxial abscess in both temporal cerebral hemispheres, foci of abscess in bilateral basal ganglionic and sylvian fissures as intraparenchymal nodularities, extensive pathological contrast concordant with meningitis and endymitis, and hydrocephalic widening of the third, fourth and lateral ventricles (Figure 1). At the sixth week of treatment, a control cranial MRI was obtained and revealed significant regression in foci of extraaxial abscess in both temporal cerebral hemispheres, reactive thickening of dura with enhancement in the same region, intraparenchymal right basal ganglionic microabscess, persistence of hydrocephalic widening of the third, fourth and lateral ventricles, and near-total regression of other parenchymal findings and endymitis (Figure 2). Netilmicin treatment was stopped at the third week of treatment, and meropenem was continued until the ninth week of treatment as for the lack of complete disappearance of abscesses. On completion of treatment, the infant underwent a ventriculoperitoneal (VP) shunt procedure and then discharged for follow-up by the pediatric neurology department.

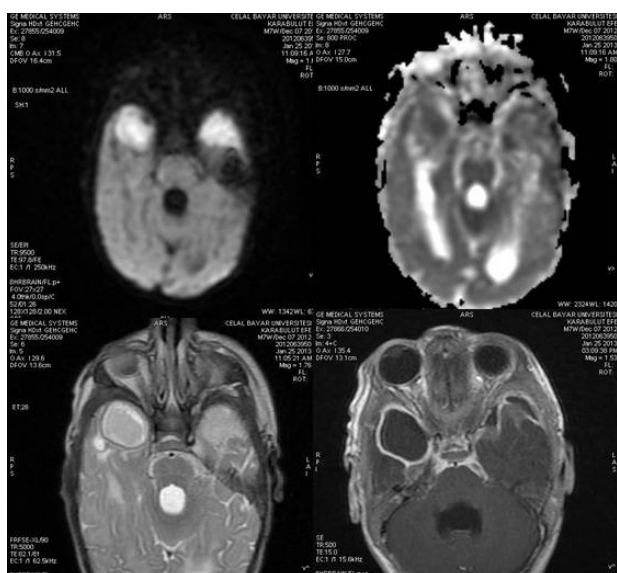
## Discussion

Brain abscesses are intraparenchymal collections of pus with an incidence of approximately 8% of intra-cranial

Received 19 April 2015, Accepted 27 September 2015, Available online 1 October 2015

<sup>1</sup>Celal Bayar University School of Medicine, Department of Pediatrics, Subdivision of Neonatology, Manisa, Turkey. <sup>2</sup>Celal Bayar University School of Medicine, Department of Pediatrics, Manisa, Turkey. <sup>3</sup>Celal Bayar University School of Medicine, Department of Radiology, Manisa, Turkey. <sup>4</sup>Celal Bayar University School of Medicine, Department of Neurosurgery, Manisa, Turkey.

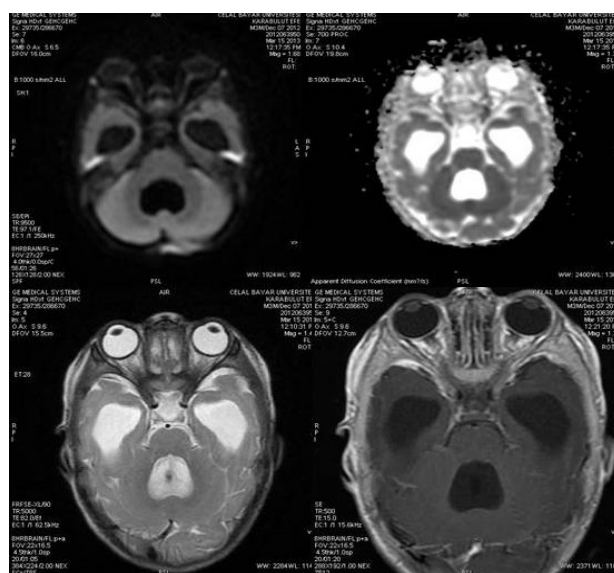
\*Corresponding author: Gökmen Bilgili, Tel: +902362361020-3264, Email: gokmenbilgili@yahoo.com



**Figure 1.** Diffusion and cranial MRI revealing foci of extraaxial abscess collections in both temporal cerebral hemispheres.

masses in developing countries and 1%-2% in the developed countries (1). These abscesses arise from direct extension of adjacent infection, hematogenous seeding, or trauma. No obvious source can be identified between 25% and 35% of cases (2). A hematogenous source is discovered in up to 25% of cases that are commonly bacterial endocarditis and chronic pulmonary infections that spread via the bloodstream (3). A penetrating injury that implants a foreign body can also lead to abscess formation (4). In our case, the etiology was a neurosurgical procedure.

A variety of pathogens can cause brain abscesses. Aerobic gram-positive cocci and aerobic gram-negative rods are recovered in patients with prior neurosurgical procedures or open head trauma. In infants less than 1 month of age, *Citrobacter* and *Proteus* are commonly seen (2,5). *Pseudomonas aeruginosa* was the etiologic agent in our patient. Prompt long-term antimicrobial therapy is the mainstay of treatment. Broad spectrum antibiotics, usually a 3rd or 4th generation cephalosporin, vancomycin, and metronidazole should be initiated and adjusted according to antibiotic susceptibilities in the case of identification of the pathogen. Duration of treatment should be 4-6 weeks in surgically treated abscesses, and 6-8 weeks for those with medical treatment solely (6). Our empiric treatment included cefotaxime and vancomycin, replaced by meropenem and netilmicin based on antibiotic susceptibility test results, and completed to 9 weeks. Medical treatment alone can be considered in abscesses smaller than 2.5 cm in diameter, multiple small abscesses, or for patients who are extremely poor surgical candidates (5). Most brain abscesses undergo surgical drainage along with medical treatment. Surgery serves multiple purposes: reduce raised intracranial pressure, confirm the diagnosis, obtain culture for microbiological testing, enhance efficacy of antibiotic therapy, and avoid spread of infection into the ventricles (1,7). Multiple cerebral abscesses were success-



**Figure 2.** Control diffusion and cranial MRI showing near-total regression in abscess collections.

fully treated with antibiotics alone without need for surgical drainage in this case.

Mortality rate of brain abscesses were over 50% before the widespread use of antibiotics, which has dropped to 4%-12% in children with new antibiotics, better imaging modalities, and improved surgical techniques (8). Delayed diagnosis is especially associated with poor prognosis.

Our patient's convulsions were under control with a single anticonvulsant, and he required a VP shunt procedure before discharge, and is on long-term follow-up in outpatient child neurology clinic.

In summary, treatment of this life-threatening condition should be prompt and long-term, identification of the causative microorganism should be made if possible, advanced neuroimaging modalities should be used for diagnosis and follow-up, and survivors should be on long-term neurologic follow-up.

### Ethical issues

Written informed consent was obtained from the patient for publication of this study.

### Conflict of interests

Authors declare that they have no competing interests.

### Acknowledgments

None.

### References

1. Bonfield CM, Sharma J, Dobson S. Pediatric intracranial abscesses. *J Infect.* 2015;71(Suppl 1):S42-S46.
2. Lu CH, Chang WN, Lui CC. Strategies for the management of bacterial brain abscess. *J Clin Neurosci.* 2006;13(10):979-985.
3. Mathisen GE, Johnson JP. Brain abscess. *Clin Infect*

- Dis. 1997;25(4):763-779.
4. Sims L, Lim M, Harsh GR. Review of brain abscesses. *Oper Tech Neurosurg.* 2004;7(4):176-181.
  5. Alvis-Miranda H, Castellar-Leones SM, Elzain MA, Moscote-Salazar LR. Brain abscess: current management. *J Neurosci Rural Pract.* 2013;4(Suppl. 1):S67-81.
  6. Arlotti M, Grossi P, Pea F, et al. GISIG (Gruppo Italiano di Studio sulle Infezioni Gravi) Working Group on Brain Abscesses. Consensus document on controversial issues for the treatment of infections of the central nervous system: bacterial brain abscesses. *Int J Infect Dis* 2010;14(Suppl 4):S79-92.
  7. Infection in Neurosurgery Working Party of the British Society for Antimicrobial Chemotherapy. The rational use of antibiotics in the treatment of brain abscess. *Br J Neurosurg.* 2000;14(6):525-530.
  8. Nickerson JP, Richner B, Santy K, et al. Neuroimaging of pediatric intracranial infection part 1: techniques and bacterial infections. *J Neuroimaging.* 2012;22(2):e42-51.

**Copyright** © 2015 The Author(s); This is an open-access article distributed under the terms of the Creative Commons Attribution License (<http://creativecommons.org/licenses/by/4.0>), which permits unrestricted use, distribution, and reproduction in any medium, provided the original work is properly cited.