



Protective Effect of Anthocyanin on Testicular Damage and Oxidative Stress Induced by Experimental Varicocele in Adult Rats: A Histological and Biochemical Study

Ghazal Rahmanifar¹, Arash Khaki^{1*}, Afshin Teymoori¹, Arman Khatami¹, Ali Rezaii¹

Abstract

Objectives: This study aimed to investigate the potential protective impact of anthocyanin against tissue damage and oxidative stress provoked by varicocele within the testes of adult rats.

Materials and Methods: A total of 32 male rats were divided into four groups as follows: a control group undergoing a sham procedure, a varicocele group without intervention (V), a varicocele group treated with anthocyanin (VA), and a group receiving anthocyanin treatment alone. Following a 56-day treatment period, the indicators of oxidative stress were gauged in the blood plasma, while histological modifications were evaluated utilizing the hematoxylin and eosin staining technique.

Results: In the varicocele group treated with anthocyanin, we observed noteworthy enhancements in Johnsen score, epithelium thickness, and seminiferous tubule diameter compared to the untreated varicocele group. Treatment groups exhibited substantial elevations in testosterone levels and antioxidant enzyme levels. Furthermore, there was a reduction in the levels of malondialdehyde (MDA), an established marker of oxidative damage, and a decline in histological damage in the treatment groups.

Conclusions: The outcomes underscore the potential safeguarding influence of anthocyanin against testicular damage stemming from varicocele induction, suggesting its beneficial role in countering oxidative stress and tissue impairment.

Keywords: Anthocyanin, Oxidative stress, Varicocele, Testis

Introduction

Varicocele is characterized as an anomaly in the veins of the pampiniform plexus within the testis. Nevertheless, the majority of varicoceles tend to be larger in size and more frequently occur on the left side of the testis. In some individuals, varicoceles can be observed bilaterally, affecting both testicles (1). Typically, varicocele is found in approximately 15% of men, and it is recognized as one of the leading causes of male infertility. Moreover, about 35% of men experiencing primary infertility (difficulty conceiving with no previous successful pregnancies) and approximately 80% of men facing secondary infertility (difficulty conceiving after a previous successful pregnancy) have been reported to have varicocele (1).

Studies suggest that the etiology of varicocele is multifactorial. One contributing factor is the anatomical variation in venous drainage between the left and right sides of the internal spermatic vein, which leads to the predominance of left-sided varicocele. Additionally, theories commonly cited for the development of varicocele include the insufficiency of venous valves, which results in the backflow of venous blood and an increase in hydrostatic pressure, ultimately contributing to the expansion of varicocele (1,2).

In recent years, numerous studies have focused on investigating the role of hypoxia and apoptosis in elucidating the pathophysiology of varicocele. Kilinç et al reported that varicocele can induce tissue hypoxia, which is associated with various pathophysiological events, including angiogenesis. These findings suggest that the development and progression of varicocele may involve processes related to decreased oxygen supply (hypoxia) and the initiation of programmed cell death (apoptosis) (3,4). In contrast, a study by Lee et al. revealed that hypoxia in the testicular tissue of individuals with varicocele is associated with pathophysiological alterations, including the generation of reactive oxygen species (ROS). This suggests that the hypoxic condition induced by varicocele may contribute to the increased production of ROS, which are known to be harmful molecules involved in oxidative stress and cellular damage (5).

Several studies have provided evidence indicating that pre-treatment with exogenous antioxidant compounds can mitigate the tissue damage caused by oxidative stress. These studies suggest that administering antioxidants prior to the occurrence of oxidative stress can help reduce the harmful effects on tissues and cells. By neutralizing or scavenging ROS and other oxidative molecules, exogenous



Key Messages

- ▶ Varicocele led to testis tissue damage in adult rats.
- ▶ Treatment with anthocyanin improved the testis damage and oxidative stress.

antioxidants may help maintain cellular homeostasis and protect against oxidative damage (6,7). Cyanidin holds the prominent position as the predominant anthocyanin compound found in plants, constituting approximately 80% of pigmented leaves, 69% of fruits, and 50% of flowers. It assumes responsibility for the captivating shades of cornflower blue and rose red. Following cyanidin, the tandem of delphinidin and pelargonidin emerge as the subsequent prevalent anthocyanin compounds. These pigments are widely distributed across diverse plant tissues, encompassing leaves, stems, roots, flowers, and fruits. Notably, animal investigations have elucidated the rapid absorption kinetics of anthocyanins, with their appearance in the bloodstream occurring within a mere 6 to 20 minutes post-ingestion, reaching their zenith concentration within a span of 16 to 60 minutes. The concentration of anthocyanins within the plasma typically spans from nanomolar to micromolar levels, manifesting slight fluctuations (8-10).

Considering the antioxidant and anti-inflammatory properties associated with anthocyanin, the present study was conducted to assess the impact of anthocyanin on tissue damage and oxidative stress induced by varicocele in the testes of adult rats. We aimed to investigate the potential effect of anthocyanin on mitigating the negative effects caused by varicocele through its antioxidative and anti-inflammatory mechanisms.

Material and Methods

All experimental procedures in this study were approved by the Animal Ethics Committee of Islamic Azad University of Tabriz, Iran. A total of 32 healthy male Wistar rats weighing between 200 to 250 g were used. The rats were purchased from the Animal Care Center of Tabriz University of Medical Sciences, Iran. All rats were eight weeks old and acclimated for a period of two weeks with ad libitum access to food and water. They were housed in a controlled animal laboratory environment with a stable temperature of $25 \pm 2^\circ\text{C}$, humidity ranging from 30% to 70%, and a 12-hour light/12-hour dark cycle. The sample size was calculated based on the following formula, and eight rats were assigned into each group.

$$n = 1 + 2C \left(\frac{s}{d} \right)^2 = 1 + 2 * 7.85 \left(\frac{0.212}{0.556} \right)^2 \approx 4$$

$$\hat{n} = n\sqrt{g-1} = 4\sqrt{5-1} = 8$$

The rats were randomly divided into four groups as follows:

Group 1 (sham): rats subjected to laparotomy surgery without the induction of varicocele (Sham, n=8); Group

2 (varicocele): rats undergoing the induction of varicocele and receiving intraperitoneal injections of normal saline for a duration of eight weeks (varicocele n=8); Group 3 (varicocele + anthocyanin): rats undergoing the induction of varicocele and receiving intraperitoneal injections of anthocyanin (Sigma Aldrich, Germany) at a dose of 100 mg/kg for eight weeks (varicocele + anthocyanin, n=8) based on a previous study (11); and group 4 (anthocyanin): rats receiving intraperitoneal injections of anthocyanin at a dose of 100 mg/kg for eight weeks without the induction of varicocele (anthocyanin, n=8).

Surgical Procedure

General anesthesia was administered through intraperitoneal injection of xylazine at a dosage of 10 mg/kg and ketamine at a dosage of 50 mg/kg (7). During the administration of general anesthesia, the rats were positioned in a dorsal recumbent posture on a specialized rodent board. Their abdominal fur was entirely removed, followed by sterilization utilizing a 70% alcohol solution and a topical application of betadine solution. For inducing experimental varicocele, an initial 2 cm incision was made in the midsection of the abdomen. The left renal vein was identified and isolated from the adjacent tissue. A silk thread of size 0-4 was passed beneath the vein, while blunt suture needles of size 5-0 were strategically placed near the vein to create an incomplete ligature around the renal vein. Subsequently, the blunt suture needle was extracted from the ligature, leading to its loosening. This process led to a reduction in the external diameter of the vein and an augmentation of blood flow within the vein. Four weeks after the surgical intervention, the abdominal region of the rats was reopened for assessment. We observed the manifestation of varicocele indicators, including pronounced vein hyperemia, inflammatory changes, and testicular enlargement on the manipulated side. Following the confirmation of varicocele, the treatment regimen was sustained for an additional eight-week duration (3). At the culmination of the designated treatment interval, all rats within each group underwent anesthesia via a combination of ketamine and xylazine. Subsequently, the testicles were surgically extracted, and blood samples were procured from the inferior vena cava. These blood samples were acquired with the intention of evaluating the serum concentrations of antioxidant enzymes and hormones. This analysis was conducted to ascertain the influence of the treatment on these specific biochemical parameters, thereby shedding light on the prospective effects of anthocyanin on antioxidant capacity and hormone levels within the context of varicocele.

Histological and Morphometrical Evaluation of Seminiferous Tubules

For histological evaluation of the seminiferous tubules, Johnson's score was utilized. This scoring system involved examining 50 seminiferous tubules in each cross-section

of the testis tissue. Each tubule was assigned a score ranging from one to ten based on the following criteria:

- Score 10: tubules with complete spermatogenesis and a normal appearance;
- Score 9: tubules with only a few spermatogenic cells missing or abnormalities;
- Score 8: tubules with more than half of the spermatogenic cells missing or abnormalities;
- Score 7: tubules with less than half of the spermatogenic cells missing or abnormalities;
- Score 6: tubules with only a few spermatogenic cells present and severe abnormalities;
- Score 5: tubules with only a few spermatogenic cells present and moderate abnormalities;
- Score 4: tubules with only a few spermatogenic cells present and mild abnormalities;
- Score 3: tubules with only a few spermatogenic cells present and very mild abnormalities;
- Score 2: tubules with only a few spermatogenic cells present and minimal abnormalities; and
- Score 1: tubules without any spermatogenic cells.

By assigning scores based on these criteria, the histological evaluation aimed to assess the overall condition and functionality of the seminiferous tubules in the testis tissue (12).

The morphometry of seminiferous tubules involved the measurement of various parameters. Specifically, 20 cross-sections of seminiferous tubules were randomly selected on each slide for analysis. We carefully chose cross-sections that appeared as circular or nearly round in shape.

In these selected sections, two main measurements were taken. Firstly, we measured the seminiferous tubule diameter (STD). This involved determining the width of the tubule by measuring the distance across 20 different cross-sections. The aim was to obtain an accurate representation of the tubule diameter. Secondly, the height of the seminiferous epithelium (HE) was measured. This measurement involved assessing the distance from the basal membrane on one side of the tubule to the luminal edge. The purpose was to quantify the height of the epithelial layer within the seminiferous tubule. Both the diameter and height measurements were conducted using linear eyepiece grids on a light microscope at a magnification of 400x. This allowed for precise and standardized measurements to be obtained for the morphometric analysis of the seminiferous tubules (13).

Evaluation of Biochemical in the Blood Serum

Previous studies described the measurement of serum levels of malondialdehyde (MDA), superoxide dismutase (SOD), and glutathione peroxidase (GPx). Here is a summary of the measurement procedures:

Measurement of MDA

A volume of 0.20 cm³ of serum was extracted and placed

into a microtube containing 3.0 cm³ of glacial acetic acid. Subsequently, 1% Thiobarbituric acid dissolved in 2% NaOH was introduced into the microtube. The microtube was then subjected to heating in boiling water for a duration of 15 min. Following the cooling phase, the absorbance of the resultant pink-hued product was assessed at a wavelength of 532 nm utilizing a spectrophotometer apparatus (Biospect). For calibration purposes, a curve was established using MDA tetrabutylammonium salt procured from Sigma (USA).

Measurement of SOD and GPx

The concentrations of SOD and GPx were determined within the plasma utilizing an ELISA reader apparatus (Antus). This analysis adhered to the procedural guidelines stipulated within the respective kits (Randox and Ransod, UK), ensuring accuracy and consistency in the measurements (7).

Serum Testosterone Level

To obtain sera for analysis, blood samples were collected from the mice by penetrating a syringe into their hearts. The collected blood samples were then subjected to centrifugation at 3000 rpm for a duration of 10 min. This centrifugation process facilitated the separation of the sera from the other blood components. The isolated sera were carefully collected and stored in a freezer at -70 °C. The stored sera were later used for the analysis of serum testosterone levels. The concentration of testosterone in the serum was measured using commercially available ELISA kits from Demeditec Diagnostics, Germany. These ELISA kits provided a reliable and standardized method for quantifying the levels of testosterone in the serum samples.

Statistical Analysis

The statistical analysis was performed using the SPSS software version 19 (USA). All the data were presented as mean ± standard error of the mean (SEM) to provide a measure of central tendency and variability. To compare the data among different groups, one-way analysis of variance (ANOVA) was employed. Furthermore, Tukey's post hoc test was conducted to determine specific group differences. This test enabled pairwise comparisons between the groups and helped identify statistically significant differences. A significance level of $P < 0.05$ was used as the threshold for determining statistical significance.

Results

Biochemical Parameters

The varicocele and varicocele + anthocyanin groups exhibited significantly decreased serum GPx levels compared to the sham group ($P < 0.001$). The anthocyanin and varicocele + anthocyanin groups showed significantly higher serum GPx levels compared to the varicocele

group ($P < 0.001$). The varicocele group demonstrated significantly elevated serum MDA levels compared to the sham group ($P < 0.001$). The anthocyanin and varicocele + anthocyanin groups displayed significantly reduced serum MDA levels compared to the varicocele group ($P < 0.001$). The varicocele group exhibited significantly lower serum SOD levels than the sham group ($P < 0.001$). The anthocyanin and varicocele + anthocyanin groups showed significantly increased serum SOD levels compared to the varicocele group ($P < 0.001$) (Table 1).

These findings indicate that varicocele induction resulted in decreased serum levels of GPx and SOD, while increasing the MDA level and reflecting oxidative stress. However, treatment with anthocyanin, either alone or in combination with varicocele induction, effectively reversed these changes, restoring the antioxidant status and reducing oxidative stress in the testicular tissue.

Testicular Histological Parameters

The varicocele and varicocele + anthocyanin groups exhibited a significantly lower mean Johnson's score (MJS) compared to the sham group ($P = 0.001$). Treatment with anthocyanin significantly increased the MJS in the anthocyanin and varicocele + anthocyanin groups compared to the varicocele group ($P = 0.001$). However, no significant difference in MJS was observed between the anthocyanin and sham groups. The varicocele group demonstrated a marked reduction in STD compared to the sham group ($P < 0.001$). The anthocyanin and varicocele + anthocyanin groups displayed significantly higher STD than the varicocele group ($P < 0.001$). Notably, there were

no significant differences in STD between the anthocyanin and sham groups. The varicocele group exhibited a substantial decrease in HE compared to the sham group ($P < 0.001$). Treatment with anthocyanin significantly increased the HE in the anthocyanin and varicocele + anthocyanin groups compared to the varicocele group ($P < 0.001$) (Figure 1 and Table 2).

These findings indicate that varicocele induction led to histological alterations in testicular tissue, characterized by a decrease in the Johnson's score, STD, and seminiferous epithelium height. However, administration of anthocyanin effectively ameliorated these histological parameters, resulting in an increase in the Johnson's score, STD, and seminiferous epithelium height. The histological improvements observed in the anthocyanin and varicocele + anthocyanin groups suggest the potential protective effects of anthocyanin against varicocele-induced tissue damage in the rat testis.

Serum Level of Testosterone

We also investigated the serum levels of testosterone hormone in different groups. Figure 2 compares testosterone hormone levels among the groups. The results indicate that the varicocele group had a significantly lower level of testosterone hormone compared to the sham group ($P < 0.05$). However, the group with varicocele receiving anthocyanin showed a significant increase in testosterone hormone levels compared to the varicocele group ($P < 0.05$). Furthermore, the group receiving anthocyanin exhibited a significant increase in testosterone hormone levels compared to the sham group ($P < 0.05$).

Table 1. Serum Level of Oxidative Stress Markers

Groups	SOD Mean \pm SD	MDA Mean \pm SD	GPx Mean \pm SD
Sham	1.76 \pm 0.053	0.58 \pm 0.029	2.08 \pm 0.025
Varicocele	0.67 \pm 0.068 ^a	2.15 \pm 0.028 ^a	0.84 \pm 0.046 ^a
Varicocele + anthocyanin	1.28 \pm 0.043 ^b	1.48 \pm 0.026 ^b	1.60 \pm 0.064 ^b
Anthocyanin	1.75 \pm 0.033 ^b	0.49 \pm 0.021	2.15 \pm 0.022 ^b

SOD: superoxide dismutase; GPx: glutathione peroxidase; MDA: malondialdehyde; SD: standard deviation.

^a $P < 0.05$ compared to the diabetic control group.

^b $P < 0.05$ compared to the control group.

Table 2. Histopathological Findings of Testis Tissue in Study Groups

Groups	MJS Mean \pm SD	STD Mean \pm SD	HE Mean \pm SD
Sham	9.68 \pm 0.09	270.42 \pm 6.25	68 \pm 1.20
Varicocele	4.37 \pm 0.25 ^a	145.20 \pm 4.57 ^a	32.5 \pm 1.49 ^a
Varicocele + anthocyanin	6.950 \pm 0.17 ^b	192.5 \pm 4.53 ^b	55.5 \pm 2.18 ^b
Anthocyanin	9.80 \pm 0.04 ^b	274.15 \pm 5.43 ^b	70.5 \pm 2.15 ^b

MJS: mean Johnson's score; STD: seminiferous tubule diameter; HE: the height of seminiferous epithelium; SD: standard deviation.

^a $P < 0.05$ compared to the diabetic control group.

^b $P < 0.05$ compared to the control group.

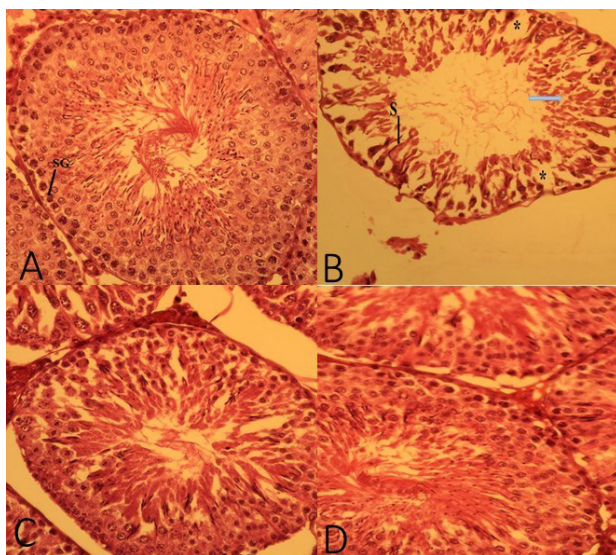


Figure 1. Histopathological findings in the study groups. A: Sham group; B: Varicocele group; C: Varicocele + Anthocyanin group; D: Anthocyanin group. S: Sertoli cell, SG: Spermatogonia.

Discussion

Varicocele is a common condition associated with male infertility, and its etiology involves various factors, including anatomical variations and venous valve inadequacy. Recent studies have focused on understanding the pathophysiology of varicocele, particularly in relation to hypoxia, oxidative stress, and apoptosis. In the present study, we evaluated the potential therapeutic effects of anthocyanin, a natural antioxidant compound, on tissue damage and oxidative stress induced by varicocele in the rat testis (14,15).

Our findings revealed significant improvements in histological parameters and hormone levels in the groups treated with anthocyanin, suggesting its potential as a protective agent against varicocele-induced testicular dysfunction. The histological assessment using Johnson's score demonstrated that varicocele induction resulted in a notable decrease in the mean score, indicating compromised testicular tissue integrity. However, treatment with anthocyanin significantly ameliorated the histological damage, as evidenced by the higher Johnson's score in the anthocyanin-treated varicocele group compared to the varicocele group alone. These results suggest the potential beneficial effect of anthocyanin on testicular tissue architecture that may help preserve normal histology.

Another important parameter assessed in our study was the diameter of seminiferous tubules, which reflects testicular function. Varicocele induction led to a significant decrease in STD, indicating impaired spermatogenesis. However, treatment with anthocyanin effectively increased the STD in both the varicocele group and the non-varicocele group receiving anthocyanin. These findings suggest that anthocyanin supplementation may contribute to the preservation or restoration of

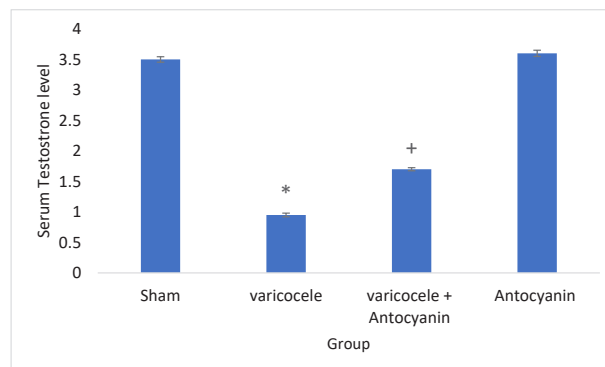


Figure 2. Comparison of Serum Levels of Testosterone Hormone in the Study Groups. Sham: group receiving normal saline; Varicocele: control varicocele group receiving normal saline; Varicocele + Anthocyanin: Varicocele group receiving Anthocyanin; Anthocyanin: Healthy group receiving Anthocyanin. * indicates significance against sham group and + indicates significance against varicocele group.

seminiferous tubule structure and function, ultimately improving testicular health and spermatogenesis (10,16).

One of the key factors contributing to varicocele-induced testicular damage is oxidative stress. Oxidative stress occurs when there is an imbalance between ROS production and the antioxidant defense system. In our study, we evaluated the levels of antioxidant enzymes, including SOD and GPx, as well as the level of MDA, a marker of lipid peroxidation and oxidative stress (17,18). Varicocele induction resulted in a significant decrease in SOD and GPx levels, indicating impaired antioxidant defense mechanisms (19, 20). However, treatment with anthocyanin restored the levels of these enzymes, suggesting its potential as an antioxidant agent in combating varicocele-induced oxidative stress (17,18). Additionally, the MDA levels were significantly increased in the varicocele group, indicating lipid peroxidation and oxidative damage. Treatment with anthocyanin significantly reduced the MDA levels, indicating its ability to attenuate lipid peroxidation and oxidative stress (21,22). The protective effects of anthocyanin against varicocele-induced testicular damage can be attributed to its antioxidant and anti-inflammatory properties. anthocyanins are potent scavengers of ROS, thereby reducing oxidative stress and its detrimental effects on testicular tissue. Moreover, anthocyanins have been shown to possess anti-inflammatory properties by inhibiting pro-inflammatory cytokines and modulating immune responses (16,23). These anti-inflammatory effects may help mitigate the inflammatory processes associated with varicocele, leading to improved testicular function (20,24).

The potential mechanisms underlying the protective effects of anthocyanin in varicocele-induced testicular damage are likely multifactorial. Anthocyanins have been reported to modulate angiogenesis and improve blood flow, which can help alleviate the hypoxic conditions associated with varicocele. Hypoxia, resulting from compromised blood flow, plays a crucial role in the pathophysiology

of varicocele and contributes to tissue damage and dysfunction. By improving blood flow and oxygen supply to the testicular tissue, anthocyanin may help mitigate the hypoxic conditions and reduce testicular damage (24,25). Furthermore, anthocyanins have been shown to regulate apoptotic pathways and inhibit cell death. Varicocele is associated with increased apoptosis in testicular tissue, leading to impaired spermatogenesis. Anthocyanin's anti-apoptotic properties may help protect testicular cells from apoptosis and preserve testicular function (24,25). Our findings are consistent with previous studies investigating the potential therapeutic effects of anthocyanin in various disease conditions. Several studies have reported the antioxidant and anti-inflammatory effects of anthocyanin in different tissues and organs, highlighting their potential as protective agents against oxidative stress-induced damage. Moreover, the beneficial effects of anthocyanin on reproductive health have been documented in various animal models, including improvements in sperm parameters, hormone levels, and testicular histology.

Limitations of the Study

In this study, we did not investigate the reproductive power of rats and the expression of proteins and genes related to apoptosis in the testicular tissue due to financial deficiencies.

Conclusion

The findings of this study provided evidence for the beneficial effects of anthocyanin in protecting against varicocele-induced testicular damage. Anthocyanin supplementation exhibited protective effects on testicular histology, seminiferous tubule morphology, and testosterone hormone levels. These results highlight the potential therapeutic application of anthocyanin in the management of varicocele-associated testicular dysfunction. However, further studies are warranted to elucidate the precise molecular mechanisms underlying the protective effects of anthocyanin and explore its potential clinical applications in the treatment of varicocele.

Authors' Contribution

Conceptualization: Arash Khaki, Ghazal Rahmanifar, Afshin Teymoori, Arman Khatami, Ali Rezaei.

Data curation: Arash Khaki, Ghazal Rahmanifar, Afshin Teymoori, Arman Khatami, Ali Rezaei.

Formal analysis: Arash Khaki, Ghazal Rahmanifar, Afshin Teymoori, Arman Khatami, Ali Rezaei.

Funding acquisition: Arash Khaki, Ghazal Rahmanifar, Afshin Teymoori, Arman Khatami, Ali Rezaei.

Investigation: Arash Khaki, Ghazal Rahmanifar, Afshin Teymoori, Arman Khatami, Ali Rezaei.

Methodology: Arash Khaki, Ghazal Rahmanifar, Afshin Teymoori, Arman Khatami, Ali Rezaei.

Project administration: Arash Khaki.

Resources: Arash Khaki.

Software: Ghazal Rahmanifar, Afshin Teymoori, Arman Khatami, Ali Rezaei.

Supervision: Arash Khaki.

Validation: Arash Khaki, Ghazal Rahmanifar, Afshin Teymoori, Arman Khatami, Ali Rezaei.

Visualization: Arash Khaki, Ghazal Rahmanifar, Afshin Teymoori, Arman Khatami, Ali Rezaei.

Writing—original draft: Arash Khaki, Ghazal Rahmanifar, Afshin Teymoori, Arman Khatami, Ali Rezaei.

Writing—review & editing: Arash Khaki, Ghazal Rahmanifar, Afshin Teymoori, Arman Khatami, Ali Rezaei.

Conflict of Interests

Authors declare that they have no conflict of interests.

Ethical Issues

This study was approved by the Animal Ethics Committee of Islamic Azad University of Tabriz, Iran (No. IR.IAU.TABRIZ.REC.1401.244).

Financial Support

Islamic Azad University of Medical Sciences, Tabriz, Iran supported the study.

Acknowledgments

We thank all the staff of Islamic Azad University of Tabriz, Iran for sincere collaboration. This research did receive any grant from any organization.

References

1. Alsaikhan B, Alrabeeh K, Delouya G, Zini A. Epidemiology of varicocele. *Asian J Androl.* 2016;18(2):179-181. doi:10.4103/1008-682x.172640
2. Buschi AJ, Harrison RB, Norman A, et al. Distended left renal vein: CT/sonographic normal variant. *AJR Am J Roentgenol.* 1980;135(2):339-342. doi:10.2214/ajr.135.2.339
3. Tek M, Cayan S, Yilmaz N, Oğuz I, Erdem E, Akbay E. The effect of vascular endothelial growth factor on spermatogenesis and apoptosis in experimentally varicocele-induced adolescent rats. *Fertil Steril.* 2009;91(5 Suppl):2247-2252. doi:10.1016/j.fertnstert.2008.06.008
4. Kiliç F, Kayaselcuk F, Aygun C, Guvel S, Egilmez T, Ozkardes H. Experimental varicocele induces hypoxia inducible factor-1 α , vascular endothelial growth factor expression and angiogenesis in the rat testis. *J Urol.* 2004;172(3):1188-1191. doi:10.1097/01.ju.0000135455.97627.15
5. Lee JD, Jeng SY, Lee TH. Increased expression of hypoxia-inducible factor-1 α in the internal spermatic vein of patients with varicocele. *J Urol.* 2006;175(3 Pt 1):1045-1048. doi:10.1016/s0022-5347(05)00417-9
6. Moghimian M, Abtahi-Evari SH, Shokoohi M, Amiri M, Soltani M. Effect of *Syzygium aromaticum* (clove) extract on seminiferous tubules and oxidative stress after testicular torsion in adult rats. *Physiol Pharmacol.* 2017;21(4):343-350.
7. Soltani M, Moghimian M, Abtahi-Eivari SH, Shoorei H, Khaki A, Shokoohi M. Protective effects of *Matricaria chamomilla* extract on torsion/detorsion-induced tissue damage and oxidative stress in adult rat testis. *Int J Fertil Steril.* 2018;12(3):242-248. doi:10.22074/ijfs.2018.5324
8. Wallace TC, Giusti MM. Anthocyanins. *Adv Nutr.* 2015;6(5):620-622. doi:10.3945/an.115.009233
9. Castañeda-Ovando A, de Lourdes Pacheco-Hernández M, Páez-Hernández ME, Rodríguez JA, Galán-Vidal CA. Chemical studies of anthocyanins: a review. *Food Chem.* 2009;113(4):859-871. doi:10.1016/j.foodchem.2008.09.001
10. Cai D, Li X, Xu Q, et al. Cyanidin-3-O-glucoside and protocatechuic acid alleviate heat stress-induced testicular damage. *Food Funct.* 2023;14(4):2200-2211. doi:10.1039/d2fo03423a
11. Hozayen WG. Effect of hesperidin and rutin on doxorubicin induced testicular toxicity in male rats. *Int J Food Nutr Sci.* 2012;1(1):31-42.
12. Johnsen SG. Testicular biopsy score count—a method for registration of spermatogenesis in human testes: normal values

- and results in 335 hypogonadal males. *Hormones*. 1970;1(1):2-25. doi:10.1159/000178170
13. Wilhelm Filho D, Torres MA, Bordin AL, Crezcynski-Pasa TB, Boveris A. Spermatic cord torsion, reactive oxygen and nitrogen species and ischemia-reperfusion injury. *Mol Aspects Med*. 2004;25(1-2):199-210. doi:10.1016/j.mam.2004.02.020
 14. Shokoohi M, Khaki A, Shoorei H, Khaki AA, Moghimian M, Abtahi-Eivary SH. Hesperidin attenuated apoptotic-related genes in testicle of a male rat model of varicocele. *Andrology*. 2020;8(1):249-258. doi:10.1111/andr.12681
 15. Shokoohi M, Khaki A, Roudi Rasht Abadi A, et al. Minocycline can reduce testicular apoptosis related to varicocele in male rats. *Andrologia*. 2022;54(4):e14375. doi:10.1111/and.14375
 16. Ekinci Akdemir FN, Yildirim S, Kandemir FM, et al. The antiapoptotic and antioxidant effects of eugenol against cisplatin-induced testicular damage in the experimental model. *Andrologia*. 2019;51(9):e13353. doi:10.1111/and.13353
 17. Dolatkah MA, Khezri S, Shokoohi M, Alihemmati A. The effect of *Fumaria parviflora* on the expression of sexual hormones along with their receptors in testicles of adult rats induced by varicocele. *Andrologia*. 2022;54(9):e14512. doi:10.1111/and.14512
 18. Dolatkah MA, Shokoohi M, Charvandeh S, et al. *Fumaria parviflora* regulates oxidative stress and apoptosis gene expression in the rat model of varicocele induction. *Andrologia*. 2020;52(11):e13826. doi:10.1111/and.13826
 19. Hamza RZ, Diab AEA. Testicular protective and antioxidant effects of selenium nanoparticles on monosodium glutamate-induced testicular structure alterations in male mice. *Toxicol Rep*. 2020;7:254-260. doi:10.1016/j.toxrep.2020.01.012
 20. Ahmadi N, Khaki AA, Khodarahmi P, Baharara J, Zakerbostanabadi S. Effect of anthocyanin on oxidative stress and testis structure in streptozotocin-induced diabetic rats. *Crescent J Med Biol Sci*. 2023;10(2):56-60. doi:10.34172/cjmb.2023.09
 21. Shoorei H, Khaki A, Khaki AA, Ali Hemmati A, Moghimian M, Shokoohi M. The ameliorative effect of carvacrol on oxidative stress and germ cell apoptosis in testicular tissue of adult diabetic rats. *Biomed Pharmacother*. 2019;111:568-578. doi:10.1016/j.biopha.2018.12.054
 22. Shoorei H, Khaki A, Shokoohi M, et al. Evaluation of carvacrol on pituitary and sexual hormones and their receptors in the testicle of male diabetic rats. *Hum Exp Toxicol*. 2020;39(8):1019-1030. doi:10.1177/0960327120909525
 23. Jang H, Kim SJ, Yuk SM, et al. Effects of anthocyanin extracted from black soybean seed coat on spermatogenesis in a rat varicocele-induced model. *Reprod Fertil Dev*. 2012;24(5):649-655. doi:10.1071/rd11174
 24. Zhou L, Zhang C, Qiang Y, et al. Anthocyanin from purple sweet potato attenuates lead-induced reproductive toxicity mediated by JNK signaling pathway in male mice. *Ecotoxicol Environ Saf*. 2021;224:112683. doi:10.1016/j.ecoenv.2021.112683
 25. Gad FA, Farouk SM, Emam MA. Antiapoptotic and antioxidant capacity of phytochemicals from Roselle (*Hibiscus sabdariffa*) and their potential effects on monosodium glutamate-induced testicular damage in rat. *Environ Sci Pollut Res Int*. 2021;28(2):2379-2390. doi:10.1007/s11356-020-10674-7

© 2024 The Author(s); This is an open-access article distributed under the terms of the Creative Commons Attribution License (<http://creativecommons.org/licenses/by/4.0>), which permits unrestricted use, distribution, and reproduction in any medium, provided the original work is properly cited.