



A Case Report of Treating Femur Head Necrosis Applying Persian-Medicine

Maryam Navabzadeh¹, Mojtaba Abdi², Javad Hadinia³, Roshanak Ghods^{4*}

Abstract

The avascular necrosis (AVN) of the femur head due to the death of the osteocytes of the bone marrow occurs because the organ is not supplied with sufficient blood. The prevalence of the problem is 10%-50% in adults. The etiology of the disease includes various factors such as trauma, cigarette smoking, drinking spirits, taking corticosteroids, genetics, metabolic disorders, human immunodeficiency virus, pregnancy, and the like. The treatment of necrosis can be conducted regarding the degree of the problem. In the present paper, a case was reported whose femur head necrosis was treated by applying Iranian Medicine without using common drugs in modern Medicine. The patient was a 46-year-old man who had felt severe pain in his left hip since a month before referring. The pain had gradually increased and the AVN of the femur head was diagnosed after magnetic resonance imaging. Finally, the surgery and arthroplasty of the femur head were recommended in this regard. In general, surgery and arthroplasty were recommended regarding the hard medicinal and complicated treatment of the AVN of the femur head. However, it is noteworthy that applying Iranian medicine capacities is possible for curing the disease.

Keywords: Treatment, Avascular necrosis, Femur head, Persian medicine, Case report

Introduction

Femur avascular necrosis (AVN) occurs due to bone marrow osteocyte death receiving insufficient blood (1-4). Approximately 10 000-20 000 cases are annually diagnosed in the USA about 75% of whom are in the age range of 30-60 years (5). Its prevalence in adults is 10%-50% (6). Its etiology includes various factors such as trauma, smoking, spirits (alcoholic drinks), corticosteroids, genetics, metabolic diseases, hemoglobinopathies, coagulative complications, myeloproliferative disorders, chemical treatment, radiation, transplants, human immunodeficiency virus, pregnancy, and the like (7, 8). Ficot believes the disorder has various stages. The first one is highly weak and asymptomatic and cannot be diagnosed through radiography. A decrease in absorbing minerals is observed only in the bone scan. The second stage includes sclerotic or cystic damages together with weak-moderate clinical symptoms. It has two subdivisions in simple radiography. The femur head has no changes but its density represents a change and the global shape of the femur head has changed into a crescent sign. The third stage encompasses the leveling of the femur head accompanied by moderate-severe clinical symptoms. In this stage, the bone scan shows an increase in the absorption of minerals and the collapse of the bone reveals as well. In the fourth stage, severe pain occurs due

to a decrease in osteoarthritis plus joint cavity, leading to the collapse of the joint. On the other hand, the bone scan reveals an increase in the absorption of minerals, and in addition to the femoral head, the acetabulum is involved (9).

The present paper introduced a case with the necrosis of the femur head cured using only Persian medicine (PM) principles. PM is a worthwhile comprehensive scientific and fundamental school considering human temperament and the four humors “blood”, “yellow bile/choler”, “phlegm”, and “black bile/melancholy” (10). Changes in the temperament and the quality of the humors are the basic causes of any diseases, and thus the improvement of a patient’s temperament is the main necessity (11).

Case Report

The case was a 46-year-old man who had felt severe pain in the left side of his hip since a month before referring (i.e., the beginning of autumn 2015). The pain had gradually increased, and after magnetic resonance imaging (MRI) in Birjand Valli-e-asr hospital on August 13, 2015, it was diagnosed that he was suffering from AVN. He was recommended to undergo surgery to change the femur head.

When referring to the health center, the case was unable to walk without the aid of another person and used a stick.

Received 10 January 2019, Accepted 10 April 2019, Available online 5 July 2019

¹Cardiovascular Diseases Research Center, Birjand University of Medical Sciences, Birjand, Iran. ²Student Research Committee, Iran University of Medical Sciences, Tehran, Iran. ³Bu-Ali Hospital, Birjand, Iran. ⁴Department of Persian Medicine, Research Institute for Islamic and Complementary Medicine, School of Persian Medicine, Iran University of Medical Sciences, Tehran, Iran.

*Corresponding Author: Roshanak Ghods, Tel: +98-55639724, Email: ghods.r@iums.ac.ir



His right femur joint had limited mobilization and he took short steps. He was thin (48 kg) and with no history of anemia.

According to some PM sources such as “Zakhireh-e-Kharazmshahi”, “Eksir-e-Azam”, and “Avicenna’s Cannon”, it was diagnosed that the case suffered the disorder of blood flow and the concentration of abnormal black bile (abnormal *Sauda*) in the hip area and the head of the femur. The patient was administered 14 massage sessions every other day, “*Monzej- e-Sauda*” or a medicine that modifies the consistency of the black bile and renders it fit for expulsion, and *Sekanjabin-e-Bazoori/Bazoori oxymel* (a syrup composed of vinegar and honey with some kinds of herbal seeds) and “*Mos-hel*” (Laxative drug). The method of massage was Iranian massage. *Gluteus maximus* muscle and *quadriceps* muscle were stretched with the hand toward the pelvic for 15 minutes. Further, rubbing the same area with the sesame oil was done two times every day. Gradually and during massaging sessions, the patient’s pain and his mobilization limitation demonstrated a decrease. The phlebotomy of the left *basilic* vein (*Fasd*) and the right *basilic* vein was done after 2 and 4 weeks, respectively. The case’s pain entirely disappeared after the second phlebotomy. Two months later (i.e., on October 16, 2015), MRI and bone scan were again done, and it was reported that femur necrosis was repaired. After 2 years, the patient has no problems and is now living a healthy life (Table 1).

Clinical and Paraclinical Findings

Before and after the treatment MRI and the bone scan after the treatment by means of the Persian medicine are shown in Figures 1-3.

Discussion

The AVN of the femur head can occur at various degrees. The more developed the problem, the more extensive and severe is the intervention. Therefore, preventing the progression of the disorder is of great significance (12). Treatment is done in two ways as follows:

Preventive measures are recommended in the beginning of necrosis, including the restriction of weight-bearing, taking drugs, and receiving physiotherapy. The active treatments are advised in stage two or later stages of the disorder, encompassing decreasing the central pressure of the femur head, osteotomy, bone transplants, and arthroplasty (13,14).

PM holds that joint pain is due to the concentration of thick and heavy humors in an area. The reason for the problem can be “*Imtila*” (the fullness of the body with fluids and the accumulation of normal or abnormal fluids in the body), malnutrition, recurring trauma, taking humor thickening drugs, descending of the black bile into an area, an organ weakness, long and persistent coldness of an environment, consuming continuous cold temperament

Table 1. Treatment Course

Measures	Time
Administering <i>monzej</i> (coctive agent), <i>ekanjabin-e-Bazoori</i> , and <i>mos-hel</i> drugs (laxatives)	The beginning stage
Fourteen massaging sessions	Every other day
<i>Fasd</i> of the left basilica	On the 15 th day
<i>Fasd</i> of the right basilica	On the 30 th day

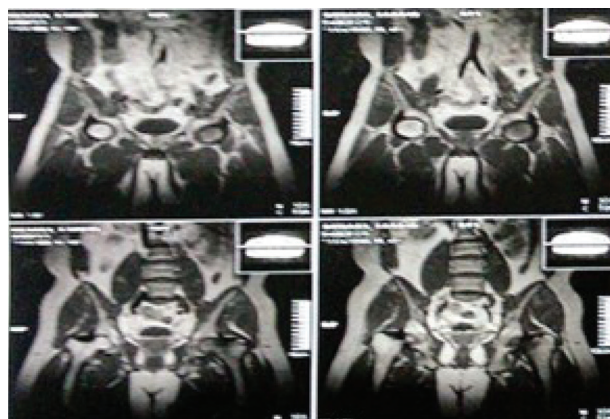


Figure 1. MRI Before the Start of the Treatment.

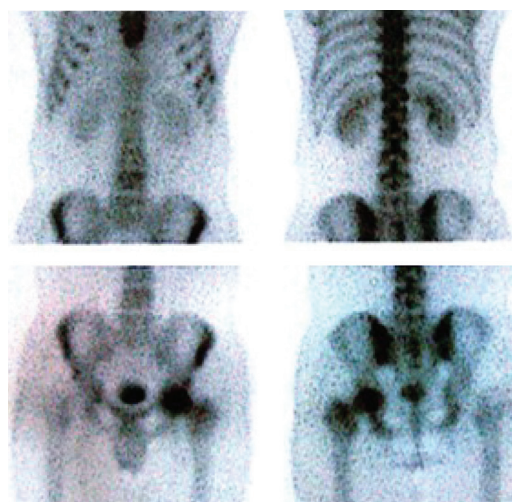


Figure 2. Nuclear Radiographic Scan After the Treatment.

foods, and hereditary. In this regard, treatment includes removing “*Imtila*”, the expulsion of pathogenic humor from the blood (particularly melancholy), improving blood circulation, proper oxygenation of the area, and improving the temperament (15-18).

In PM, the general trend of treatment is based on the existence of the four humors in a man, and the thick humor causing the blockage must be removed whenever a blockage occurs in an area of the body (19). According to medicine, bone necrosis is the result of a venous blockage. It is possible that blood supply to a specific organ or

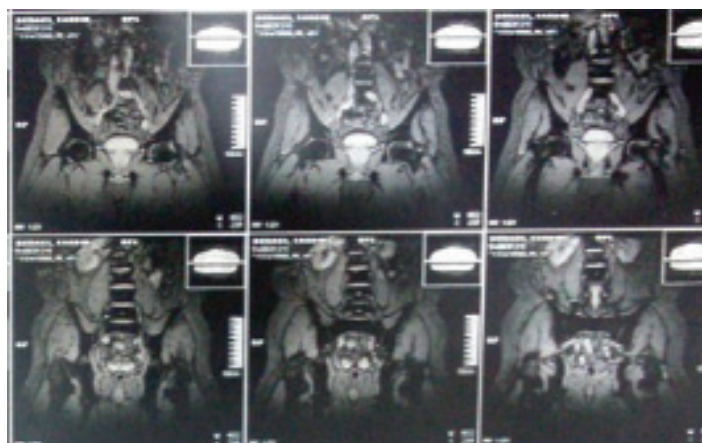

Figure 3. MRI Image After the Treatment. Note. MRI: Magnetic resonance imaging.

bone is disrupted for some reason. This can be similar to some kinds of gangrene since their clinical symptoms are somehow similar. The primary treatment of the disorder in traditional medicine is phlebotomy aiming at the quick decrease of the disrupting substance or humor and then massaging. Iranian traditional medicine holds that massaging has various favorable effects in the improvement of blood supplying to a specific organ (20). In a study by Amini et al, it was found that *Fasd* (phlebotomy) is as an effective method for the treatment of articulation pains and sciatica (18). The obtained results from previous studies confirmed the positive effect of *Fasd* on the musculoskeletal disease (21, 22).

With regard to the mentioned case, laxative drugs were administered in addition to massaging traditional diluting and removing the intruding abnormal humor. In the PM, "nozj" refers to a process in which thick and intruding substances are diluted and prepared for removal from the body (23). Hopefully, necrosis progress would stop and the recovery process would improve with the improvement of blood supply to a specific organ and as a result of its oxygenation.

Therefore, the current study is more certainly suggests the method for similar cases. With regard to the favorable result of the recent treatment, it is possible to carry out various studies in the future (e.g., pilot and clinical trial studies).

Limitations

Patients with similar problems and acute conditions usually refer to modern medicine and are particularly advised to undergo surgery and rarely come to PM clinics for treatment. This limits enough number of patients for evaluation with this new method.

Conclusions

Regarding the severity and complication developing the medicinal treatment of the vascular necrosis of the femur head that leads to arthroplasty and surgery, it is advisable

to consider the capacity of PM in treating the disease, along with modern medicine.

Authors' Contribution

The case was treated by MN and JH. RG and MA helped prepare and set up the manuscript and review texts. All authors read and approved the final manuscript.

Conflict of Interests

All the authors declare that they have no conflict of interests.

Ethical Issues

All stages of the study were based on the latest version of the Declaration of Helsinki, and written consent was obtained from the patient.

Financial Support

None declared.

Acknowledgments

Thanks are due to all those who diagnosed the patient's problem, took care of him, and treated him..

References

1. Malizos KN, Karantanas AH, Varitimidis SE, Dailiana ZH, Bargiotas K, Maris T. Osteonecrosis of the femoral head: etiology, imaging and treatment. *Eur J Radiol.* 2007;63(1):16-28. doi:10.1016/j.ejrad.2007.03.019
2. Zibis AH, Karantanas AH, Roidis NT, et al. The role of MR imaging in staging femoral head osteonecrosis. *Eur J Radiol.* 2007;63(1):3-9. doi:10.1016/j.ejrad.2007.03.029
3. Bassounas AE, Karantanas AH, Fotiadis DI, Malizos KN. Femoral head osteonecrosis: volumetric MRI assessment and outcome. *Eur J Radiol.* 2007;63(1):10-15. doi:10.1016/j.ejrad.2007.03.028
4. Kaushik AP, Das A, Cui Q. Osteonecrosis of the femoral head: an update in year 2012. *World J Orthop.* 2012;3(5):49-57. doi:10.5312/wjo.v3.i5.49
5. Pouya F, Kerachian MA. Avascular necrosis of the femoral head: are any genes involved? *Arch Bone Jt Surg.* 2015;3(3):149-155.
6. Al-Tonbary Y, Tricta F, El-Beshlawy A, Badr MA, Mansour A. Updates in hemoglobinopathies. *ScientificWorldJournal.* 2013;2013:912913. doi:10.1155/2013/912913
7. Babis GC, Sakellariou V, Parvizi J, Soucacos P. Osteonecrosis of the femoral head. *Orthopedics.* 2011;34(1):39. doi:10.3928/01477447-20101123-19

8. Lee MS, Hsieh PH, Shih CH, Wang CJ. Non-traumatic osteonecrosis of the femoral head-from clinical to bench. *Chang Gung Med J*. 2010;33(4):351-360.
9. van der Jagt D, Mokete L, Pietrzak J, Zalavras CG, Lieberman JR. Osteonecrosis of the femoral head: evaluation and treatment. *J Am Acad Orthop Surg*. 2015;23(2):69-70. doi:10.5435/jaas-d-14-00431
10. Kordafshari GR, Esmaeili S. Nutrition in Persian Islamic Medicine. Tehran: Nasle Nikan Press; 2014. [Persian].
11. Mohammadi Kenari H, Kordafshari G, Moghimi M, et al. Treatment of hypothyroidism (Hashimoto's thyroiditis) in Persian medicine: a case report. *Journal of Islamic and Iranian Traditional Medicine*. 2018;9(2):103-107.
12. Mont MA, Cherian JJ, Sierra RJ, Jones LC, Lieberman JR. Nontraumatic Osteonecrosis of the femoral head: where do we stand today? a ten-year update. *J Bone Joint Surg Am*. 2015;97(19):1604-1627. doi:10.2106/jbjs.o.00071
13. Cao H, Guan H, Lai Y, Qin L, Wang X. Review of various treatment options and potential therapies for osteonecrosis of the femoral head. *J Orthop Translat*. 2016;4:57-70. doi:10.1016/j.jot.2015.09.005
14. Mont MA, Jones LC, Hungerford DS. Nontraumatic osteonecrosis of the femoral head: ten years later. *J Bone Joint Surg Am*. 2006;88(5):1117-1132. doi:10.2106/jbjs.e.01041
15. Aghili Shirazi M. *Khulasah al-Hikmah*. Qom: Esmā'ilian Publications; 2006.
16. Arzani M. *Tebe Akbari [Akbari's Medicine]*. Institute E-eT-eT, editor. Qom: Jalaleddin; 2008.
17. Avicenna. *The Canon of Medicine*. Tehran: AlMayi; 2014.
18. Amini MH, Esmaeili SS, Mehdi Barzi D, Gholami Fesharaki M. The effect of FASD (blood-letting) in the treatment of sciatica: a randomized clinical trial study. *Ann Med Health Sci Res*. 2018;8:391-396.
19. A'zam Khan M. *Exir e A'zam (Great elixir)*. Tehran: Institute of Medicine Historical Studies, Islamic and Complementary Medicine; 2008:476-477.
20. Jorjani I. *Zakhireh-i Kharazmshahi (Treasure dedicated to the king of Khwarazm)*. Qom: Ehya'e Tebe Tabi'I Institute; 2012.
21. Jiang G, Jia C, Lin M. Effect of bloodletting therapy at local myofascial trigger points and acupuncture at Jiaji (EX-B 2) points on upper back myofascial pain syndrome: a randomized controlled trial. *J Tradit Chin Med*. 2016;36(1):26-31. doi:10.1016/s0254-6272(16)30004-8
22. Chang XR, Feng YS, Yi SX, Zeng XB, Lin YP. [Effects of pricking bleeding at "Weizhong" (BL40) on sciatic nerve conduction velocity and interleukin-1alpha content in the lumbar vertebral nucleus pulposus in experimental lumbar intervertebral disc protrusion rabbits]. *Zhen Ci Yan Jiu*. 2007;32(5):319-322.
23. Alizadeh-Vaghasloo M, Zareian MA, Ali-Soroushzadeh SM. The concept of Nozj. *Trad Integr Med*. 2016;1(4):133-135.

Copyright © 2022 The Author(s); This is an open-access article distributed under the terms of the Creative Commons Attribution License (<http://creativecommons.org/licenses/by/4.0>), which permits unrestricted use, distribution, and reproduction in any medium, provided the original work is properly cited.