



The Study of Silicon Shoes Insert Benefits in Symptom and Radiology of Patients With Idiopathic Femoral Head Osteonecrosis: Two Arms Randomized Controlled Trial

Alireza Sadeghpour¹, Hossein Aslani¹, Morteza Gojazadeh¹, Mahdi Pashazadeh^{1*}

Abstract

Objectives: C Femoral head osteonecrosis is one of the most common orthopedic diseases in which the exact etiology is unknown and has no specific treatment. This study was designed and with the theory of stopping the disease or at least showing down the progression of the disease and reducing the pain of patients with femoral head idiopathic osteonecrosis (ION).

Materials and Methods: This study was designed as a randomized clinical trial in which two control and interventional groups with a shoe insert were compared over a period of one year. The shoe insert was made of silicone gel and leather carbide with a thickness of one cm on the heel which gradually reduced until paw and was used at both feet. The study was considered to be meaningful with $P < 0.05$.

Results: A total of seven out of 14 patients were included in every group. They were followed up on a 4-time basis every 3 months and for 1 year. Harris Hip Score (HHS) and Ficat forms were completed for everyone. Despite the clinical satisfaction of the patients regarding the use of the shoe insert, HHS was not meaningful in their viewpoints. The progression of the disease was based on the Ficat form and according to $P < 0.003$ although it was mildly meaningful and showed down the progression of femoral head ION in patients who used a shoe insert in the intervention group.

Conclusions: Although shoes insert clinically controlled pain in patients, it was not significant in data analysis. Finally, the use of shoe inserts could help slow down the progression of the ION femoral head.

Keywords: ION of the femoral head, HHS, Ficat, Shoe insert, Osteoarthritis

Introduction

Osteonecrosis of the femoral head is considered as a relatively common disease in orthopedic. The exact etiology of this disease is unclear and for whatever reason, the femur head has a picture of a blood disorder, it is suggested to fall (1). Several etiologies are described for femoral head osteonecrosis. It may have traumatic or non-traumatic causes (2). Non-traumatic causes can be due to several factors such as autoimmune diseases, alcohol consumption (3), caisson, coagulation disorders, hip infections, pancreatitis, anemia, tuberculosis (3), lupus, AIDS (4), and the use of some drugs such as corticosteroids (5) and bisphosphonates. These factors can affect the blood flow to the femoral head, leading to small fractures and the collapse of the femoral head and degenerative changes (1-7). The traumatic etiology of the femoral head osteonecrosis may include femoral neck fractures in the sub-capital, transcervical and femoral neck fractures. The greater distance between the fractures than the neck base increases the risk of developing avascular necrosis (AVN) in the femoral head (7).

Idiopathic femoral head osteonecrosis is one of the non-traumatic causes of the AVN of the femoral head (8), which mainly affects between 30 and 60 years of age

and accounts for about 5 to 18% of total hip arthroplasty (THA) cases of this age (9,10)

The idiopathic osteonecrosis (ION) of femoral head has various surgical and non-surgical treatments (11,12), which can be used in non-surgical procedures, decrease the pressure on the femoral head with the mechanism of preventing weighing on the affected limb using the cane, as well as physical therapy measures to increase the complement range of motion and muscle strength (13,14). The purpose of all of the above-mentioned measures is to prevent the collapse of the femoral head, namely, the joint collapse that causes degenerative changes in the joint (14).

The progression of AVN of the femoral head is unpredictable and the radiographic finding may not match clinical indications. In the early stages, the patient may only be in pain when weighing on the limb, and therefore, the removal of the cane is recommended for patients to control the pain and prevent the collapse of the femoral head, but most patients do not like the form of the cane, and they do not cooperate in this regard (11,15). One of the actions that seems logical in this theory is the use of shoe insert and orthopedic shoes to absorb the return forces from the ground during weight-bearing, which could reduce the pressure on the joint and the clinical symptoms.



It is advisable to prevent the progression of the disease (16,17). According to Aoyama et al study (18), using the shoe insert is recommended in some medical conditions, including knee joint osteoarthritis (OA). Considering the lack of an accurate study in this regard, the present study was designed and implemented to investigate the results of using a shoe insert in adult patients with femoral head ION. To this end, the clinical symptoms of patients were evaluated by comparing the Harris Hip Score (HHS) and the degree of the progression of the radiographic symptoms of the disease according to Ficat classification. So far, no effective treatment has been suggested to slow the progression of the femoral head osteonecrosis from subchondral collapse and the prevention of the OA of the hip. Thus, the present study aimed to evaluate the effect of shoe insert treatment on femoral head ION patients in order to prevent the progression of clinical symptoms and radiographic changes in the disease so that to prevent disease progression and delay the need for THA.

Materials and Methods

This study was designed as a two-arm randomized single-blind clinical trial with a parallel-group based on previous studies in knee OA and Charcot Marie tooth disease and the positive effect of medical insole on these diseases (Figure 1). All patients referred to the hip clinic of Tabriz Shohada hospital from November 2017 to May 2018 and diagnosed with AVN of the femoral head were invited to participate in the study. These patients did not want to have Core Decompression and their disease was in its early stages (Ficat I, II). Although the use of shoe inserts is a safe method, informed consent was obtained from all patients for their participation in the study. After

the approval of the ethical committee and considering ethical considerations and the secrecy of the patients, more patients were referred to the hip clinic and inclined to undergo a surgery or were in the higher stages of the disease (Ficat 3 or 4). A total of 14 patients reported their willingness to participate in this study. The inclusion criteria were patients who had no previous history of surgery on the hip joint and were not willing to undergo core decompression for femoral head osteonecrosis. In addition, the patients would be excluded if they wished to discontinue treatment or needed surgery during the study.

All 14 patients in the study were randomly divided into intervention and control (without prescription) groups (7 in each group) by Rand list 1.2 software, the details of which are provided in Tables 1 and 2. For patients in the intervention group, a silicone shoe insert with the leather dress was prescribed with a skin-resistant method to prevent foot sweating, designed for every patient individually in a digital form. The used shoe insert was inserted bilaterally into both shoes. None of the patients was aware of the prescription of the shoe insert and thus were based on the standard radiographic changes of the disease and standard scans. However, the researchers required no blinding.

The heel of the shoe insert was 1 cm thick, which gradually reduced to the thickness until the toes. Patients were advised to use full-time suppositories and were followed up for a period of one year and at intervals of three months. Further, the HHS form was completed and after radiologic procedure Ficat form was completed each time they referred for a visit. The HHS standard forms could provide health and hygiene resources regarding using protective equipment by means of transportation

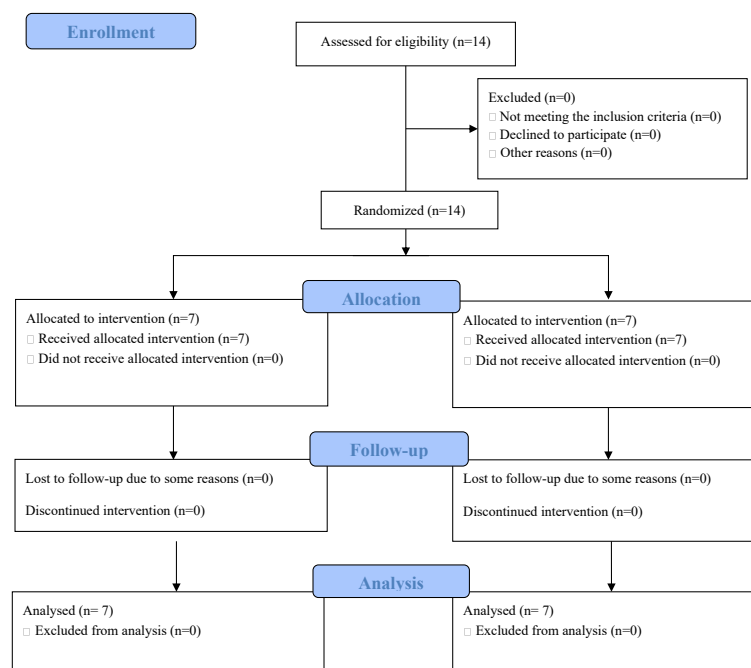


Figure 1. CONSORT Flow Diagram.

Table 1. Intervention Group With Shoe Inserts

Background Illness	Age	Gender	Form	Turn to Visit			
				First	Second	Third	Last
MS	25	Female	HHS	63	66	72	75
			Ficat	2	2	2	2
To became obese	32	Male	HHS	65	69	79	81
			Ficat	2	2	2	2
To became obese	27	Male	HHS	59	58	56	55
			Ficat	2	2	2	2
SLE	23	Female	HHS	76	76	79	82
			Ficat	2	2	2	2
Pregnancy	19	Female	HHS	52	58	69	72
			Ficat	2	2	2	2
SLE	37	Female	HHS	55	56	59	61
			Ficat	2	2	2	2
LBP	45	Male	HHS	74	77	77	79
			Ficat	2	2	2	2

Note. MS: Multiple sclerosis; SLE: Systemic lupus erythematosus; LBP: Low back pain; HHS: Harris hip score.

Table 2. Control Group Without Shoe Inserts

Background Illness	Age	Gender	Form	Turn to Visit			
				First	Second	Third	Last
To became obese	24	Male	HHS	87	77	72	68
			Ficat	1	1	1	2
RA	17	Female	HHS	77	75	75	73
			Ficat	2	2	2	2
To became obese	17	Female	HHS	74	72	68	65
			Ficat	2	2	2	2
Liver transplantation	31	Male	HHS	72	59	51	47
			Ficat	2	2	3	3
Kidney transplantation	29	Male	HHS	61	59	55	51
			Ficat	2	2	2	2
SLE	27	Female	HHS	61	60	55	52
			Ficat	2	2	2	2
LBP	45	Male	HHS	80	72	62	56
			Ficat	2	2	2	2

Note. RA: Rheumatoid arthritis; SLE: Systemic lupus erythematosus; LBP: Low back pain; HHS: Harris hip score

and public transport, as well as raising the opportunity of the stairs, the ability to hold shoes and socks, and finally, the deformities and degrees of hip joint mobility. The standard forms of Ficat also relate to the radiological classification of patients with femoral head AVN. It is emphasized that the value of the X-ray in tracking patients with AVN is even equivalent to arthroscopy. After completing the research and the HHS and Ficat forms for 14 studied patients, the chi-square statistical test was used to investigate the relationship between Ficat qualitative variables and independent samples *t* test. Furthermore, repeated measures ANOVA and Friedman were utilized to evaluate the relationship between quantitative HHS variables by SPSS 22 and *P* value <0.05 was considered statistically meaningful. Eventually, the regression models were used to study the effects of confounding variables such as weight, underlying diseases, and drug use in the 2 study groups.

Results

Of 14 patients in the study, 7 cases were males and 7 were females. They were randomly divided into control (4 males and 3 females) and intervention (3 males and 4 females) groups. The mean age of the patients was 27.14 and 29.14 in the control and intervention groups, respectively. The mean age of 14 patients was 28.14 ± 0.05 years (Table 3).

The factors that led to the creation of ION for the femoral head were: corticosteroids which were administered to 4 patients due to rheumatologic diseases such as lupus and rheumatoid arthritis, and arbitrary corticosteroids which were administered to 4 people in order to become obese. In addition, someone looked for pregnancy and 2 people took corticosteroids after kidney and liver transplantation. Further, one person suffered from MS and 2 people received corticosteroids for the treatment of low back pain (Table 4).

The 2 groups of this study were compared in terms of

Table 3. Age Range

Age	Frequency	Percent
11-20	3	21.4
21-30	6	42.9
31-40	3	21.4
Up 40	2	14.3
Total	14	100.0

Table 4. Cause of Femur Head Idiopathic Osteonecrosis

Causes	Frequency	Percent
Rheumatologic diseases	4	28.6
For obesity	5	35.7
Organ transplantation	2	14.3
Multiple sclerosis	1	7.1
Back ache	2	14.3
Total	14	100.0

Table 5. Comparison of HHS and Ficat in 2 Control and Intervention Groups During 1-year Follow-up

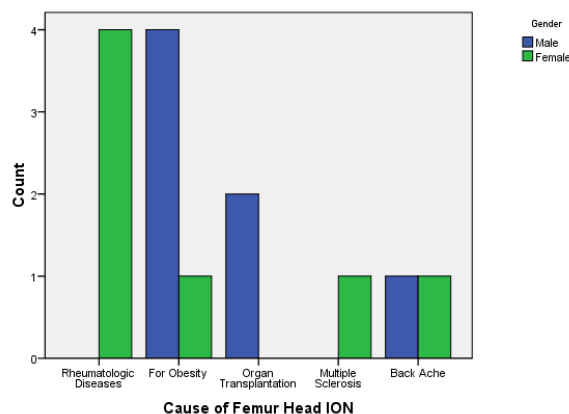
	Group	N	Mean	SD	P Value
HHS in 1st turn	Without	7	73.14	9.582	0.943
	With	7	63.43	9.071	
HHS in 2nd turn	Without	7	67.71	8.036	0.99
	With	7	65.71	8.731	
HHS in 3th turn	Without	7	62.57	9.325	0.918
	With	7	70.14	9.424	
HHS in 4th turn	Without	7	58.86	9.822	0.912
	With	7	72.14	10.399	
HHS	Without	7	262.29	34.403	0.987
	With	7	271.43	35.265	
Ficat	Without	7	7.29	2.059	0.003
	With	7	8.00	0.000	

Note. HHS: Harris hip score; SD, standard deviation.

*P values calculated with repeated measurement of ANOVA test.

the mean age and sex using independent *t* test, and Fisher exact test, which were 0.919 and 0.265 for the randomized division of patients according to the P values, respectively. Based on the results, no significant difference was found between the 2 groups in this regard. HHS and Ficat were completed for each member of each visit. The obtained data were then compared with each other as the frequency of the referrals and at the end of the one-year period.

Mean HHS scores for the first, second, and third times with P values ($P = 0.943$, $P = 0.99$, and $P = 0.918$) did not show any significant difference between the 2 groups. As regards the pain severity, the mean total of 4 periods of the referral and follow-up of the patients over a period of one year was 262.20 ± 34.44 and 271.43 ± 26.21 in control and intervention groups based on their average HHS score,

**Figure 1.** Causes of Femoral Head ION With Gender.

respectively. Patients in the intervention group using shoe insert were satisfied clinically and they declare to reduce their pain and increase individual ability, but it was not statistically meaningful, ($P = 0.987$; independent *t* test). All patients in the intervention group on radiological evidence and Ficat classification were in group II and no changes were observed in their disease stage during one year of follow-up. However, at the beginning of the study, 5 and 2 patients were in groups II and I in the control group, respectively. In the final stage of patient follow-up, a patient progressed from stage II to stage III and one patient was also changed from stage I to stage II.

Finally, radiographic changes showed a slight difference ($P = 0.003$) based on the stage of the disease in Ficat classification, which is statistically meaningful and could be a sign of the progression of the femoral head ION disease in the case of using a shoe insert (Table 5, Figure 2).

Using the paired sample *t* test, changes in disease stage at the final visit compared to the first, second, and third times demonstrated no significant differences with respect to P values of 0.478, 0.635, and 0.339.

Discussion

The ION of the femoral head is one of the most common orthopedic diseases. In the early stages of the disease, pain and movement restriction are disabling for patients and no definitive treatment is yet known to prevent the progression of this disease. Thus, this study was designed and implemented to delve into the issue. The use of a shoe insert inside the patient's shoes with the hypothesis of preventing shock and shock transfer from the hip joint seems to be logical in theory. Therefore, it can be useful since it is often recommended that the limb should not be weighed to prevent the collapse of the femoral head (11-15). Papalia et al in their systematic study examined the effects of orthopedic shoes and found that orthopedic shoes have a profound effect on muscle recruitment and electrographic activity and can help prevent degenerative changes in the hip joint and the lumbar plays an effective

role in this regard (16). Additionally, during a 10-year study on a patient with Charcot-Marie-Tooth, Bensoussan et al (19) reported that the use of orthopedic shoes was helpful for reducing pain and improving patient walking and walking distance without the use of auxiliary equipment. However, as previously mentioned, there was no study on the occurrence of femoral head osteonecrosis cases.

In the present study and based on the information from quantitative HHS formulas at intervals of 3 months between 0 and 100 in addition to their mean comparison with an annual *P* value score of 0.987, no significant difference was observed between control and intervention groups. Nonetheless, patients were clinically highly satisfied with the use of the shoe insert.

Regarding the radiological progression of the disease or its stopping, based on Ficat standard form, a slight insignificance difference was found with respect to $P = 0.003$, which could indicate the positive effect of using the shoe inset on stopping the progression ION of the femoral head. According to the results of this study, it seems that using a shoe insert can be effective in reducing the pain in patients and may delay the progression of the disease and the need for hip replacement. It is hypothesized that the ION of the femoral head can produce the OA of the femoral head in 3 to 5 years, which can greatly help the health system and patients if using the shoe insert.

Suggestions

1- It is recommended that the study be done with larger sample size and longer time to examine the role of the shoe insert in order to delay the progression of the disease more accurately.

2- In addition, patients should be advised to use a shoe insert because of its low cost compared to its potential benefits.

Conflict of Interests

Authors have no conflict of interests.

Ethical Issues

This study was registered at the Iranian Registry of Clinical Trials (IRCT20180714040468N1). In addition, the participants signed informed consent forms and the Research Council and Ethics Committee of Tabriz University of Medical Sciences approved the protocol of the study (code of ethics: IR. TBZ Med. rec.1396,1289)..

Financial Support

This research received no specific grant from funding agencies in the public, commercial, or not-for-profit sectors.

References

- Seo EM, Shrestha SK, Duong CT, et al. Tribological changes in the articular cartilage of a human femoral head with avascular necrosis. *Biointerphases*. 2015;10(2):021004. doi:10.1116/1.4919020
- Malizos KN, Karantanas AH, Varitimidis SE, Dailiana ZH, Bargiotas K, Maris T. Osteonecrosis of the femoral head: etiology, imaging and treatment. *Eur J Radiol*. 2007;63(1):16-28. doi:10.1016/j.ejrad.2007.03.019
- Milner PF, Kraus AP, Sebes JI, et al. Sickle cell disease as a cause of osteonecrosis of the femoral head. *N Engl J Med*. 1991;325(21):1476-1481. doi:10.1056/nejm199111213252104
- Inoue S, Horii M, Asano T, et al. Risk factors for nontraumatic osteonecrosis of the femoral head after renal transplantation. *J Orthop Sci*. 2003;8(6):751-756. doi:10.1007/s00776-003-0716-9
- Kerachian MA, Séguin C, Harvey EJ. Glucocorticoids in osteonecrosis of the femoral head: a new understanding of the mechanisms of action. *J Steroid Biochem Mol Biol*. 2009;114(3-5):121-128. doi:10.1016/j.jsbmb.2009.02.007
- Kaushik AP, Das A, Cui Q. Osteonecrosis of the femoral head: an update in year 2012. *World J Orthop*. 2012;3(5):49-57. doi:10.5312/wjo.v3.i5.49
- Piuzzi NS, Anis HK, Muschler GF. Osteonecrosis of the femoral head with subchondral collapse. *Cleve Clin J Med*. 2019;86(8):511-512. doi:10.3949/ccjm.86a.19004
- Ai ZS, Gao YS, Sun Y, Liu Y, Zhang CQ, Jiang CH. Logistic regression analysis of factors associated with avascular necrosis of the femoral head following femoral neck fractures in middle-aged and elderly patients. *J Orthop Sci*. 2013;18(2):271-276. doi:10.1007/s00776-012-0331-8
- Plenk H, Jr., Gstettner M, Grossschmidt K, Breitenseher M, Urban M, Hofmann S. Magnetic resonance imaging and histology of repair in femoral head osteonecrosis. *Clin Orthop Relat Res*. 2001(386):42-53. doi:10.1097/00003086-200105000-00006
- Mont MA, Jones LC, Hungerford DS. Nontraumatic osteonecrosis of the femoral head: ten years later. *J Bone Joint Surg Am*. 2006;88(5):1117-1132. doi:10.2106/jbjs.e.01041
- Urbaniak JR, Coogan PG, Gunneson EB, Nunley JA. Treatment of osteonecrosis of the femoral head with free vascularized fibular grafting. A long-term follow-up study of one hundred and three hips. *J Bone Joint Surg Am*. 1995;77(5):681-694. doi:10.2106/00004623-199505000-00004
- Sugano N, Atsumi T, Ohzono K, Kubo T, Hotokebuchi T, Takaoka K. The 2001 revised criteria for diagnosis, classification, and staging of idiopathic osteonecrosis of the femoral head. *J Orthop Sci*. 2002;7(5):601-605. doi:10.1007/s007760200108
- Etienne G, Mont MA, Ragland PS. The diagnosis and treatment of nontraumatic osteonecrosis of the femoral head. *Instr Course Lect*. 2004;53:67-85.
- Zalavras CG, Lieberman JR. Osteonecrosis of the femoral head: evaluation and treatment. *J Am Acad Orthop Surg*. 2014;22(7):455-464. doi:10.5435/jaaos-22-07-455
- Camp JF, Colwell CW, Jr. Core decompression of the femoral head for osteonecrosis. *J Bone Joint Surg Am*. 1986;68(9):1313-1319.
- Papalia R, Di Pino G, Tecame A, et al. Biomechanical and neural changes evaluation induced by prolonged use of

- non-stable footwear: a systematic review. *Musculoskeletal Surg.* 2015;99(3):179-187. doi:10.1007/s12306-015-0350-7
17. Nigg BM, Segesser B. Biomechanical and orthopedic concepts in sport shoe construction. *Med Sci Sports Exerc.* 1992;24(5):595-602.
 18. Aoyama T, Goto K, Kakinoki R, et al. An exploratory clinical trial for idiopathic osteonecrosis of femoral head by cultured autologous multipotent mesenchymal stromal cells augmented with vascularized bone grafts. *Tissue Eng Part B Rev.* 2014;20(4):233-242. doi:10.1089/ten.TEB.2014.0090
 19. Bensoussan L, Jouvion A, Kerzoncuf M, et al. Orthopaedic shoes along with physical therapy was effective in Charcot-Marie-Tooth patient over 10 years. *Prosthet Orthot Int.* 2016;40(5):636-642. doi:10.1177/0309364615584657
 20. Sabir M, Lyttle D. Pathogenesis of Charcot-Marie-Tooth disease. Gait analysis and electrophysiologic, genetic, histopathologic, and enzyme studies in a kinship. *Clin Orthop Relat Res.* 1984(184):223-235.

Copyright © 2020 The Author(s); This is an open-access article distributed under the terms of the Creative Commons Attribution License (<http://creativecommons.org/licenses/by/4.0>), which permits unrestricted use, distribution, and reproduction in any medium, provided the original work is properly cited.