



Surgical Closer of Atrial Septal Defect in Adults after 40 Years Old

Rezvanieh Salehi^{1*}, Alireza Yaghoubi², Sarvin Mazani³, Mohammad Goldust⁴

Abstract

Objective: Atrial septal defect (ASD) is the most common congenital heart disease in adults. The aim of this study was to determine the value of surgical closure of ASD in patients over 40 years of age.

Materials and Methods: Retrospective analysis of 96 patients with the mean age of 47.58 ± 6.59 , who had undergone surgical repair of ASD, was carried out. Pre and postoperative clinical status, New York Heart Association (NYHA) functional class and systolic pulmonary artery pressure before and after surgical repair, complications of post operation were assessed and analyzed. The follow-up period was between 1 month and 16 years.

Results: Before the operations, 62 patients (89.8%) were placed in NYHA functional classes of II and III. However, after the surgeries most of the patients could be placed in the functional classes I and II. The mean of pulmonary artery pressure before the surgeries was about 46.68 ± 14.18 and dropped to 32 ± 11.89 mm Hg after the operations ($P < 0.0001$). Atrial fibrillation rhythm was present in 18 cases preoperatively which was reduced to 3 patients at the discharge time (16.6%). The mean right ventricular (RV) sizes were reduced from 4.1 to 2.5 cm after the surgical repairs. In 35 cases (36.64%), we had no tricuspid valve regurgitation after surgery for RV systolic presser estimation.

Conclusion: Surgical closure of ASD in patients over 40 years of age could improve their clinical status, and lead to a reduced pulmonary systolic as well as smaller RV sizes.

Keywords: Adults, Atrial Septal Defect, Cardiac Surgery

Introduction

Atrial septal defect (ASD) account for 5-10% of all congenital heart disease (CHD), and about 30% of the CHD diagnosed in adults (1). ASDs are twice as common in females as in males. Most ASDs occur sporadically as a result of spontaneous genetic mutations; however, hereditary forms have been reported (2). Associated extra-cardiac congenital defects are present in 25% of infants, and about one third have a hereditary syndrome (3). Patients are usually asymptomatic in the first and second decades of life. The most common manifestations of this condition in adults are development of fatigue,

dyspnea on exertion, and exercise intolerance (4). Paradoxical embolization, palpitations secondary to supraventricular arrhythmias, or recurrent respiratory infections may be occur (5). If left untreated, patients with hemodynamically significant ASDs will develop symptoms of right-sided heart failure. Because of its low operative risks, the closure of ASD is recommended in symptomatic cases with large left to right shunts (6). It is a disorder to be addressed surgically or through interventional catheterization. The most currently used method for secundum type ASD closure is using device close in the presence of sufficient rims.

Received: 8 Sep 2013, **Revised:** 19 Oct 2013, **Accepted:** 20 Dec 2013, **Available online:** 15 Jan 2014

¹ Department of Cardiology, Cardiovascular Research Center, Tabriz University of Medical Sciences, Tabriz, Iran

² Department of Cardiac Surgery, Cardiovascular Research Center, Tabriz University of Medical Sciences, Tabriz, Iran

³ Cardiovascular Research Center, Tabriz University of Medical Sciences, Tabriz, Iran

⁴ Student Research Committee, Tabriz University of Medical Sciences, Tabriz, Iran

***Corresponding Author:** Rezvanieh Salehi, Department of Cardiology, Cardiovascular Research Center, Tabriz University of Medical Sciences, Tabriz, Iran

Tel: +98 9141161912, Email: Salehiir2002@yahoo.com

Medications won't repair the hole, but they may be used to reduce some of the signs and symptoms that can accompany with ASD. ASD remains unrecognized for many years in adults as it has few or no associated clinical symptoms (7). Drugs may also be used to reduce the risk of complications after surgery (8). The standard criterion for treatment of ASD is direct closure of the defect by using an open approach with extracorporeal support (9). Surgical techniques and equipment have since improved to the point that the mortality rate from this repair approaches zero. Complete earlier surgical repairs could prevent subsequent heart failures, pulmonary hypertensions, thromboembolic events and also arrhythmias (10). Despite the benefits of surgical closure of ASD in childhood and adulthood, the long-term survival of the patients undergoing surgical operations over the age of 40 remains controversial (11). The aim of this study is to evaluate the functional classes, pulmonary systolic pressures, right ventricular (RV) sizes, surgical complications and also arrhythmia in patients with ASD.

Materials and Methods

This study was approved by research committee of Tabriz University of Medical Sciences, Iran. Written consent was obtained from all the patients. The medical records of all patients diagnosed with ASD at the age of ≥ 40 years from the January of 1985 until the August of 2011 were retrospectively analyzed. The exclusion criteria included the small-size ASDs, with QP/QS ≤ 1.5 , the associated congenital anomalies such as pulmonary stenosis, Ebstein anomaly of tricuspid valve, and the ages lower than 40. The Patients with anomalous mitral valves in ostium primum or ostium secundum types ASD were not excluded. All cases underwent full clinical evaluation, a 12 lead ECG study, complete echocardiographic and also cardiac catheterization studies were performed. Echocardiographic evaluation

included RV dimension in RV out flow tract, using M-mode technique from high parasternal long axis position, and 4-chamber view. Also comprehensive echocardiographic evaluation of shunt sizes or the associated valvular or other congenital anomalies, RV systolic pressure by tricuspid regurgitation (TR) jet velocity and Bernoulli equation were calculated. The follow-up was through telephone calls and office visits. The statistical calculations were performed using SPSS for Windows (version 17.0, SPSS Inc., Chicago, IL, USA). All ($P < 0.05$) (two-tailed) were considered as statistically significant. Continuous variables with normal distribution are presented as mean \pm standard deviation. Categorical variables were analyzed with t-test.

Results

One hundred and fourteen patients were studied, but only 96 patients fit our inclusion criteria. The mean ages were 47.58 ± 6.59 , ranging from 40 to 68 years of age. Women made up 75% of our cases (72 patients) and men 25% (24 cases). The mean of pulmonary to systemic circulation ratio (QP/QS = 2.5 ± 0.59 (1.6-4.5)). Pre-operative RV systolic presser (RVSP) was between 46 ± 14.18 mm Hg (20-85) and dropped to 32.77 ± 11.9 mm Hg post operatively (15-70 mm Hg). However, the evaluation of RVSP with TR jets was not valid in 35 cases, because they had no TR for RVSP estimation. We followed 56 patients who were active. Forty patients were in our missed data due to wrong numbers or address changing (Table 1 and Figure 1).

Table 1. Demographic data of study population

Variable	Mean \pm SD
Age	47.58 \pm 6.59
Qp/Qs	2.50 \pm 0.59
RVSP pre-operative	46.68 \pm 14.18
RVSP post-operative	32.77 \pm 11.89

RVSP: Right ventricular systolic presser; SD: Standard deviation

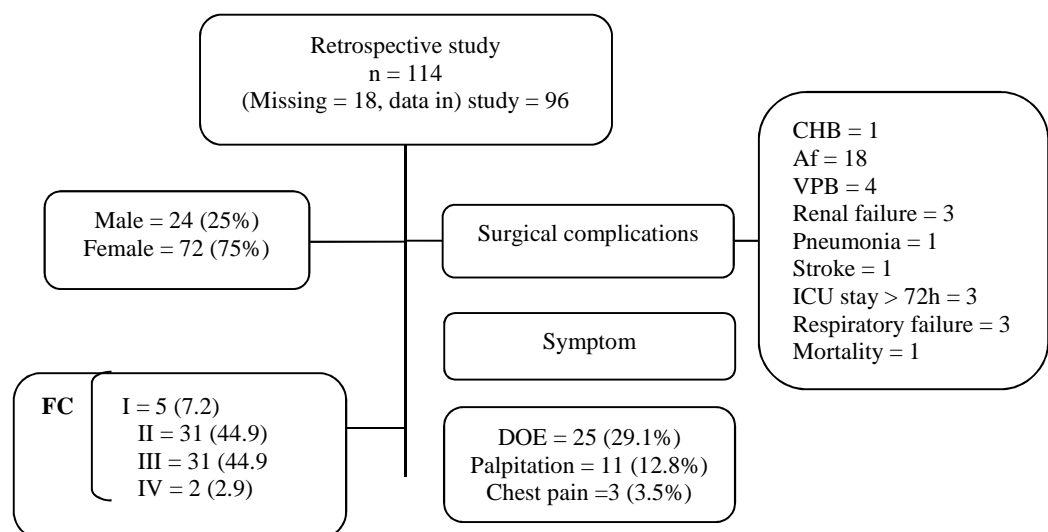


Figure 1. Demographic flowchart of study population

CHB: Complete heart block; Af: Atria fibrillation; VPB: Ventricular premature beats; ICU: Intensive care unit; FC: Function class; DOE: Dyspnea on exertion

Discussion

ASD is a volume over load of the right heart, with symptomatic deterioration with increasing of age and also heart failures which lead to death after 35-50 years of age (12). It is recommended surgical or catheter-based correction of this anomaly in childhood to prevent complications of ASD such as thromboembolic events, AF rhythm, and heart failure in adulthood (13). After the first report of the successful surgical repair of ASD with operative mortality rate of 6-9%, nowadays the mortality has decreased to 3% and incomplete closure is uncommon (< 1%) (14). The previous belief indicating that only 50% of patients with unrepaired ASDs could live to be over 40 and that only < 10% could be alive after the age of 60 has not been confirmed by other studies (15,16). Fiarresga et al. showed that there was an increased risk of post operative cardiovascular complication with patients who had an operation after the age of 40 years when compared with the surgeries in childhood or young adulthood (17), but our study revealed only one in-hospital death in 49 years, an old woman with intractable arrhythmia, respiratory and renal failure. Our study mainly pointed out the post-operative complications. ICU stays exceeding 72 h were found only in 3 cases; 1 case being due to renal and another one because of respiratory failure. We found AF rhythm only in 18 cases (64.7%) in women, 12 cases (64.7%) of men, all of them converted to sinus rhythm except for 3 cases (Figure 1). Multiple discrepancies were found in exploring the clinical impact of surgical treatment of ASD in patients over 40 years old (18). These might be related to heterogeneity of the study groups and the study bias. For reducing these disagreements, Konstantinides et al. used multivariate analysis in 179 consecutive patients over the age of 40 with diagnosis of isolated ASD. They found significant mortality rate decrement after surgical repairer of the defects (18). Their results were in complete agreement with ours which showed only 1 death in hospital. Attie et al. In recent publications of 473 adults with ASD over the age of 40 years in randomized medical or surgical groups found no significant alteration of prognosis in terms of mortality, whereas the risk of major cardiovascular complications was clearly elevated in the surgical group (19). Furthermore, our study revealed more dramatic decrement of RVSP and RV sizes after surgery and these are compatible with the results of Kijima et al. group who compared surgical closure of ASD before and after the age of 25 years with the natural history of un operated patients (20). Functional capacity also decreased from II, III to I and II in our study group. All patients were active and alive after our surgical repair excluding the one who died in hospital.

Conclusion

Surgical closure of ASD in patients over 40 years of age could improve their clinical status, functional

capacity and lead to a reduced pulmonary systolic as well as smaller RV sizes and incidence of heart failure. Also correction of this anomaly should be considered regardless of patients' age.

Ethical issues

The study was approved by the ethic committee of Tabriz University of Medical Sciences.

Conflict of interests

We declare that we have no conflict of interests.

Acknowledgments

We would great thank all of the patients who participated indirectly in this study.

References

1. Ueda H, Yanagi S, Nakamura H, Ueno K, Gatayama R, Asou T, et al. Device closure of atrial septal defect: immediate and mid-term results. *Circ J* 2012; 76: 1229-34.
2. Yuan YQ, Huang Q, Yu L, Wang RM, Zhao YJ, Guo YX, et al. Long-term follow up of interventional therapy of secundum atrial septal defect. *Chin Med J (Engl)* 2012; 125: 149-52.
3. Yilmaz K, Ewert P, Hetzer R, Stamm C. Surgical repair after ineffective device closure of an inferior sinus venosus defect. *Interact Cardiovasc Thorac Surg* 2012; 14: 485-7.
4. Ma ZS, Dong MF, Yin QY, Feng ZY, Wang LX. Totally thoracoscopic closure for atrial septal defect on perfused beating hearts. *Eur J Cardiothorac Surg* 2012; 41: 1316-9.
5. Hanninen M, Kmet A, Taylor DA, Ross DB, Rebeyka I, Vonder Muhll IF. Atrial septal defect closure in the elderly is associated with excellent quality of life, functional improvement, and ventricular remodelling. *Can J Cardiol* 2011; 27: 698-704.
6. Butera G, Biondi-Zoccai G, Sangiorgi G, Abella R, Giamberti A, Bussadori C, et al. Percutaneous versus surgical closure of secundum atrial septal defects: a systematic review and meta-analysis of currently available clinical evidence. *EuroIntervention* 2011; 7: 377-85.
7. Kutty S, Hazeem AA, Brown K, Danford CJ, Worley SE, Delaney JW, et al. Long-term (5- to 20-year) outcomes after transcatheter or surgical treatment of hemodynamically significant isolated secundum atrial septal defect. *Am J Cardiol* 2012; 109: 1348-52.
8. Zhang H, Chen Q, Chen LW, Cao H, Zhang GC, Chen DZ. Intraoperative device closure of atrial septal defects in the older population. *J Cardiothorac Surg* 2011; 6: 123.
9. Park JJ, Lee SC, Kim JB, Seo DJ, Song JM, Yun SC, et al. Deterioration of mitral valve competence after the repair of atrial septal defect in adults. *Ann Thorac Surg* 2011; 92: 1629-33.
10. Akkaya E, Vuruskan E, Aksoy I, Ardic I, Kucukosmanoglu M, Ozer O. Intracardiac

- echocardiography-guided device closure of atrial septal defects: our initial experience. *Turk Kardiyol Dern Ars* 2011; 39: 474-8.
11. Uechi M, Harada K, Mizukoshi T, Mizuno T, Mizuno M, Ebisawa T, et al. Surgical closure of an atrial septal defect using cardiopulmonary bypass in a cat. *Vet Surg* 2011; 40: 413-7.
 12. Jategaonkar SR, Scholtz W, Horstkotte D, Kececioglu D, Haas NA. Interventional closure of atrial septal defects in adult patients with Ebstein's anomaly. *Congenit Heart Dis* 2011; 6: 374-81.
 13. Samiei N, Bayat F, Moradi M, Parsaei M, Haghighi SZ, Mohebbi A, et al. Comparison of the response of the right ventricle with endovascular occlusion and surgical closure in adults with atrial septal defect one year after intervention. *Clin Med Insights Cardiol* 2010; 4: 143-7.
 14. Pala S, Acar G, Tigen K, Kirma C. Percutaneous retrieval of an interatrial septal occluder device embolized into the aortic arch. *Turk Kardiyol Dern Ars* 2010; 38: 502-4.
 15. Ma ZS, Dong MF, Yin QY, Feng ZY, Wang LX. Totally thoracoscopic repair of atrial septal defect without robotic assistance: a single-center experience. *J Thorac Cardiovasc Surg* 2011; 141: 1380-3.
 16. Moore JW, Norwood JB, Kashow KM, Murphy JD. Closure of atrial septal defects in the cardiac catheterization laboratory: early results using the Amplatzer Septal Occlusion Device. *Del Med J* 1998; 70: 513-6.
 17. Fiarresga A, De Sousa L, Martins JD, Ramos R, Parames F, Freitas I, et al. Percutaneous closure of atrial septal defects: a decade of experience at a reference center. *Rev Port Cardiol* 2010; 29: 767-80.
 18. Konstantinides S, Geibel A, Olschewski M, Gornandt L, Roskamm H, Spillner G, et al. A comparison of surgical and medical therapy for atrial septal defect in adults. *N Engl J Med* 1995; 333: 469-73.
 19. Attie F, Rosas M, Granados N, Zabal C, Buendia A, Calderon J. Surgical treatment for secundum atrial septal defects in patients > 40 years old. A randomized clinical trial. *J Am Coll Cardiol* 2001; 38: 2035-42.
 20. Kijima Y, Taniguchi M, Akagi T, Nakagawa K, Kusano K, Ito H, et al. Torn atrial septum during transcatheter closure of atrial septal defect visualized by real-time three-dimensional transesophageal echocardiography. *J Am Soc Echocardiogr* 2010; 23: 1222-8.

Citation: Salehi R, Yaghoubi A, Mazani S, Goldust M. **Surgical Closer of Atrial Septal Defect in Adults after 40 Years Old.** *Crescent J Med & Biol Sci* 2014; 1(1): 21-4.